This is a digital copy of a book that was preserved for generations on library shelves before it was carefully scanned by Google as part of a project to make the world's books discoverable online.

It has survived long enough for the copyright to expire and the book to enter the public domain. A public domain book is one that was never subject to copyright or whose legal copyright term has expired. Whether a book is in the public domain may vary country to country. Public domain books are our gateways to the past, representing a wealth of history, culture and knowledge that's often difficult to discover.

Marks, notations and other marginalia present in the original volume will appear in this file - a reminder of this book's long journey from the publisher to a library and finally to you.

Usage guidelines

Google is proud to partner with libraries to digitize public domain materials and make them widely accessible. Public domain books belong to the public and we are merely their custodians. Nevertheless, this work is expensive, so in order to keep providing this resource, we have taken steps to prevent abuse by commercial parties, including placing technical restrictions on automated querying.

We also ask that you:

+ *Make non-commercial use of the files* We designed Google Book Search for use by individuals, and we request that you use these files for personal, non-commercial purposes.
+ *Refrain from automated querying* Do not send automated queries of any sort to Google's system: If you are conducting research on machine translation, optical character recognition or other areas where access to a large amount of text is helpful, please contact us. We encourage the use of public domain materials for these purposes and may be able to help.
+ *Maintain attribution* The Google "watermark" you see on each file is essential for informing people about this project and helping them find additional materials through Google Book Search. Please do not remove it.
+ *Keep it legal* Whatever your use, remember that you are responsible for ensuring that what you are doing is legal. Do not assume that just because we believe a book is in the public domain for users in the United States, that the work is also in the public domain for users in other countries. Whether a book is still in copyright varies from country to country, and we can't offer guidance on whether any specific use of any specific book is allowed. Please do not assume that a book's appearance in Google Book Search means it can be used in any manner anywhere in the world. Copyright infringement liability can be quite severe.

About Google Book Search

Google's mission is to organize the world's information and to make it universally accessible and useful. Google Book Search helps readers discover the world's books while helping authors and publishers reach new audiences. You can search through the full text of this book on the web at `http://books.google.com/`

ATLAS
OF
HUMAN HISTOLOGY

LANE
MEDICAL LIBRARY

Dr. Barkan + Hirschfelder

LANE MEDICAL LIBRARY
STANFORD UNIVERSITY
300 PASTEUR DRIVE
PALO ALTO, CALIF.

ATLAS

OF

HUMAN HISTOLOGY.

ATLAS

OF

HUMAN HISTOLOGY.

LANE LIBRARY

BY

DR. ARNOLD BRASS,
GÖTTINGEN.

SIXTY PLATES ENGRAVED AND PRINTED IN COLOURS,

WITH

Explanatory Notes.

AUTHORIZED TRANSLATION FROM THE GERMAN, WITH ADDITIONS,

BY

R. A. YOUNG, M.D., B.Sc. LOND.,
LECTURER ON PHYSIOLOGY AT THE MIDDLESEX HOSPITAL MEDICAL SCHOOL, LONDON.

LANE MEDICAL LIBRARY
35-05
SAN FRANCISCO

NEW YORK:
WILLIAM WOOD AND COMPANY.
1897.

LANE LIBRARY

E 551
B 823
1897

TRANSLATOR'S PREFACE.

THE lack of an English Atlas of Histology, at once portable and at a price within the reach of the student, renders an apology for an English edition of Dr. Brass's Atlas unnecessary.

This Atlas is simply a representation in colour of the appearances presented under the microscope by prepared and stained preparations of the various tissues and organs of the body, and is intended to serve as an aid and an incentive to the study of the actual specimens, and as a companion to the text-book of Histology, and not as a substitute for either; in other words, to enable the student to work out the details of his own specimens and to draw them, ample space being left for that purpose.

A unique feature of the Atlas is that most of the specimens have been derived from some of the best private collections in Germany (the source in nearly every case being stated), while the figures are drawn as faithfully as possible from the actual specimens, and the process of reproduction and colouring carried out by Dr. Brass with his own apparatus.

The material was in nearly all cases human, so that human, and not comparative, Histology is represented, the material being obtained fresh under conditions not readily attainable here.

The explanatory notes attached to each plate are not exhaustive descriptions of the structures represented, but merely short outlines to describe the nature of the section, and indicate the various tissue elements of which it is composed.

The magnification in diameters, the method of hardening and staining, and the source of the preparation, are given with each figure.

In the translation, I have for the most part adhered closely to the German text, but in some cases slightly longer explanatory outlines have been given, especially in the case of the plates dealing with the nervous system, in the hope of increasing their utility.

R. A. YOUNG.

THE MIDDLESEX HOSPITAL, 1896.

EXTRACT FROM AUTHOR'S PREFACE.

THE special features of the present Atlas are the nature and method of the illustrations.

There is no lack of good text-books of normal Histology for the student or the practitioner, but there is a need for a good illustrated work, the plates of which shall present as exactly as possible the appearances of the actual tissues as they are seen by the aid of the microscope.

In order to obtain the necessary specimens, I applied to many Professors, Clinicians, Docents, and Physicians; on all hands I experienced the greatest encouragement. In the first place, I laid my plans before Professor Waldeyer, of Berlin, and Professor Merkel, of this place, who at once placed their rich and costly collections at my disposal.

To these gentlemen I must once again express my most sincere thanks.

I am also indebted to Professor Flemming and Professor Kallius for assistance in the provision of material. By other gentlemen, whose names I mention in the text, still further specimens were lent for my use.

Numerous injected specimens came from the Anatomical Institute at Leipzig; for these I am indebted to Dr. Reichenbach and Dr. Meyer. In like manner Dr. Freudenstein placed at my disposal his specimens, which were prepared in the Histological Institute at Strassburg.

Two perfectly fresh bodies of new-born children I obtained through Professor Ahlfeld, of Marburg; they were prepared by the usual methods of Marburg Institute. The numerous illustrations of the tissues of the newly born are chiefly made from these preparations.

Material was also obtained from the bodies of recently executed criminals, or of suicides, or direct from operation cases, since the microscopical appearances of fresh tissues differ from those presented by specimens derived from bodies which have been kept any time before the material is taken. Such differences are well shown by the sections of the mucous membrane of the stomach and intestines.

The fact that I can employ numerous colours for the elucidation of the illustrations makes it possible for me to produce the figures in relatively smaller degrees of magnification; for the most part I adopt that degree which is necessary to see the structure quite distinctly.

Each plate has a short explanatory note. The individual tissue elements are indicated in the plates. The terminology chosen is, as far as possible, uniform. We possess as yet, unfortunately, no generally accepted international terminology; in default of this I have adopted the meanings current at the present time.

The addition of a detailed descriptive text was unnecessary, since there is no lack of good text-books of Histology, to which the present Atlas might serve as a companion work.

For all assistance in my work I must offer my most sincere thanks.

GÖTTINGEN, 1896.

LIST OF PLATES.

A. CELLULAR STRUCTURES.

A 1. Cell Structure—General outlines.
A 2. Cell Forms—Modifications of protoplasm.
A 3. Cell Division—Karyokinesis.

B. THE SKIN.

B 1. Skin—General outlines.
B 2. Skin—Appendages: hair.
B 3. Skin—Papillæ, nails, etc.
B 4. Skin—Nerves and sensory end-organs.
B 5. Skin—Sebaceous glands, Meibomian glands. The mammary gland.
B 6. Skin—Epidermis, sweat glands. The lips.

C. SENSE ORGANS.

C 1. Sense Organs—Smell and taste.
C 2. Sense Organs—The eye: cornea and lens.
C 3. The Eye—Choroid, iris, ciliary processes.
C 4. The Eye—Optic nerve and retina.
C 5. The Eye—Retina (*continued*).
C 6. The Ear—Cochlea and organ of Corti.
C 7. The Ear—Semicircular canals; ampullæ. Auditory cells.

D. THE NERVOUS SYSTEM.

D 1. The Nervous System—Nerve cells and nerve fibres.
D 2. Spinal Cord—Medulla oblongata.
D 3. Medulla Oblongata (*continued*)—Nerve elements from cord and medulla.
D 4. Medulla Oblongata (*continued*).
D 5. Medulla Oblongata—Upper part: commencement of pons Varolii.
D 6. Spinal Cord and Medulla in the Infant.
D 7. Medullated Fibres and their Arrangement.
D 8. Pons Varolii and Fourth Ventricle.
D 9. Pons and Corpora Quadrigemina.
D 10. Cerebellum.
D 11. Cortex Cerebri—Pyramidal cells.
D 12. Cortex Cerebri—Results of Golgi's method.
D 13. Sympathetic and Peripheral Nervous System—Cells and fibres.
D 14. Neuroglia—Structure and development.

E. MUSCLE.

E 1. Striated Muscle—General outlines: vascular supply.
E 2. Striated Muscle—Heart muscle. Non-striated or plain muscle.

F. CONNECTIVE TISSUES.

F 1. Connective Tissues—General outlines.
F 2. Fibro-cartilage. Elastic Cartilage. Elastic Fibres.
F 3. Development of Bone.
F 4. Structure of Bone.

G. ORGANS OF DIGESTION.

G 1. Tooth.
G 2. Development of Tooth.
G 3. Tongue.
G 4. Tongue (*continued*). Œsophagus.
G 5. Stomach—General structure. Cardiac and Pyloric Glands.
G 6. Stomach (*continued*). Duodenum. Villi.
G 7. Salivary Glands. Pancreas.
G 8. Omentum and Mesentery. Ileum.
G 9. Small Intestine. Villi. Nerve Plexuses.
G 10. Colon and Vermiform Appendix.
G 11. Liver.
G 12. Liver (*continued*). Regeneration of Intestinal Epithelium.

H. ORGANS OF RESPIRATION.

H 1. Larynx and Air-tubes.
H 2. Lung. Thyroid Gland.

J. THE VASCULAR SYSTEM.

J 1. Blood-corpuscles and Capillary Vessels.
J 2. Arteries and Veins.
J 3. Lymph-vessels. Thymus. Spleen.

K. URINARY ORGANS.

K 1. Kidneys. Bloodvessels and tubules.
K 2. Kidneys (*continued*)—Glomeruli.
K 3. Urinary Bladder. Ureter. Urethra.

L. GENERATIVE ORGANS.

L 1. Ovary.
L 2. Ovary (*continued*). Graafian Follicles. Uterus. Fallopian Tube.
L 3. Testis. Epididymis.
L 4. Penis. Prostate. Urethra.

A.—THE CELL.

A.1.

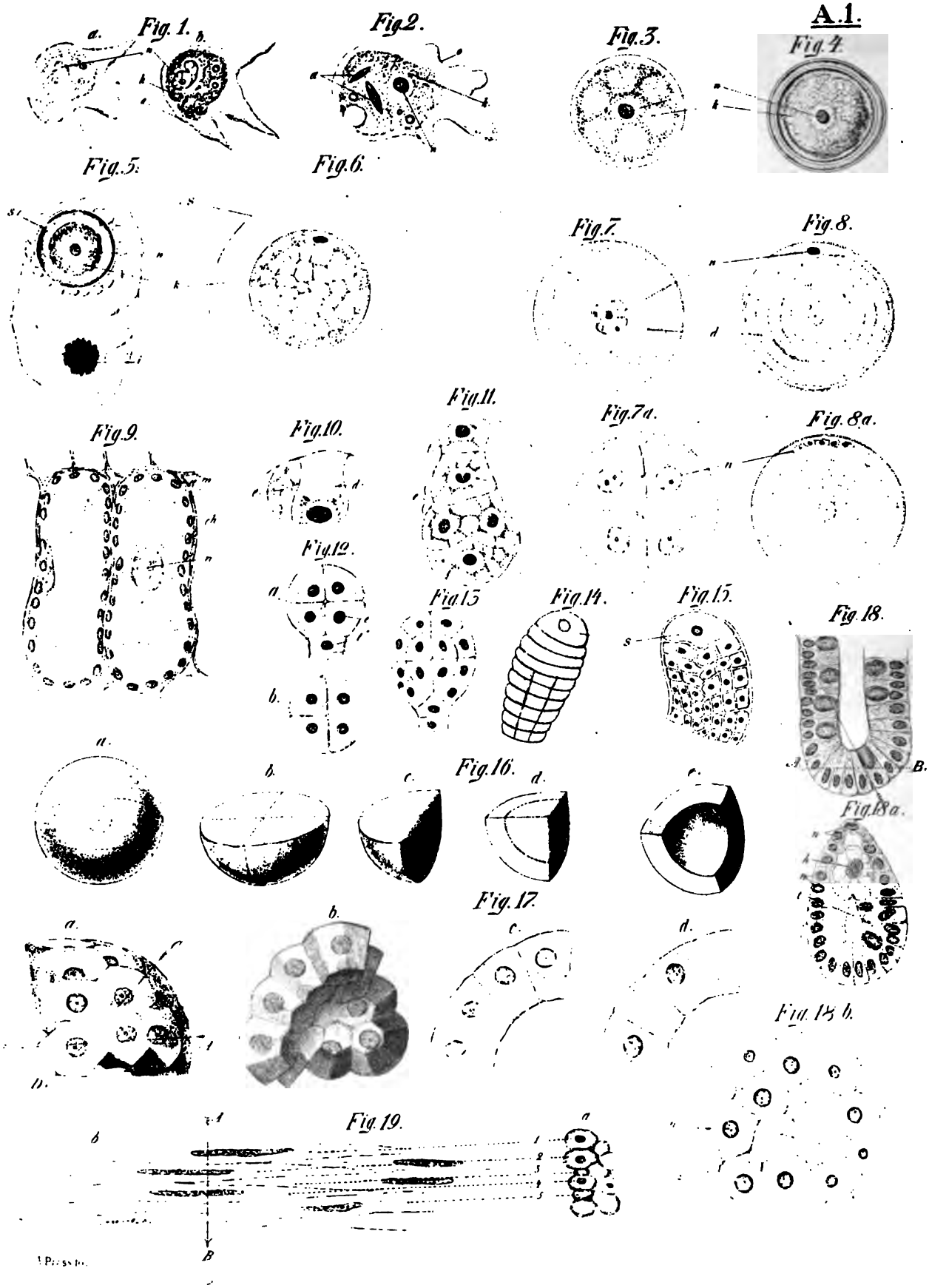
Fig. 1.
Fig. 2.
Fig. 3.
Fig. 4.
Fig. 5.
Fig. 6.
Fig. 7.
Fig. 8.
Fig. 9.
Fig. 10.
Fig. 11.
Fig. 7a.
Fig. 8a.
Fig. 12.
Fig. 13
Fig. 14.
Fig. 15.
Fig. 18.
Fig. 16.
Fig. 18a.
Fig. 17.
Fig. 18 b.
Fig. 19.

A 1. CELL STRUCTURE—GENERAL OUTLINES.

FIG. 1. **Blood Corpuscles of the Fresh-water Crayfish** (×600).—These cells are easy to examine in the living condition, as in *a*; the general outline of the cell is seen, but its margin is not sharply defined, and its contents are indistinct.

b, After treatment with chromo-acetic-osmic acid (Flemming's reagent)—all parts of the cell are now sharply defined and differentiated. *n*, nucleus; *k*, granular endoplasm, outside which the more clear ectoplasm, *e*, is seen forming processes or *pseudopodia*—serving for locomotion and the ingestion of food material.

FIGS. 2-5. **Fresh-water Amœbæ** (×1000).—Fixed with Hermann's fluid (chromic-platinic chloride), stained with acid carmine, and decolourized by ½ per cent. hydrochloric acid.

FIG. 2. **Amœba Princeps.**—Pseudopodia fixed, showing the nature of amœboid movement, and the homogeneous appearance of the pseudopodia themselves.

a, Food particles (ingested diatoms).
n, *k*, *e*, as in the last figure.

FIG. 3. **Resting Stage of the same Amœba.**—The cell has assumed a globular shape, and become surrounded by a delicate membrane, while small spherical clear areas appear in the protoplasm, *k*, but disappear at a later stage.

FIG. 4. **Permanent Stage of the same Amœba.**—It now has a thicker laminated external membrane; at a later stage the protoplasmic contents split into numerous small masses (*spores*).

FIG. 5. **Permanent Stage of an Amœba Parasitic in Plant Cells** (after Zopf).—

ss', Two cell membranes or partitions; *s*, a larger external one, within which at *i* lies the granular undigested residue of some food material.

Outside the inner membrane, *s'*, the cell substance is arranged so as to form a layer of vesicles or vacuoles. The main body of the cell has contracted away from the membrane into a spherical mass, in the centre of which lies the nucleus.

FIG. 6. **Ovum of a Beroë, one of the Ctenophora, highly magnified** (after Chun).—Externally there is a delicate membrane, *s*, which encloses a gelatinous mass in which the actual ovum lies. The yolk, *k*, has a spongy structure internally, while the outer part is finely granular; the nucleus lies at the upper part of the ovum.

The ovum itself is enclosed by a special membrane, in addition to that which encloses the gelatinous material.

(NOTE.—FIGS. 5 and 6 both indicate that animal cells may possess one or more membranes.)

FIGS. 7, 7*a*. **Mammalian Ovum in Section** (partly diagrammatic).—Fig. 7 shows the mature ovum as a spherical cell with a central nucleus, *n* (*the germinal vesicle*), which lies in a finely granular yolk material. This spherical cell forms the origin of all the

other cells of the body. The first primitive layers or tissues are derived by division after the manner represented in diagrams 16 and 17.

In this case, the whole ovum takes part in the division, and, as the process goes on, becomes divided into 2, 4, 8, 16, and so on.

Fig. 7*a*. **Section through the Ovum after Division into Four.**

Figs. 8, 8*a*. **Diagrammatic Representation of the Structure of the Ovum of a Bird and the early Segmentation Process.**—Fig. 8: The germinal vesicle, *n*, lies excentrically at the upper pole, and when division takes place, the yolk does not take part in the process, so that the first segmentation cells lie on the surface, in the situation of the germinal vesicle itself before division, as shown in Fig. 8*a*.

Fig. 9. **Vegetable Cells.**—They show the characteristics of the cell more distinctly than animal cells. The nuclei, *n*, are stained red, and are surrounded by a layer of granular protoplasm, from which fine threads pass off to the peripheral part of the cells, where there is a distinct layer of protoplasm, in which lie the green *chlorophyll* granules, *ch*. In the body of the cells are large clear spaces filled with cell-sap. Externally the cells are enclosed by tough membranes of cellulose, *m*.

Fig. 10. **Ovule of a Plant in Cross-section, highly magnified.**—The *oosphere*, *d*, is seen with an unfertilized accessory cell, *e*, lying in the *embryo-sac*, of which only a part is represented. The *oosphere* after fertilization divides transversely; that part which remains attached to the embryo-sac is called the *suspensor*; the other cell by repeated division forms the *embryo*, which grows into the embryo-sac.

Fig. 11. **Vegetable Embryo**, *e*, consisting of four cells, which are attached to the embryo-sac by the suspensor, *t*.

Fig. 12. **Semi-diagrammatic Representation of the Embryo of the Shepherd's Purse (Capsella bursa pastoris).**

a, Embryo seen from the side; below is the suspensor, consisting of two cells; the embryo is nearly spherical, and consists of eight cells, four only being seen in this view.

b, Seen from the end of the embryo—four cells again seen. Tangential division then occurs, so that central and peripheral cells are formed, the latter again dividing by radial septa.

Fig. 13. **Section through that Stage in which there are Eight Central and Thirty-two Peripheral Cells.**—Four of the former and eight of the latter are visible.

(Figs. 14 **and** 15 **are introduced to show the Nature of Cell Formation and Cell Growth in Plants, for Comparison with the same Process in Animals.**)

Fig. 14. **A Young Leaf-bud of Marsilia Uncinata magnified** (after Behrens).

Fig. 15. **The same in Section.**—*s* is the *apical cell*, from which (in Cryptogamia) cell multiplication proceeds; the cells separate off by tangential division from the lower part of the apical cell, and then again undergo division parallel to the surface, forming growing tissue or primary *meristem*.

The horizontal lines in the figure indicate the primary divisions, the vertical ones the secondary divisions parallel to the lateral surface.

FIGS. 16-19. **Diagrams introduced to show the Relation between the Microscopical Appearance and the Actual Shape and Form of Cell,** *i.e.*, to show how the former depends on the direction of section.

FIG. 16. **Diagrammatic Scheme of the Process of Segmentation of the Mammalian Ovum.**

The spherical cell *a* shows an equatorial groove (dotted in the diagram), through which division occurs into two halves, each of which again divides.

b shows the lower half resulting from the first division; the places of subsequent segmentation are indicated.

c, The half of *b* split off by the second division; this divides again into two, each of which divides somewhat in the manner indicated in *d*, by a division parallel to the convex surface.

The same process occurs in all the eight segments, so that the ovum now consists of eight cells of the form shown in *e*, and eight central cells like that indicated by the smaller segment of *d*.

But the further process of segmentation does not proceed so regularly; the central cells get separated, and the outer ones divide more rapidly, so that structures like those of Fig. 17 are produced.

FIG. 17. **The Eighth Part of such an Ovum as that described above.**—Ten cells are here shown lying side by side.

a shows the appearance when seen from the outside.

b that from the inside.

Owing to the cells lying so close together, the contiguous surfaces of adjacent cells have become mutually flattened, while the inner and outer surfaces form now a part of the spherical surface of the embryo. Each cell in the diagram may be regarded as having six lateral surfaces, a base and an outer surface.

If sections be now made, *e.g.*, in the directions of the arrows AB and CD, the section AB will obviously show four cells and four nuclei, and the appearance under the microscope will be as represented at *c*. The section CD passes through four cells, but only includes the nuclei of two of them, as shown at *d*.

FIGS. 18, 18*a*, 18*b*. **Examples from the Tissues, also to illustrate the Relation between Actual Cell Structure and Microscopical Appearances.**—Fig. 18: The end of a gland from the digestive tract, very highly magnified. The gland is represented in longitudinal section, as are also the cells lining it, which are seen to consist of two varieties—narrow cylindrical or *columnar* epithelial cells, between which lie more deeply-stained cells distended with secretion (*goblet cells*); the nuclei in both lie towards the base of the cells.

If now a thin section be made in the direction of the arrow, the microscopical appearances are as represented in Fig. 18*a*.

FIG. 18*a*. **Oblique Section of a Digestive Gland.**

n, Nuclei of the cells.

h, Section through the distended part of a goblet-cell, around which are a number of clear polygonal areas, the sections of cells the nuclei of which are not caught in the plane of the section; again, in the upper part the cells and nuclei are seen in transverse section, in the lower part in longitudinal section.

At *t* the lumen of the gland is seen.

If a thin section of the blunt end of the gland in Fig. 18 be made in the direction AB, and more highly magnified, the appearances obtained would be such as represented in Fig. 18*b*.

FIG. 18*b*. **Transverse Section of the End of a Digestive Gland.**

The cells appear irregularly polygonal in section (five- and six-sided).

At *z* only the cell outlines and protoplasm are seen, the section having missed the nuclei, while in the surrounding cells the nuclei, *n*, are seen in some cut directly across, in others only just caught by the section.

FIG. 19. **To show in Diagram how quite different Appearances may be presented by Tissues (in this case Non-striated Muscle Fibres) according to the Direction of the Section.**

a, Cross-section of non-striated muscle fibres.

b, The same cells seen in longitudinal section, the arrow AB indicating the direction of the section represented in *a*.

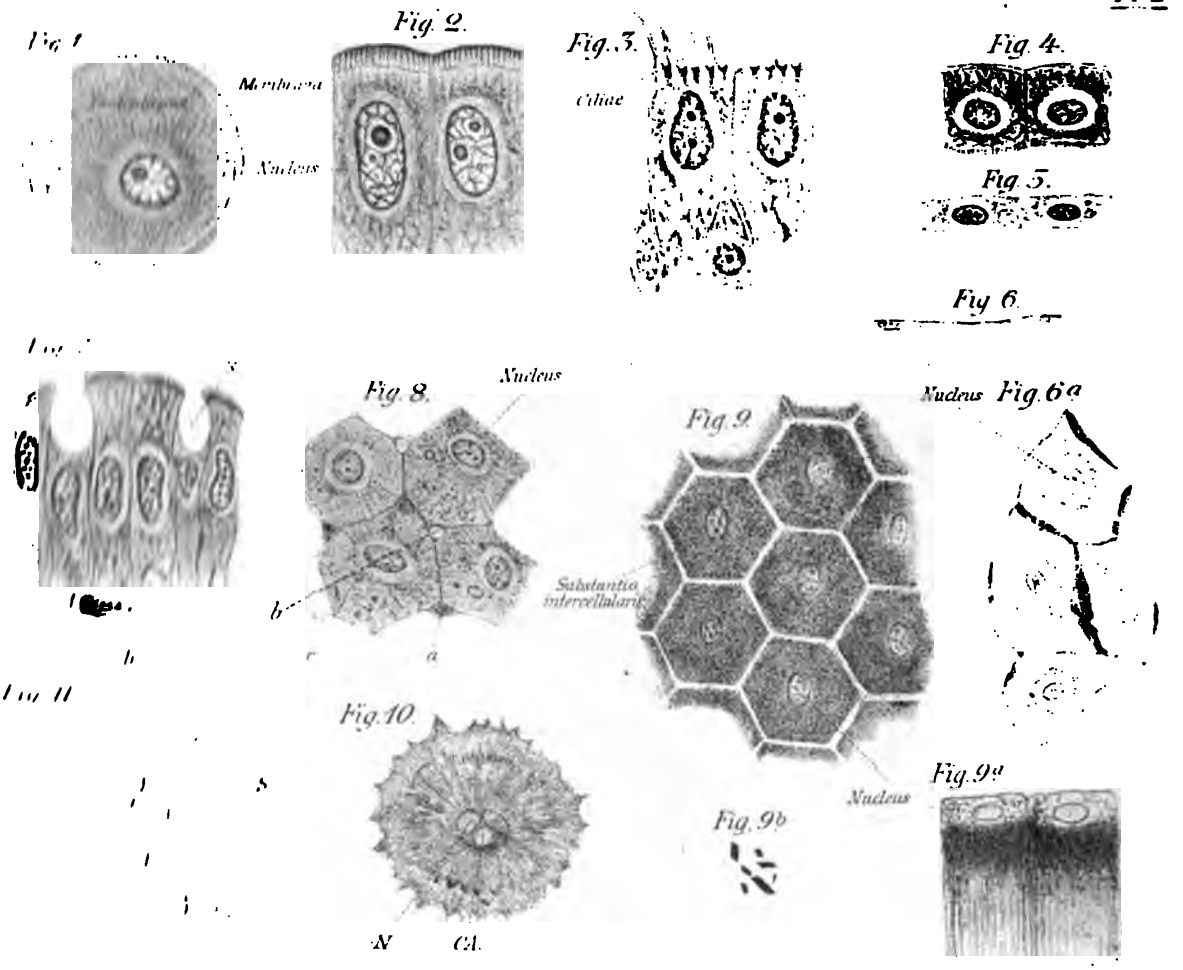
Fig. 1
Membrana
Nucleus
Fig. 2.
Fig. 3.
Cilia
Fig. 4.
Fig. 5.
Fig 6.
Fig. 8.
Nucleus
b
a
Fig. 9
Substantia intercellularis
Nucleus
Fig. 6a
Fig. 10.
N
CA.
Fig. 9b
Fig. 9a

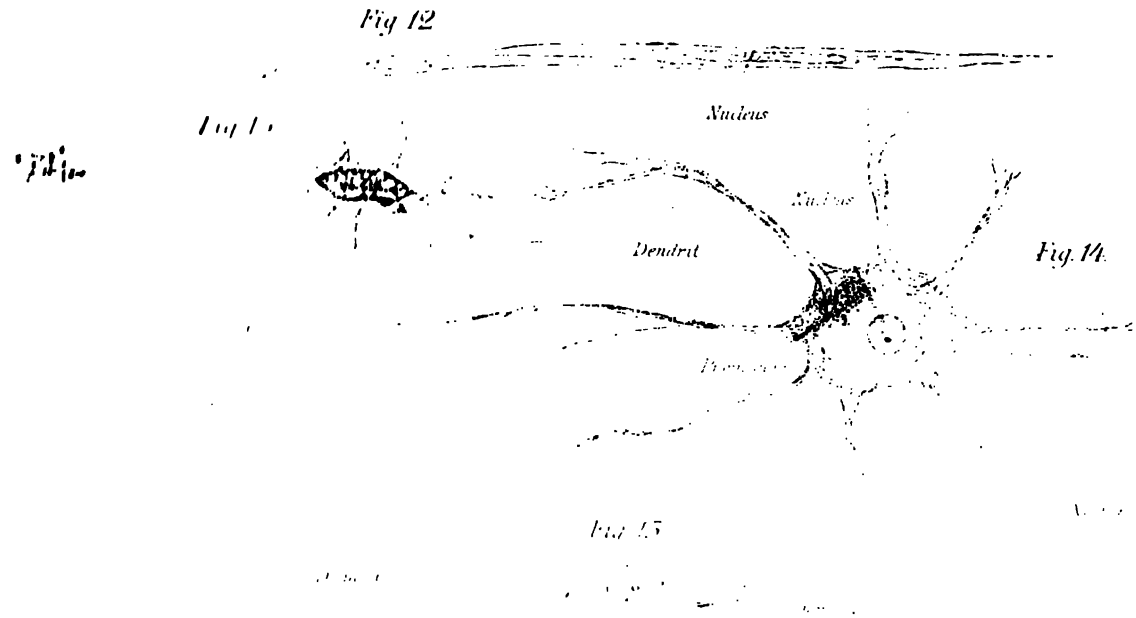
Fig 12
Nucleus
Dendrit
Fig. 14.

A 2. CELL FORMS—PROTOPLASMIC MODIFICATIONS.

FIG. 1. **Mature Ovum (×300)**, consisting of a spherical mass of protoplasm containing food material, or *yolk*, and enclosed by a distinct membrane with a radial structure, the *zona radiata*. Lying rather below the centre of the protoplasm is a nucleus, here called the *germinal vesicle*, with a nucleolus, the *germinal spot*. Carmine.

FIG. 2. **Two Columnar Epithelial Cells from an Intestinal Gland.**—The nuclei are stained red, and show distinctly the chromatin fibres, nucleoli, and the nuclear membrane; the protoplasm is paler in colour, and shows a network, *the spongioplasm*, stained yellowish-brown.

A striated appearance of that border of the cell directed towards the gland lumen is to be noticed (*the striated free border, or cuticula*). Chromic and osmic acids; acid carmine.

FIG. 3. **Ciliated Epithelium from the Trachea.**—The cells are more or less columnar in shape, and possess fine hair-like processes (*cilia*) projecting from their free borders. Just below the origin of the cilia the protoplasm shows a striated appearance. Between the ciliated cells are smaller irregular cells (*Débove's membrane*).

FIG. 4. **Epithelial Cells.**—Square in cross-section, irregularly polygonal when seen from the surface. Hæmatoxylin.

FIG. 5. **Epithelial Cells.**—Oblong in cross-section; surface view like the last. Methylene blue.

FIGS. 6 and 6*a*. **Squamous Epithelium from the Mucous Membrane of the Cheek,** consisting of flattened cells, the protoplasm being much altered, the nucleus small and often surrounded by small granules.

FIG. 6. **Seen in Section.**—Flat, spindle-shaped, slightly larger in the middle around the nucleus.

FIG. 6*a*. **Seen from the Surface.**—Irregularly polygonal in shape; the edges are often turned up. Picro-carmine.

FIG. 7. **Columnar Epithelium from a Villus of the Small Intestine,** showing characters similar to those of Fig. 2, the striated free border, or cuticula, being well marked.

Lying between these cells, *e.g.* at *x*, are goblet-cells, which have discharged their secretion. *Cf.* Plate G 8, Fig. 9. *b*, a cell of the subjacent connective tissue. Hæmatoxylin, eosin.

FIG. 8. **Liver Cells.**—The cells are polygonal in outline, whatever be the direction of section, since the liver cells themselves are polyhedral in shape.

The protoplasm is pigmented, and contains granules of various kinds; the nucleus is large, round or oval, and shows the intranuclear network distinctly.

The blue spaces at the angles of the cells are *blood capillaries* in section; the pink spaces which are generally situated between the borders of adjacent cells are *intercellular bile-ducts*.

FIG. 9. **Pigment Epithelium of the Retina, seen from the Outer Surface.**—The

individual cells are more or less regularly hexagonal, and are bound together by clear, non-pigmented intercellular substance. The oval nuclei can be seen through the central part of the cell, which is somewhat less pigmented than the periphery.

FIG. 9*a*. **Two of the Cells (lateral view).**—The outer part, or body, of the cell rests against the choroid, and contains the nucleus, while from the under surface of the cell (*i.e.*, the inner side when *in situ*) are given off delicate protoplasmic fibrils, which surround the rods and cones of the retina. 9 and 9*a*, carmine.

FIG. 9*b*. **Shows the Nature of the Pigment,** which consists of very fine crystals, shown very highly magnified in the figure.

FIG. 10. **Pigment Cells from the Skin of the Head of the Pike** (preparation by Professor Solger, Berlin collection).—*N*, A double nucleus; around this the protoplasm, showing a concentric arrangement of its granules round a central point—the *attraction sphere*, CA.

The pigment is arranged in irregular radiating threads.

FIG. 11. **Endothelial Cells from the Peritoneum,** after treatment with chromic acid and silver nitrate. The cell margins are marked out by the deposition of reduced silver in the intercellular substance, and are seen to be irregular and sinuous. Occasionally small spaces are left between the cells. In transverse section the cells are quite flat, somewhat as in Fig. 6.

FIG. 12. **Elongated, Spindle-shaped, Plain Muscle Fibres.**—The nucleus is long and rod-shaped, and situated in the axis of the cell; the contractile substance is arranged round it, and shows a fine longitudinal fibrillation. The manner in which the individual cells are arranged to form tracts of muscle is also indicated. Carmine.

FIG. 13. **Two Connective-tissue Cells, with Ramifying Processes.**—The nuclei are large and irregular in shape. Methylene blue.

FIG. 14. **A Nerve Cell from the Spinal Cord.**—It possesses many processes, and is hence called a *multipolar* nerve cell, but only the main branches of these processes are indicated; one (that directed downwards and to the right in the figure) acquires a medullary sheath, and is known as the *axis cylinder process*; the others all branch and ramify (without anastomosing, according to Golgi and others), and are known as *dendrites*. Carmine.

FIG. 15. **A Smaller Nerve Cell with Fewer Processes.**—Carmine.

A.3.
Fig. 1.
Fig. 2.
Fig. 3.
Fig. 4.
Chromatin
Fig. 5.
Fig. 6.
Fig. 7.
Stroma
Fig. 8
Centrosomata
Nucleus
J. Bruss, fec.

A 3. CELL DIVISION—KARYOKINESIS.

THE resting nucleus consists of a membrane enclosing a nuclear matrix, in which are an intranuclear network and small spherical refractive bodies, the nucleoli.

The nuclear membrane, the network, and the nucleoli, all take stains readily, and are spoken of as *chromatic*, the matrix being, on the other hand, *achromatic*, composed of achromatin.

FIGS. 1-4. **Nuclei with Varying Arrangements of the Chromatin.**—This latter substance undergoes changes in a more or less regular manner during the process of division, and it has therefore been carefully studied; but the changes occurring in the great mass of the cell—the actual protoplasm—are much more difficult to study, and still require careful investigation.

FIG. 1. **Nucleus (Germinal Vesicle) of the Mature Human Ovum** (×**750**).—Its margin is deeply stained, and is well marked, forming apparently a distinct membrane. The germinal spot is violet, and has several small bodies adjacent to it. (*Cf.* Plate L 2, Fig. 1.) Hæmatoxylin, eosin.

FIG. 2. **Ovum of a Human Fœtus of Seven Months** (*cf.* Plate L 1, Figs. 3 and 4).—The nucleus is very large, and contains a large nucleolus, and also a large amount of chromatin granules, arranged so as to form a distinct network.

FIG. 3. **Nucleus of the Ovum of Proteus Anguineus** (×**150**).—Peripherally lying just beneath the nuclear membrane is a series of chromatin granules, while in the inner part there is an arrangement of ramifying chromatin bands. 5 per cent. sublimate, acid carmine.

FIG. 4*a*. **Nucleus of a Frog's Ovum in Process of Maturation** (×**250**).—Numerous processes, like pseudopodia, are given off from the outer part of the nucleus into the cell protoplasm (probably for purposes of nutrition), and it is noteworthy that where these processes are most numerous the chromatin bodies lie scattered most thickly.

FIG. 4*b*. **A Chromatin Granule more highly magnified**, containing within it numerous highly refractive granules. 5 per cent. sublimate, acid carmine.

FIG. 5. **Direct Cell and Nuclear Division of Connective-tissue Cells from the Tail of the Salamander Tadpole** (×**1500**).—Sublimate, acid carmine.

a, A resting cell with a large nucleus.

b, *c*, *d*, Showing the appearance of a constriction in several nuclei, and simultaneous accumulation of the protoplasm towards the ends.

e, The division of the cells and nucleus being completed, the two halves are separating.

f, A nucleus seen from above; in the upper part on the right lies a small, highly refractive body (*centrosome*).

g, Shows the process of nuclear division just completed; the two halves of the nucleus are separating, and each shows a small pointed process in the act of withdrawing into the body of the nucleus (*cf. e*).

(Direct or amitotic division of cells, described by Remak, is certainly much less common than the indirect division to be subsequently described, but apparently does sometimes occur.)

FIG. 6.—**Two Lymph Corpuscles of Proteus Anguineus** (×750).—The nuclei of the corpuscles are in process of division into several parts. Sublimate, acid carmine.

FIG. 7. **A Small Lobule of the Testis of Salamandra Maculosa.**—The mother cells of the spermatozoa are arranged in small groups, all the cells of each group being in the same phase of division (which might be taken to indicate that cell division and state of nutrition are closely associated with one another).

a, *b*, *c*, *d*, *e*, Various phases of the nuclei in the process of indirect or mitotic division.

i., ii., iii., iv., Various phases of direct cell division. 5 per cent. sublimate, acid carmine.

FIG. 8. **Diagrams showing the Stages of Indirect or Mitotic Cell Division** (*i.e.*, **the process of Karyokinesis**), **according to the majority of the more recent investigators.**

a, Cell with resting nucleus. Its chromatin has a net-like arrangement; a large nucleolus is seen in the upper part. To the right of the nucleus is a small, highly refractive granule, the *centrosome*, which is in the protoplasm of the cell outside the nuclear membrane. It seems to exert a directive influence on the granules of the protoplasm, or *microsomes*.

The origin of the centrosome is doubtful. By some it is regarded as being primarily derived from the nucleus; by others, as derived from the cell protoplasm. In any case, it appears to play a not unimportant part in the process of division. It is sometimes called the *polar corpuscle*, and is occasionally double.

b, Cell at the commencement of division. The chromatin begins to lose its reticular form and to be arranged in branching bands; the microsomes, or granules of the protoplasm, now becoming arranged in definite lines, radiating from the centrosome.

c, The chromatin is now arranged as a skein of thick filaments (**the spirem stage**); there are now two centrosomata, each forming the centre of a radiating arrangement of microsomes in the cell protoplasm.

d, The nuclear membrane has disappeared. The chromatin filaments are now arranged in loops (**chromosomes**), and the two centrosomata are separating from one another.

e, Arrangement of the chromosomes about the equator (**equatorial stage**); fine lines forming the *achromatic spindle* are now seen to extend between the two centrosomata.

f, The chromosomes (here four in number) have now become arranged in a star-like manner (**aster or monaster stage**), and at the same time have each split longitudinally into two.

g, The two halves separate, the bend of each filament going towards the centrosome. This process is known as **metakinesis.**

h, Further stage of metakinesis.

i, Formation of star at each pole (**diaster stage**). The achromatic spindle begins to disappear.

k, The threads are beginning to assume a skein-like arrangement, and division is advancing in the protoplasm (**dispirem stage**).

l, **End stage with two new cells**, each with a resting nucleus.

B.—CUTANEOUS STRUCTURES.

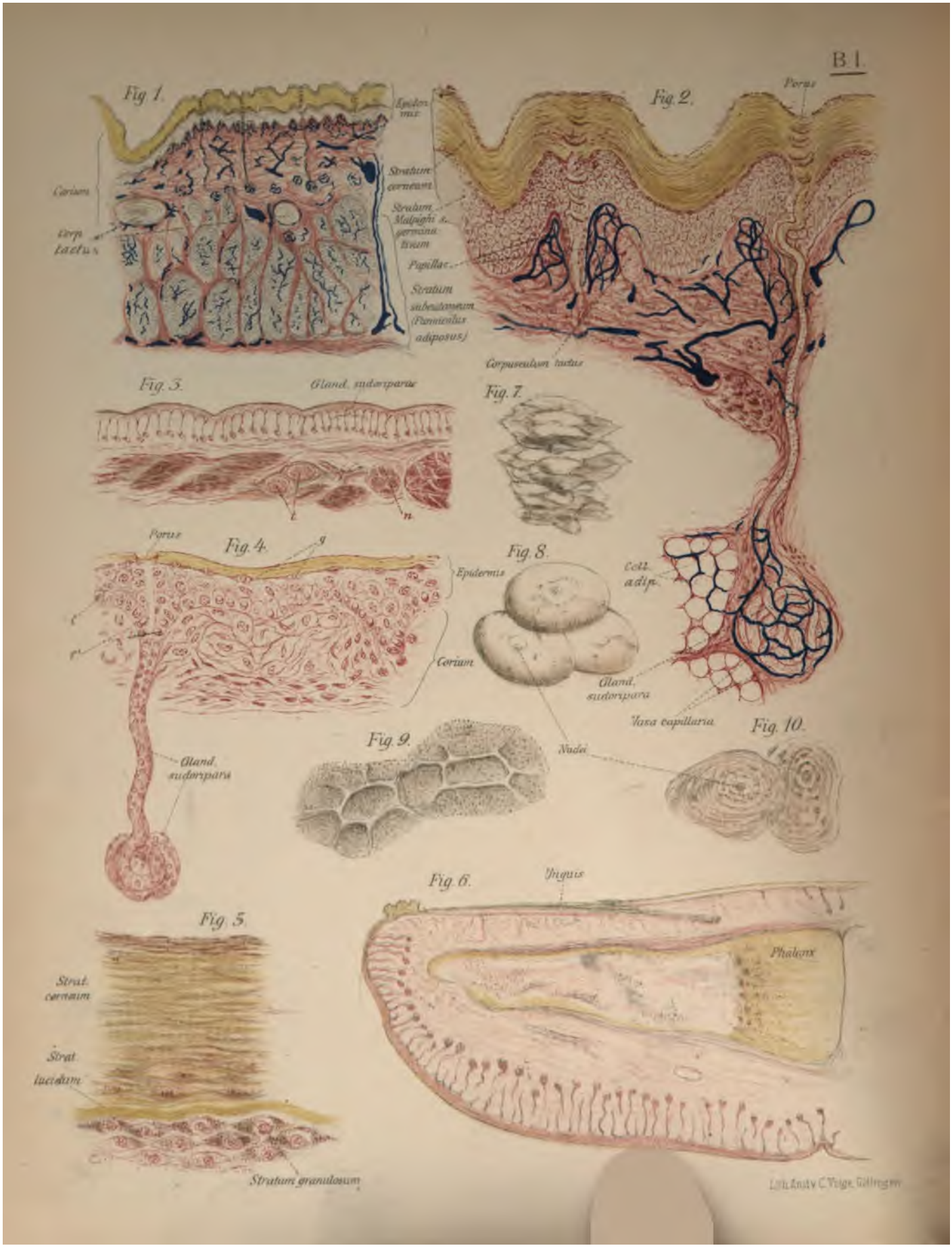
Fig. 1.
Epidermis
Stratum corneum
Stratum Malpighi s. germinativum
Papillae
Stratum subcutaneum (Panniculus adiposus)
Corium
Corp. Lactus
Fig. 2.
Porus
Corpusculum tactus
Fig. 3.
Gland. sudoriparae
Fig. 7.
Fig. 4.
Porus
Epidermis
Corium
Gland. sudoripara
Fig. 8.
Cell. adip.
Gland. sudoripara
Vasa capillaria
Nuclei
Fig. 9.
Fig. 10.
Fig. 6.
Unguis
Phalanx
Fig. 5.
Strat. corneum
Strat. lucidum
Stratum granulosum

B 1. SKIN—GENERAL OUTLINES.

FIG. 1. **Transverse Section of the Skin of the Hand, injected (×10).**—The epidermis, consisting of several layers (the outer or *horny layer* being stained yellow) rests upon the vascular *dermis or corium*, with its papillæ. Lying in the corium are two Pacinian bodies (Vater's corpuscles) in section, and several sweat glands, their coiled ducts being visible in their course through the epidermis.

The dense connective tissue of the corium merges into the looser subcutaneous tissue, which, with its abundance of fat cells, is called *panniculus adiposus*. Injected blue; stained picrocarmine. (Freudenstein.)

FIG. 2. **Part of the Last Section, more highly magnified (50).**—The capillary network around the coiled secreting tubule of a sweat gland, and the arrangement of the vessels in the papillæ of the dermis, are shown in greater detail.

The superficial horny layers of the epidermis are differentiated by the stain from the deeper protoplasmic layers, or *rete mucosum*. (Freudenstein.)

FIG. 3.—**Section through the Palm of the Hand of a Newly-born Child (×15).**—The large number of sweat glands is noticeable; subsequently they become more widely separated owing to the growth of the intervening tissues. Müller's fluid, picrocarmine.

FIG. 4.—**Part of the same Section, more highly magnified (169).**—The horny layer is stained yellow, and rests upon the rete mucosum or *rete Malpighi*—the superficial cells of which are well-developed granular cells, *g*—forming the *stratum granulosum* (*cf.* Plate B 6, Fig. 1). The deepest layer of the epithelium contains numerous cells with oval or cup-shaped nuclei, *e*, *e'*. The duct (*porus*) of the sweat gland has not yet become coiled. Müller's fluid, picrocarmine.

FIG. 5. **Part of the Epidermis from the Specimen shown in Fig. 1 (×150).**—The *stratum corneum*, or horny part of the epidermis, is seen to consist of three layers:

i., A thin layer of flattened *superficial scales*, which are being constantly desquamated.

ii., A broad layer of cells, less flattened, but showing no sign of nuclei. It forms the greater part of the horny layer, and is sometimes known as the *epitrichial layer*.

iii., A layer of clearer cells, stained bright yellow—the *stratum lucidum*. Beneath

this is the most superficial layer of the rete mucosum—the stratum granulosum. Picrocarmine. (Freudenstein.)

(NOTE.—In preparations injected with Berlin blue, and subsequently stained with picrocarmine, a most complete differentiation of the different layers of the epidermis is often obtained.)

FIG. 6. **Longitudinal Section of the Ungual Phalanx of the Thumb from an Infant (× 15).**—In situations, such as the nail-bed, where horny structures are highly developed, the sweat glands are absent. They are seen to be few in number just behind the nail-groove, but are very numerous in the skin of the palmar surface of the finger-tip. Müller's fluid, picrocarmine.

FIG. 7. **A Few Scales from the Horny Layer of the Epidermis, isolated (× 400).**—The figure shows them as seen from the surface, before the addition of reagents.

FIG. 8. **Similar Scales, after warming with Caustic Potash (× 400).**—They swell up, and the remains of the nuclei become visible.

FIG. 9. **A Few Squamous Cells from the Mucous Membrane of the Mouth (× 400).**—Scraped from the inner side of the cheek, and examined fresh.

The cells are joined to one another laterally in such a way that the intercellular substance is heaped up into small elevations or ledges, while on the surface, where one cell rests upon another, are small rods of intercellular substance to unite them. These intercellular bridges are well seen between the cells of the epidermis. (*Cf.* Plate B 6, Fig. 5.)

FIG. 10. **Two Squamous Cells after Treatment with Chromic Acid (× 400).**—The nuclei and concentric rings of granules are brought distinctly into view.

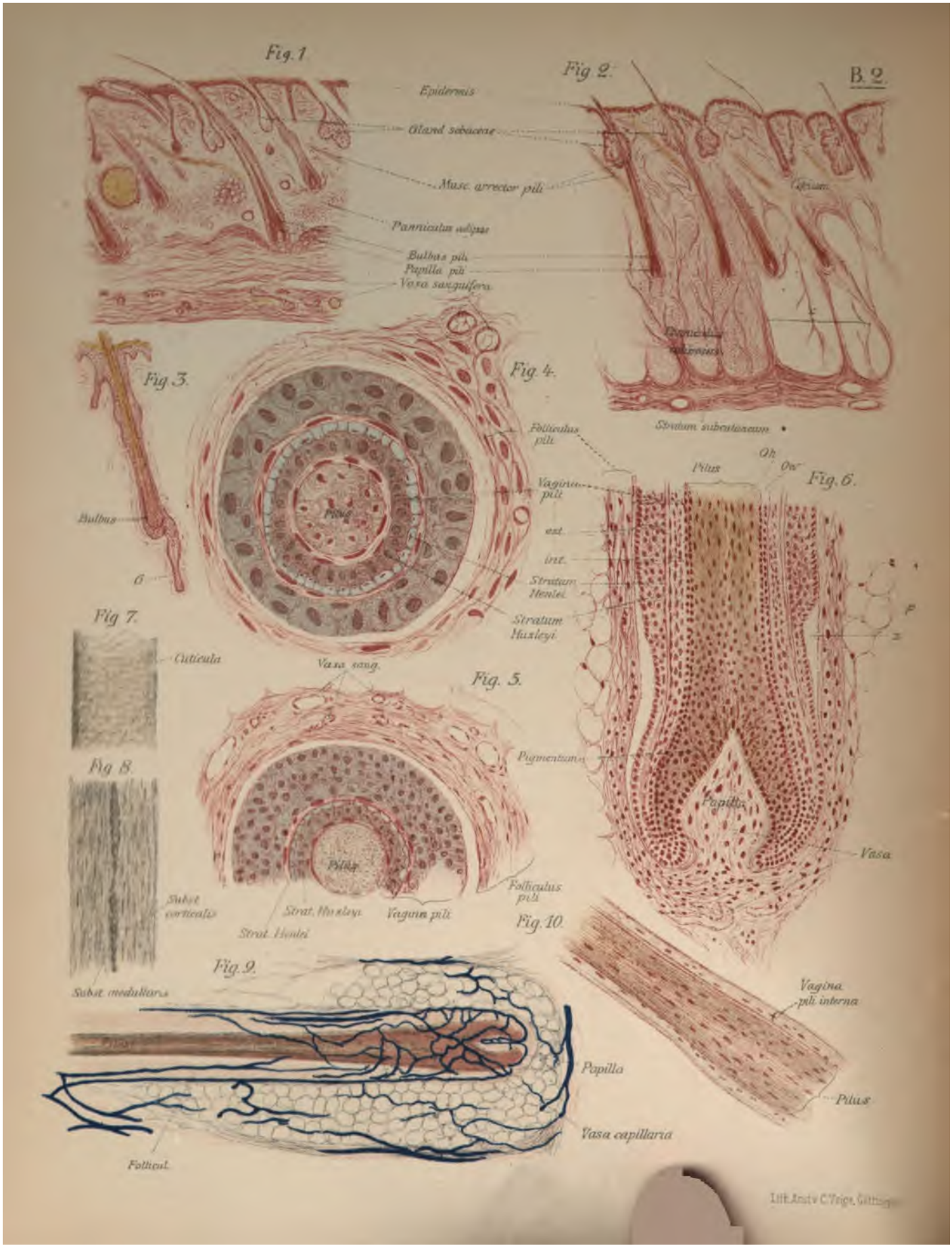

Lith. Anst. v. C. Feige, Göttingen

B 2. THE SKIN (continued)—APPENDAGES: HAIR.

FIG. 1. **Section through the Scalp of a New-born Child (×40).**—The general details are as described before: the epidermis, the cutaneous muscles (*arrectores pilorum*), and the contents of the bloodvessels are all stained yellow; the deeper layers of the epidermis, the connective tissue, and the hair follicles, red. In the middle is a hair, with its root and follicle shown in complete longitudinal section. On the left side of the section the apex of a hair is seen still lying covered over by the epidermis. Chromic acid and alcohol, picrocarmine.

FIG. 2. **Section through the Scalp of an Adult (×10).**—The subcutaneous tissue (*panniculus adiposus*) is only represented on the left of the figure, the bands of connective tissue which support the subcutaneous tissue, and connect it to the structures lying beneath it, being shown on the right. Two of the hairs are seen in complete longitudinal section, showing the hair itself, or the body of the hair outside the skin, and *the root*, or that part lying in the depression or *hair follicle;* in the other two the section has only caught the hair roots, but one shows distinctly the enlargement of the root, or *hair knob*, lying over the *hair papilla*. Picrocarmine. (Waldeyer.)

FIG. 3. **A Hair from the Scalp of an Infant (×60).**—From just below the hair root a cylindrical process of cells G, derived from the hair papilla, passes downwards, and constitutes the rudiment of a new hair. At first the rudiment is composed of protoplasmic cells, but later the central ones become modified to form the hair medulla and the hair scales, as in the formation of the original hair. Picrocarmine.

FIG. 4. **Transverse Section through the Root of a Small Hair just above the Papilla (×800).**—Showing the structure of the hair follicle, and the *root-sheaths* which line it and invest the hair root, which is here cut just above the papilla, and therefore consists of soft, protoplasmic cells, actively growing. Double-stained. (Waldeyer.)

The hair follicle examined from without inwards presents:

1. A connective-tissue network—the dermic part of the follicle (*folliculus pili*)—consisting of connective-tissue fibres and cells, arranged for the most part circularly, and enclosing bloodvessels (*vasa sanguifera*).

2. A clear, membranous structure—*the hyaline layer*—separating the connective-tissue part of the follicle from the epithelial root-sheaths.

NOTE.—In this section the root-sheath has contracted to some extent, leaving a space between itself and the connective-tissue layer, in the situation of the hyaline layer.

3. *The root-sheath*—an epithelial sheath which is very closely applied to the hair root, and consists of two layers:

(*a*) *The outer root-sheath*—stained purplish in the section, consisting of several layers of soft, protoplasmic, non-flattened cells, continuous with the Malpighian layer of the epidermis.

(*b*) *The inner root-sheath*—itself consisting of three layers:

(i.) *Henle's layer*—consisting of elongated cells, stained blue in the figure; many of them non-nucleated.

(ii.) *Huxley's layer*—stained purplish, lying immediately internal to Henle's layer, and consisting of softer polyhedral cells with distinct nuclei.

(iii.) *The cuticle of the root-sheath*—stained pink, which must be distinguished from the *cuticle of the hair* itself, with which in the section it is seen to be in close relation.

FIG. 5. **Transverse Section through the Root of a Coarser Hair from the Scalp (×250).**—The section has caught the hair follicle higher up than in Fig. 4—*i.e.*, considerably above the hair knob—so that the cellular structure of the hair is less distinct, the hair consisting in this situation of elongated fibrillated cells enclosed by the *hair-cuticle*.

The layers of the root-sheath are exactly as in Fig. 4.

FIG. 6. **Longitudinal Section of the Root of a Hair from the Scalp (×150).**—The vascular hair papilla is distinctly seen, and the soft, growing protoplasmic cells of the hair knob fitting over it; some of these cells are seen to be pigmented and to possess branching processes. A little higher the cells composing the hair become longer and narrower.

The layers of the root-sheath and hair follicle as in Fig. 4.

At *x* the outer root-sheath has withdrawn from the hyaline layer of the follicle, and on pulling out such a hair, the entire root-sheath is frequently removed with it.

p, Fat cells of the panniculus adiposus around the hair follicle.

O, *h*, Hair cuticle. *O*, *w*, Cuticle of inner root-sheath. Müller's fluid, acid carmine. (Merkel.)

FIG. 7. **Part of the Surface of a Hair outside the Hair Follicle (×150).**—The irregular margins of the flattened, imbricated scales forming the hair-cuticle are seen.

FIG. 8. **Shaft of a Hair, the Microscope being focussed on the Central Part (×150).**—Centrally the dark substance or *medulla*, around which is the fibrous material of the hair, consisting of elongated cell-remains; investing the whole, the *hair cuticle*.

FIG. 9. **Hair Root, with the Surrounding Adipose Tissue (×40).**—The bloodvessels are injected blue; a loop of capillaries penetrates the papilla, while around the hair root is a wide-meshed capillary network.

FIG. 10. **Part of the Shaft of a Hair with the Inner Root-sheath adherent to it.**

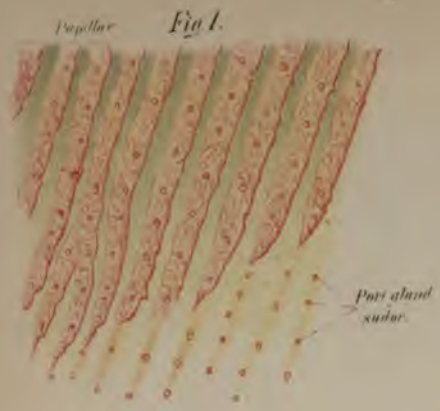
Papillae
Fig 1.
Pori aland sudor.

Fig. 2.


Fig 3.
Epidermis

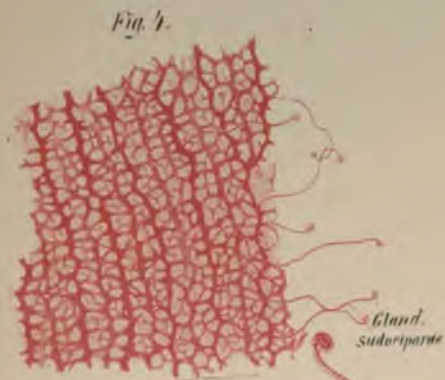
Fig. 4.
Gland. sudoriparae
Papillae

Vallum unguis
Fig. 6.
Unguis
Matrix unguis
Stratum granul.

Fig. 7.
Corium
Matrix ung.
Radix ung.

Fig. 5.

Fig 8.
Unguis
Matrix ung
Corium
Radix
Pedo
Phalanx

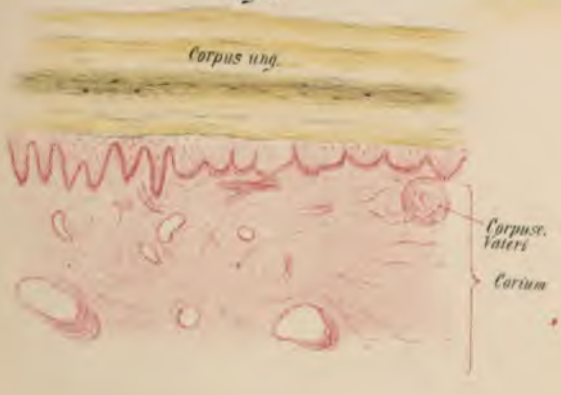
Fig. 9.
Corpus ung.
Corpusc. Vateri
Corium

Stratum corneum
Fig 10.
Vallum ung.
Matrix unguis
Stratum granules

A. Graux fec.

B 3. THE SKIN (continued)—PAPILLÆ, NAILS.

FIG. 1. **Horizontal Section of the Skin of the Finger-tip, slightly oblique** (×15).—The papillæ are seen to be arranged in rows or lines, several of which are cut across in the section. These rows of papillæ form the small lines seen with the naked eye in such situations as the finger-tips and palm of the hand.

The ducts of the sweat glands lie in the middle line of each of these rows, and open on to the surface by small orifices or *pores*. Picrocarmine. (Waldeyer.)

FIG. 2. **Distribution of the Blood-vessels in the Rows of Papillæ and the Corium below them** (×20.)—The section is oblique, in the upper part being deeper, and passing through the tissues of the dermis; in the lower part more superficial, through the epidermis, the small vessels in the lower part being in the papillary elevations of the dermis, and not in the epidermis itself, which is non-vascular. Injected specimen. (Waldeyer.)

FIG. 3. **Elastic Network in the Skin** (×20).—A fine network of elastic fibres exists in the corium, and very fine fibres pass up into the papillæ. (Preparation by Weigert, in the Berlin collection.)

FIG. 4. **Papillary Part of the Skin, separated and stained** (×25).—On the right some sweat-glands have also been removed. Carmine. (Waldeyer.)

FIG. 5. **Part of the Last Preparation** (×100).—The papillæ of the dermis passing up into the Malpighian layer render it irregular and reticular, hence its name *rete Malpighi*. Two sweat glands are shown throughout their length. Carmine. (Waldeyer.)

FIG. 6. **Transverse Section of the Nail of a Seven-Months Fœtus** (×80).—The nail, which is distinctly developed, is stained yellow, and is seen to rest upon the *stratum granulosum* of the rete, which, with the corium beneath, is here known as the *nail-bed*.

The papillæ of the nail-bed, well marked at the side, are more closely packed and flatter at the middle of the nail. Chromic acid, picrocarmine.

FIG. 7. **Longitudinal Section of the Finger-nail and its Bed from an Adult** (×8).—The nail (stained yellow) is seen to dip deeply into the *nail groove*, forming the *root of the nail;* the part of the bed in this situation is called the *nail matrix*, and is the part concerned in the growth of the nail. The papillæ, being arranged in longitudinal rows, are not seen in this section. Picrocarmine. (Waldeyer.)

FIG. 8. **Longitudinal Section at the Situation of the Root of the Thumb-nail, from an Infant** (×60).—Sweat glands, which, as stated above, are absent in the region of the nail, are seen to occur in the skin immediately behind it. Picrocarmine. (Waldeyer.)

FIG. 9. **Cross-section of the Nail and Nail-bed of an Adult (×60).**—The nail itself is seen to consist of several layers, and is practically a greatly thickened stratum lucidum, the epitrichial layer having disappeared, except over the lunula, or white part of the nail near the matrix.

The papillæ of the nail-bed are seen in section; they run longitudinally, and constitute elongated ridges rather than separate papillæ. A *Pacinian body* (*corpusc. Vateri*) is seen in the connective tissue beneath the papillæ. Picrocarmine. (Waldeyer.)

FIG. 10. **Cross-section of the Nail of a Seven-Months Fœtus near the Finger-tip (×100).**—The nail-bed is seen to be continuous with the Malpighian layer of the skin; the nail, with the lower part of the stratum corneum (*stratum lucidum*). Chromic alcohol, picrocarmine.

B. 4. THE SKIN—NERVES AND SENSORY END-ORGANS.

FIG. 1. **Section of the Skin of the Toe (×70).**— Three *tactile corpuscles* (*corpuscula tactûs*) are seen projecting into the papillæ of the corium. Gold chloride, Ranvier's method. (Merkel.)

FIG. 2. **A Tactile Corpuscle from the Sole of the Foot, more highly magnified (650).**— Two nerve fibres enter the corpuscle from below. (*Cf.* Figs. 9, 10.) Gold chloride. (Merkel.)

FIG. 3. **Section through the Skin of the Pig's Snout (×260).**—*Merkel's tactile cells* are seen in the deeper layers of the rete Malpighi. A nerve fibre passes to each tactile cell; on the right some larger nerve fibres are shown. Gold chloride. (Merkel.)

FIG. 4. **Section of the Skin of the Dog's Nose (×30).**—Numerous nerve fibres pass from below (the corium) into the papillæ and the rete Malpighi. Ramon-y-Cajal's silver method. (Merkel.)

FIG. 5. **A Part of the same Preparation more highly magnified.**—The nerve fibres are seen to extend deeply into the Malpighian layer.

FIG. 6. **Section of the Skin and Mucous Membrane of the same Dog's Nose (× 15).**— On the left of the specimen, the nerve fibres are seen ramifying in the subcutaneous tissue. On the right the large and small ducts of mucous glands are also marked out by the reduction of the silver salt. Ramon-y-Cajal's silver method. (Merkel.)

FIG. 7. **A Tactile Hair from the Cat.**—Around the hair is applied Bonnet's basket-like nerve plexus, with small nerve-cells attached to the nerve fibres. (Merkel.)

FIG. 8. **Nerve Fibres and End-cells from the same Preparation more highly magnified.** The nerve fibres appear varicose, and the cells are oval in shape. (Merkel.)

FIG. 9. **Cross-section of a Tactile Corpuscle from the Finger-tip (×325).**—The centre of the corpuscle is not occupied by a central core, as in the Pacinian bodies, but is composed of connective tissue in which the nerve fibre or fibres wind. (Merkel.)

FIG. 10. **Tactile Corpuscle from the Finger-tip (palmar surface) of Man (×325).**—A well marked nerve fibre passes to the corpuscle from below, and is seen in section in the body of the corpuscle. (Merkel.)

Fig. 1.

Fig. 3.

Fig. 2.

Fig. 5.

Fig. 4.

Fig. 6.

Fig. 7.

Fig. 8.

Fig. 9.

Fig. 10.

A. Brass fec.

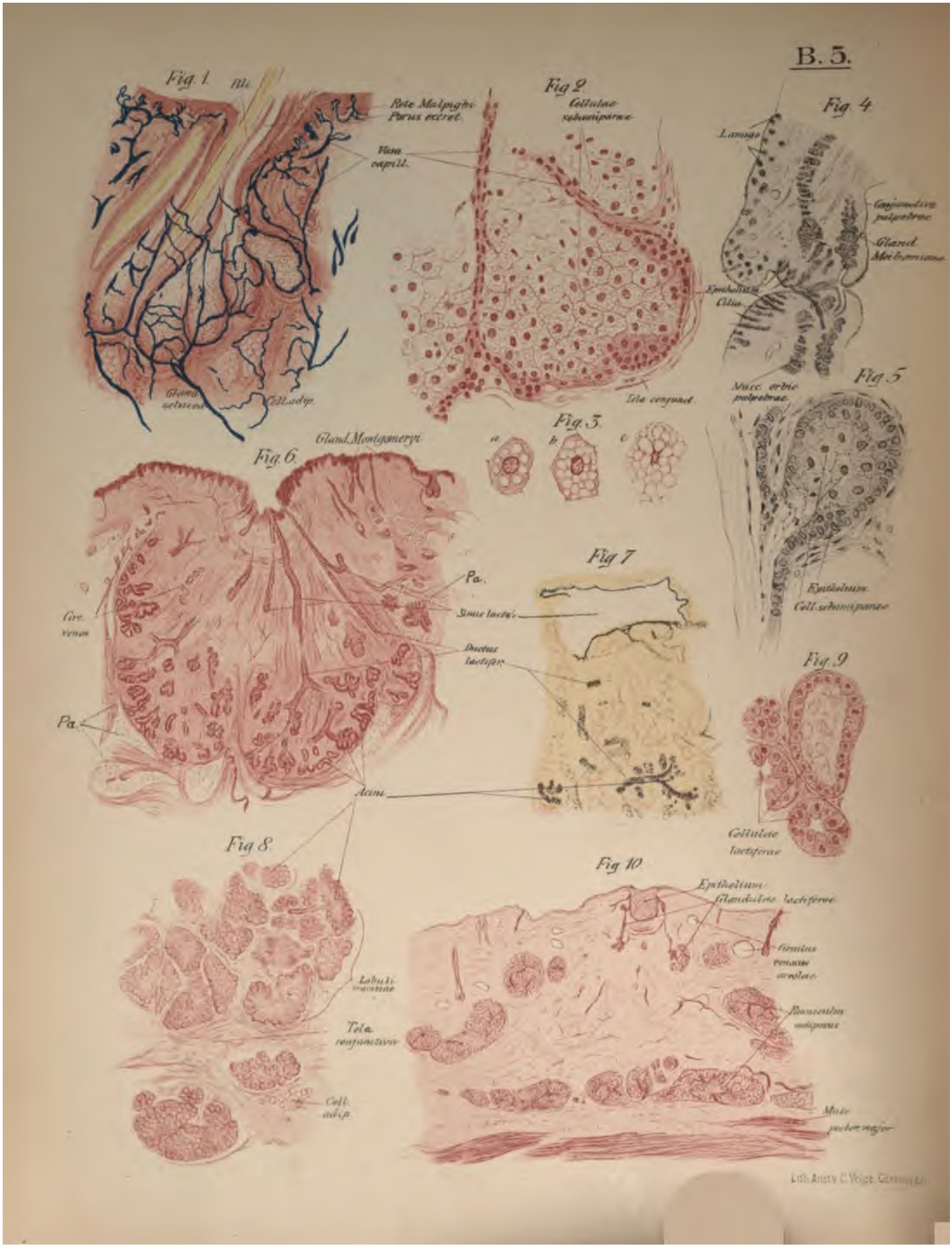
B. 5.
Fig. 1.
Rete Malpighi
Porus excret.
Vasa capill.
Cell. adip.
Fig. 2.
Cellulae sebumiparae
Tela conjunct.
Fig. 4.
Lamiae
Conjunctiva palpebrae
Gland. Meibomiana
Epithelium
Cilia
Fig. 5.
Musc. orbic. palpebrae
Epithelium
Cell. sebumiparae
Fig. 3.
a
b
c
Fig. 6.
Gland. Montgomeryi
Pa.
Sinus lactis
Ductus lactifer.
Pa.
Acini
Fig. 7
Fig. 9
Cellulae lactiferae
Fig. 8.
Lobuli mammae
Tela conjunctiva
Cell. adip.
Fig. 10
Epithelium
Glandulae lactiferae
Circulus venosus areolae
Musc. pector. major
Lith. Anst. v. C. Voigt, Göttingen

B. 5. THE SKIN—SEBACEOUS GLANDS, MEIBOMIAN GLANDS. THE MAMMARY GLAND.

FIG. 1. **Section of the Scalp, injected blue** (×35).—Two hair follicles are cut across obliquely; to the right the acini and duct of a sebaceous gland are shown in section. The duct usually opens into a hair follicle, near the surface. The acini of the gland are surrounded by a wide-meshed capillary network. Picrocarmine. (Reichenbach.)

FIG. 2. **Part of a Section through the Acini of a Sebaceous Gland** (×200).—Lying at the periphery and lining the acinus is a layer of cells, which contain only few fat droplets, stain darkly, and in the living state actively divide to form fresh sebaceous cells, which pass towards the centre of the acinus and go to form cells of the middle zone, with very numerous fat droplets (in this section the fat has been removed by benzol, so that the cell substance appears spongy). The cells most centrally placed, filling up the acinus and extending towards the duct, are in process of disintegration, so that the fatty material is set free, forming the secretion or sebum. Müller's fluid, acid carmine. (Merkel.)

FIG. 3. **Isolated Cells from a Sebaceous Gland** (×300).—*a* A cell from the border zone, with only a few fat droplets and much unaltered protoplasm.

b A cell from the middle zone, with abundant fat-droplets.

c A cell near the duct in process of disintegration, nearly all the protoplasm being replaced by fat. Müller's fluid, acid carmine. (Merkel.)

FIG. 4. **Section through the Eyelids of a Six or Seven Months Fœtus** (×10).—The lids are still closed, and although all the other tissues still present distinct embryonic characters, the *Meibomian glands* are already well developed and produce fat, like the cells in the sebaceous gland of Fig. 2. Alcohol, hæmatoxylin.

FIG. 5. **Acinus of a Meibomian Gland more highly magnified (300).**—The specimen shows that the cells of this gland and the changes in them associated with the process of secretion very closely resemble those occurring in the sebaceous glands, so that the Meibomian glands are regarded as modifications of the latter. Alcohol, hæmatoxylin.

FIG. 6. **Section of the Mammary Gland of a New-born Male Child** (×5).—The *galactoferous ducts*, each with a dilatation, the *sinus lacteus*, are seen converging towards the nipple, where they open by small pores. From the sinus lacteus pass off smaller tubules —lactiferous tubules (*ductus lactifer.*)—to the acini of the gland, which are arranged in lobes, and are well developed in this specimen. (In some cases a small amount of secretion may occur in the acini of the mammary gland of male children.)

The body of the gland is embedded in the panniculus adiposus (*P.a.*). Similar

appearances are presented by *Montgomery's glands*, which lie around the nipple, in the areola; they are practically small, undeveloped milk glands, and are best marked during lactation. (Merkel.)

FIG. 7. **Section through the Mammary Gland of a Non-lactating Woman** (×20).—The ducts and acini appear as dark areas lying in the connective tissue and fat; in the upper part a *sinus lacteus* is seen in section. Unstained preparation. (Merkel.)

FIG. 8. **Acini from the Breast of a Lactating Woman** (×50).—The connective and adipose tissue is now much less abundant in proportion to the secreting gland tissue than formerly, owing to the increased development of the latter to prepare for lactation. Carmine. (Merkel.)

FIG. 9. **Acini from the same Preparation more highly magnified (250).**—The acini are larger than in the non-lactating condition, and contain fat globules; the cells lining the acini are more or less cubical in shape, instead of being flat, as in the non-secreting mammary gland. On the left, in the upper part of the section, a few cells belonging to another acinus are seen from the base or attached surface.

FIG. 10. **Section through the Developing Mammary Gland of a Six-Months Female Embryo** (×12).—The epithelium in the situation of the future nipple is much thickened, and sinks like a plug into the subjacent tissue.

From this epithelial plug the galactoferous ducts pass off laterally in various directions; two such are shown in the section. The gland substance grows downwards into the panniculus adiposus, between the fat lobules. Chromic acid, acid carmine.

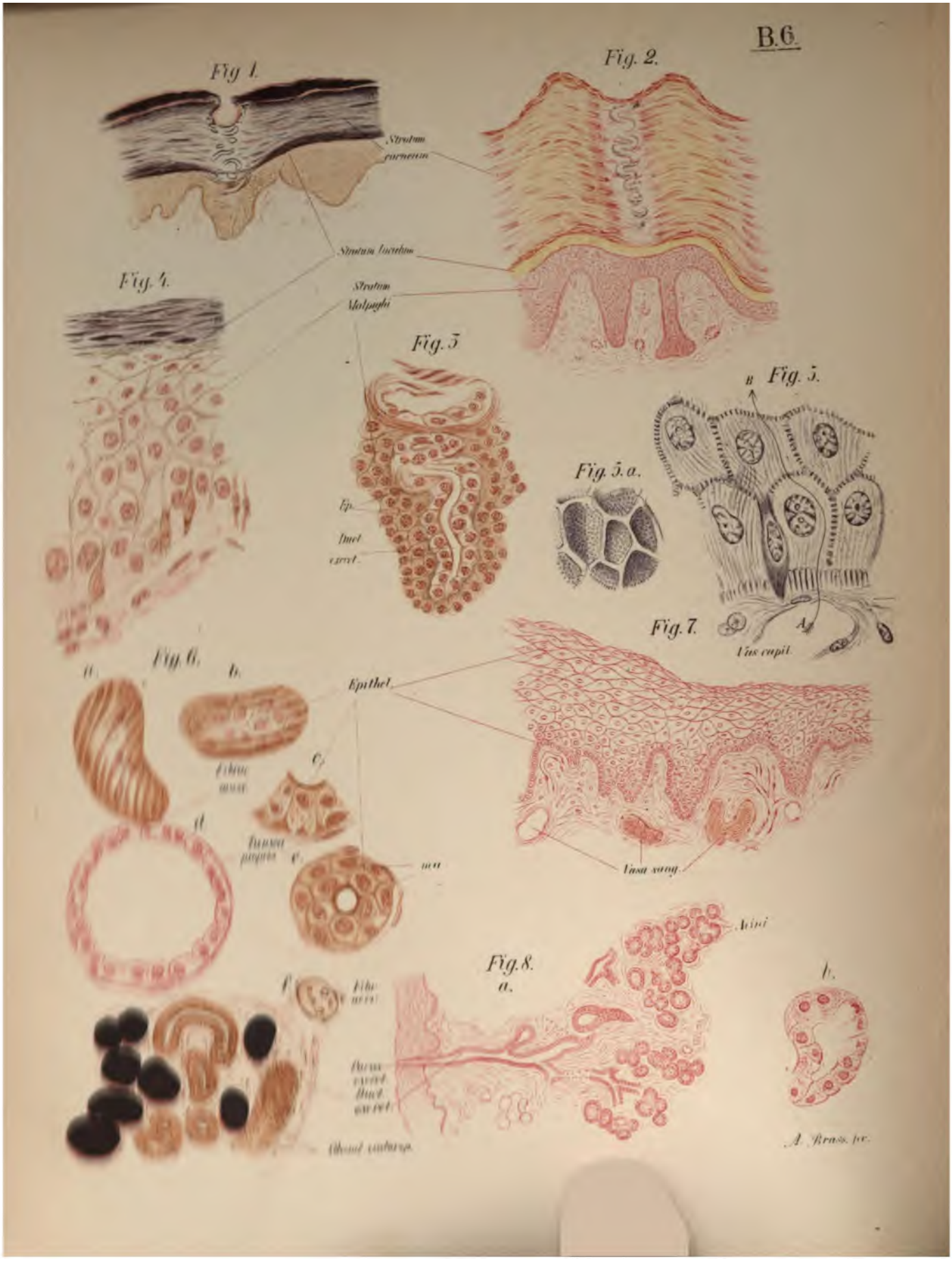
B.6.
Fig. 1.
Fig. 2.
Stratum corneum
Stratum lucidum
Stratum Malpighi
Fig. 4.
Fig. 3
Ep.
Duct excret.
Fig. 5.
B
Fig. 5. a.
A
Vas capil.
Fig. 7.
Epithel.
Vasa sang.
Fig. 6.
a.
b.
c.
d.
e.
f.
Fig. 8.
a.
b.
Acini
A. Brass. fec.

B 6. THE SKIN—EPIDERMIS—SWEAT GLANDS. THE LIPS.

FIG. 1. **Skin of the Palmar Surface of Finger-tip, treated with Osmic Acid (× 70).**—The horny part of the epidermis shows the three layers already described (*cf.* Plate B 1, Fig 5). The superficial cuticle and the deep stratum lucidum are both darkly stained owing to the reduction of the osmic acid. The coiled duct of a sweat gland passes through the epidermis, several windings being here shown in section. Flemming's fluid, acid carmine. (Merkel.)

FIG. 2. **Epidermis from the Sole of the Foot (× 30).**—The horny layer is relatively much thicker, as is the rule in parts subjected to intermittent pressure; the stratum lucidum is again well shown. The coils of a sweat duct are here shown completely. Alcohol, picrocarmine. (Meyer.)

FIG. 3. **Duct of a Sweat Gland in the Rete Malpighi of the Specimen represented in Fig. 1 (× 350).**—The duct is lined by cells which seem to be differentiated from the cells of the rete even in the embryonic condition* (*cf.* Plate B 1, Fig. 4). Flemming's fluid, acid carmine. (Merkel.)

FIG. 4. **Deeper Cells of the Epidermis from the same Preparation (× 750).**—The *stratum lucidum*, the deepest stratum of the horny part of the epidermis, rests upon a layer of flattened cells, containing granules of *eleidin* (the *stratum granulosum*), then follows a layer several cells deep (the layer of *prickle cells*), the cells being irregularly polyhedral in shape; they are separated by small intercellular spaces, which are bridged across by fine fibres serving to unite the cells to one another. The mos deeply placed cells are longer and more regular in shape, and possess numerous fine processes which are directed towards the vessels of the corium, and no doubt assist in deriving nourishment for the cells. Flemming's fluid, acid carmine. (Merkel.)

FIG. 5. **Cells from just above the Corium, highly magnified (slightly diagrammatic).**—The deepest cells again show the processes directed towards the vessels. Where the margins of several (generally three) cells come together, the intercellular substance is in the form of a ridge, while where the flat surfaces of two cells come together it is in the form of small rods (Fig. 5*a*). From cell to cell a stream of lymph or plasma passes, as described by Ranvier.

FIG. 6. **Details of the Structure of Sweat Glands.**—*a*, A small secreting canal from the coiled part of the gland. There is a layer of oblique nucleated fibres (probably

* The coiled part of the sweat duct in the epidermis is, however, generally described as simply a passage between the epithelial cells of the epidermis.—TRANSLATOR.

plain muscle fibres, though this is not absolutely certain) between the basement membrane and the epithelial cells of the gland; the outlines of the latter can be indistinctly seen through the fibres.

b, Section a little deeper, the muscle fibres being for the most part shaved off; the epithelial cells are now clearly seen.

c, Section of a part of a gland tubule. The basement membrane is shown with the muscle fibres in transverse section resting upon it, and the epithelial cells internal to them.

d, Cross-section of a secreting tubule; the lumen is greater than that of the duct *e*.

e, Cross-section of a duct from the convoluted part of the gland. There is a basement membrane, two layers of epithelium, but no muscular tissue; the lumen is small, and is lined by a distinct cuticle. (*a*—*e* × 600.)

f, Cross-section of a coil of a sweat gland, with fat cells around it stained black by osmic acid. (×210.) The gland tubules are seen in longitudinal and cross-section, and one part shows the investment of oblique muscle fibres. Flemming's solution, acid carmine. (Merkel.)

FIG. 7. **Transition of the Epithelium of the Lip into that of the Mucous Membrane of the Mouth, from a Seven-Months Fœtus** (×150).—The epithelium of the mouth is thinner and the papillæ broader and less regular than those of the lip. Chromic acid, acid carmine.

FIG. 8*a*. **Section of a Mucous Gland and its Duct from the Lip of a Seven-Months Fœtus** (×70).—These glands are well developed and functionally active at this stage. The duct branches repeatedly, the small ductules passing to the alveoli of the gland.

FIG. 8*b*. **Section through an Alveolus of the Gland** (×350). — The cells are characteristic *mucous cells*, the inner part of the cell being swollen out with mucin, which replaces the protoplasm and does not stain. Chromic acid and alcohol, acid carmine.

C.—SENSE ORGANS.

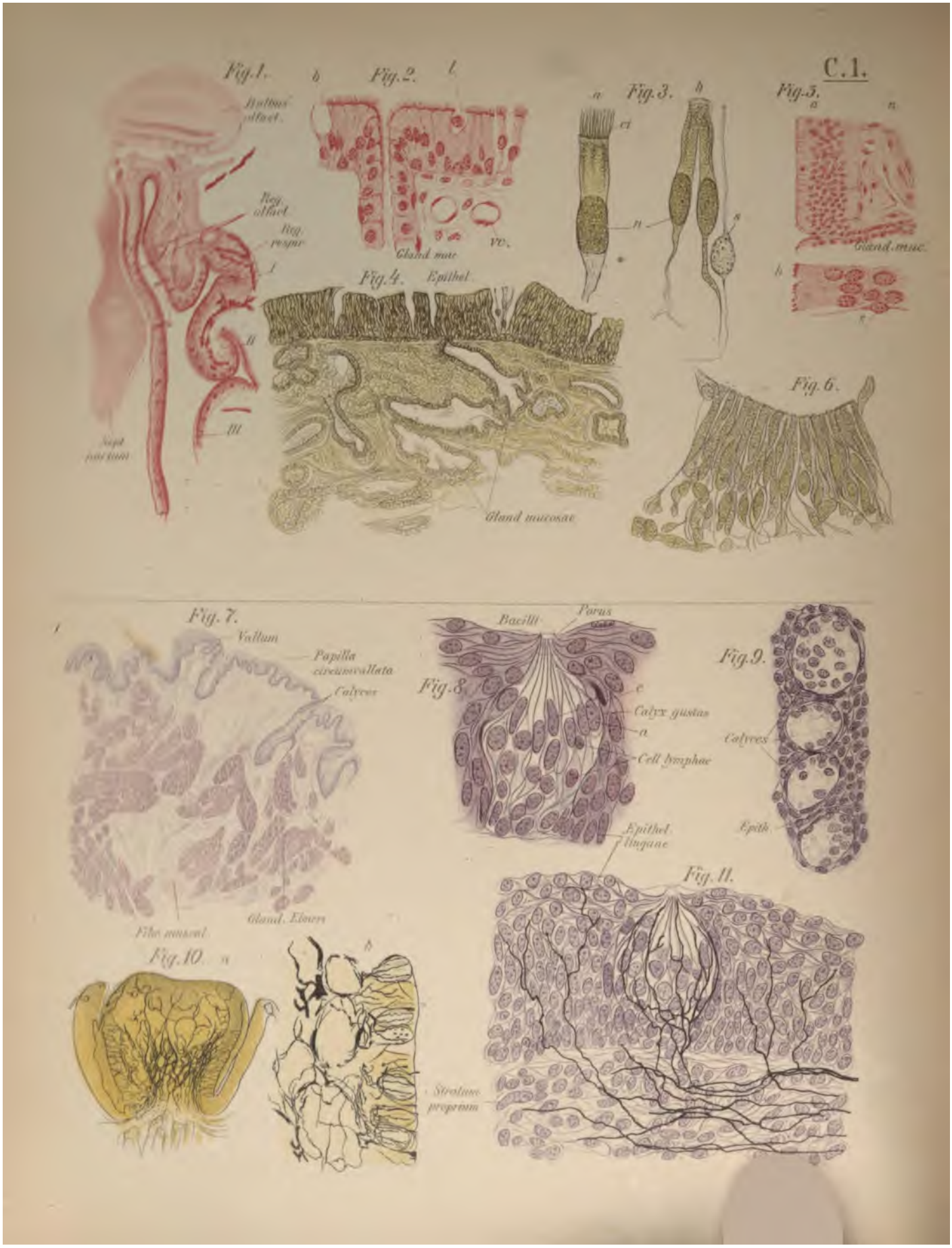
C.1.
Fig.1.
Fig.2.
Fig.3.
Fig.5.
Fig.4.
Epithel
Gland mucosae
Fig.6.
Fig.7.
Vallum
Papilla circumvallata
Calyces
Fig.8.
Bacilli
Porus
Calyx gustus
Cell lymphae
Fig.9.
Calyces
Epith.
Fig.10.
Fig.11.
Epithel linguae
Stratum proprium

C 1. SENSE ORGANS—SMELL AND TASTE.

FIG. 1. **Section of the Posterior Part of the Nasal Cavity of a Seven-Months Fœtus** (×7).—In the upper part is the *olfactory bulb;* the septum narium lies to the left.

The olfactory region (*regio olfactoria*) of the nasal mucous membrane extends down the septum, and down the lateral wall as far as the two red asterisks marked in the figure. The mucous membrane in this region contains only few of the larger mucous glands, but the bundles of the olfactory nerve fibres (stained red) can be distinguished even with this low magnification, especially at the side of the septum.

I., II., III., The upper, middle, and lower turbinated bones.

The respiratory region (*regio respiratoria*) extends* from the asterisk on the upper turbinated bone, over the middle and lower turbinated bones, across the floor of the nasal cavity, and up the nasal septum as far as the asterisk. Chromic acid, alcohol, acid carmine.

FIG. 2. **Part of the Respiratory Region from the Last Preparation** (×300).—The epithelial cells are elongated or columnar in shape, and bear cilia at their free margins.

l, A lymph corpuscle passing between the cells.

b, A goblet or mucoid cell.

V C, Capillary vessel in section.

The opening of the duct of a mucous gland on to the surface is shown. The ciliated epithelium extends for a short distance down the duct, and then becomes cubical and non-ciliated. Deceptive appearances may be obtained in section, epithelial knots appearing, since the ducts pass obliquely through the epithelium of the mucous membrane, and the section, as is frequently the case, does not catch the neck of the gland. Chromic acid, alcohol, acid carmine.

FIG. 3*a*. **Ciliated Epithelial Cell from the Respiratory Region of an Adult** (×500).—*ci*, The cilia; *n*, the nucleus.

FIG. 3*b*. **Two Tapering, Non-ciliated Supporting Cells from the Regio Olfactoria of an Adult,** with an *olfactory cell* (*s*) lying beside them. The branching basal processes of the supporting cells are also shown. Osmic acid. (Merkel.)

FIG. 4. **Cross-section of the Olfactory Region of an Adult, prepared with Osmic Acid** (×100).—The mucous membrane is thick, somewhat pigmented, and is lined by a cylindrical epithelium, between the cells of which *olfactory cells* are found. Beneath the mucous membrane are large glands—*Bowman's glands.* (Merkel.)

* The regio olfactoria is, however, by most authors described as extending down to the middle of the middle turbinated bone.—TRANSLATOR.

Fig. 5*a*. **Section through the Olfactory Region of a Seven-Months Fœtus** (×150).—The arrangement of the epithelium is distinct, and exactly as in the adult. The duct of a mucous gland is also shown.

n, Nerve fibres passing to the epithelium.

Fig. 5*b*. **Supporting Cells and an Olfactory Cell from the same Specimen** (×350).—On the free surface of the supporting or *sustentacular cells* lie small granules which stain readily, and might be mistaken for cilia. Chromic acid, alcohol, acid carmine.

Fig. 6. **A Shred of Mucous Membrane from the Olfactory Region** (×300).—The specimen shows the cells in their natural relations. At the free margins of the cells there is an appearance of a row of granules, as in the last figure. A thin *cuticle* or membrane is also described as existing over the free surface of these cells. Osmic acid. (Merkel.)

Figs. 3, 4, and 6 after preparations of Brunn's.

Fig. 7. **Cross-section of a Circumvallate Papilla from an Adult** (×25).—The papilla, surrounded by the *trench*, into which *r*. *Ebner's glands* open, is seen with secondary papillæ on the surface, and *taste-buds* on each side of the trench (*cf.* Plate G 4, Figs. 3-3). Müller's fluid. (Merkel.)

Fig. 8. **A Taste-bud from the Last Preparation** (×500).—At the outer part of the taste-bud are numbers of flat, elongated supporting cells, which are also very distinctly seen in section in Fig. 9. These *sustentacular or supporting cells* are fusiform, and possess large nuclei; they extend down to the basement membrane. Between them lie taste or *gustatory cells*, *a*, which possess cilia-like processes, passing towards the middle of the taste-bud or *gustatory pore*. Müller's fluid. (Merkel.)

Fig. 9. **Cross section of Four Taste-buds** (×250).—The spaces in the epithelium in which the taste buds lie are seen to be distinctly marked off, and the nuclei of the supporting cells are well shown. Müller's fluid. (Merkel.)

Fig. 10. **Taste-organ of the Mole.**—Introduced for comparison.

A circumvallate papilla with a very pronounced network of nerve fibres [illegible]

The ramifications of the nerve fibres in the taste-buds on the right side of the [illegible] Golgi's method. (Kallius.)

Fig. 11. **Nerve Distribution in a Taste-bud and the Surrounding Epithelium** [illegible]

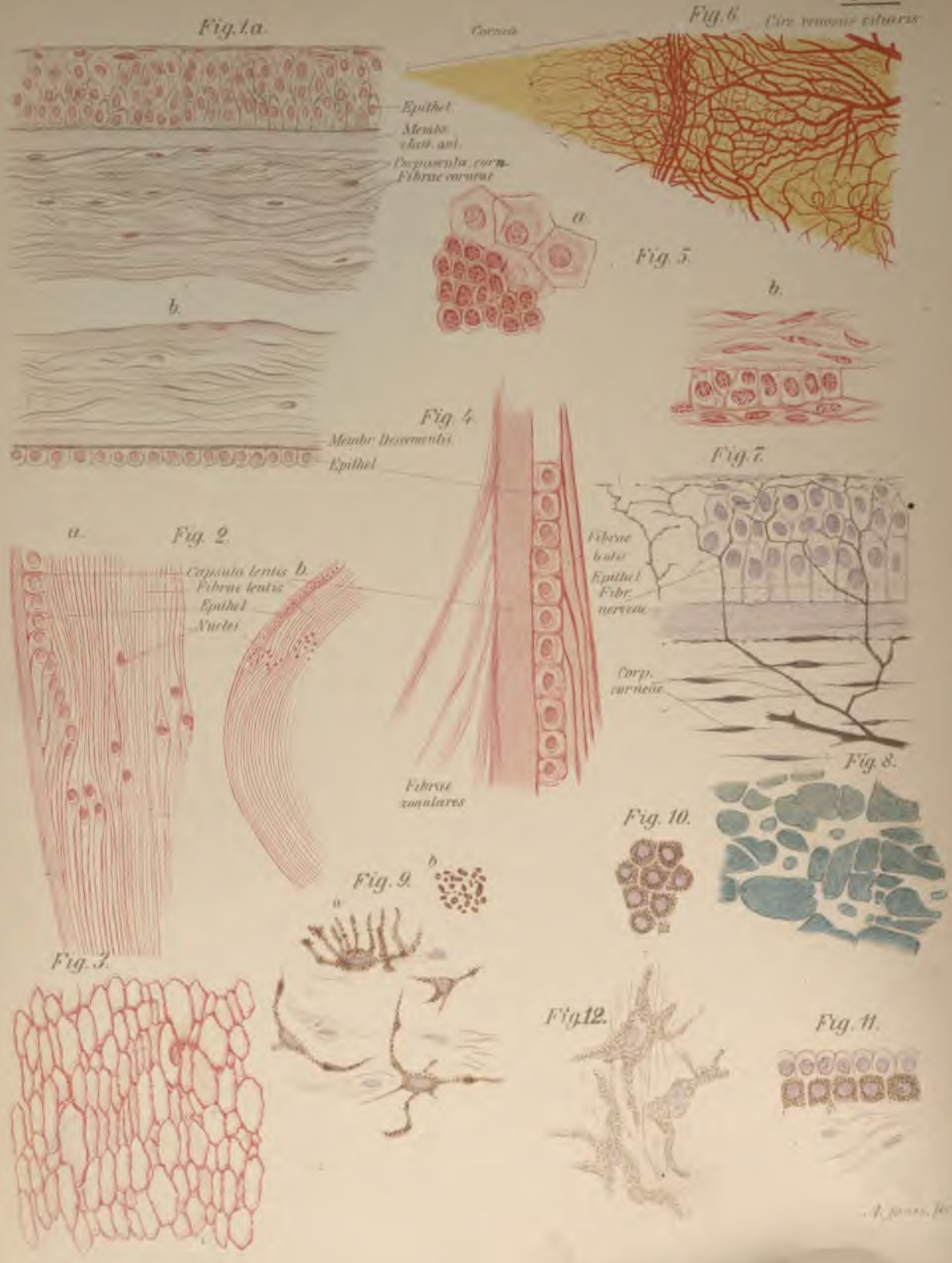
Fig. 1a.
Cornea
Epithel
Membr. elast. ant.
Corpuscula corn.
Fibrae curvae
b.
Fig. 6.
Cir. venosus ciliaris
a.
Fig. 5.
b.
Fig. 4.
Membr. Descemetii
Epithel
Fig. 7.
Fibrae laxae
Epithel
Fibr. nerveae
Corp. corneae
a.
Fig. 2.
Capsula lentis
b.
Fibrae lentis
Epithel
Nuclei
Fibrae zonulares
Fig. 8.
Fig. 10.
Fig. 9.
b.
a.
Fig. 3.
Fig. 12.
Fig. 11.

C 2. SENSE ORGANS—THE EYE: CORNEA AND LENS.

FIG. 1*a*. **Section of the Outer Layers of the Cornea** (×150).—The anterior epithelium rests upon the anterior homogeneous lamina (*membrane of Bowman*); it consists of several layers, the more superficial being flat, the deeper more columnar.

Beneath this come many layers of connective tissue, the strands or bundles of which are seen in either transverse or longitudinal section, leaving spaces or lacunæ between them (*v. Recklinghausen's spaces*), in which the *corneal corpuscles* lie, and which also serve as lymph channels.

FIG. 1*b*. **Section of the Inner Layers of the Cornea** (×150).—It is bounded internally by the internal or elastic lamina (*the membrane of Descemet*), and the epithelium resting on it, a single layer of lower, flattened cells derived from the epithelium of the anterior chamber. Müller's fluid, carmine. (Schmidt-Rimpler.)

FIG. 2. **The Structure of the Lens**—(*a*) **The Lens Capsule and the Border Zone of the Epithelial Layer (Lens Epithelium) applied to it** (×300).—The cells increase in length by degrees, and form the *lens fibres*, each possessing a spindle-shaped enlargement around the nucleus.

With the development of these fibres the nuclei become pressed towards the centre of the lens. The lens fibres are thus transformed epithelial cells.

FIG. 2*b*. **The Edge less highly magnified (75).**—The lens capsule, epithelium and fibres are shown. The latter can be followed in their curved course for a longer distance. Carmine. (Schmidt-Rimpler.)

FIG. 3. **Cross-section of the Lens Fibres from a New-born Child** (× 350.) — The broader fibres are those which are cut across in the neighbourhood of the nucleus. One of the latter is visible in the preparation. The lens fibres have finely-serrated edges. Chromic acid, alcohol.

FIG. 4. **Capsule of the Lens, with the Fibres of the Zonule passing to it** (×375).—On the right are the epithelial cells (*lens epithelium*), with the ends of lens fibres resting on them. Carmine. (Schmidt-Rimpler.)

FIG. 5. **Epithelium of the Anterior Surface of the Cornea from a Seven-Months Fœtus** (×400)—(*a*) **Seen from the Surface.**—Above, the flat cells which form the external layer are seen; below, the smaller, more columnar cells, which form the deepest layer and rest on Bowman's membrane.

FIG. 5*b*. **Cross-section** (inverted in relation to Fig. 1*a*).—In the lowest part are the flattened cells, which lie externally, and appear spindle-shaped in section; lying

just above these, the deeper, more cylindrical epithelial cells; above this, again, the connective-tissue basis of the cornea, with the spindle-shaped corneal corpuscles. Chromic acid, acid carmine.

FIG. 6. **Arrangement of Bloodvessels at the Limbus Conjunctivæ-Corneæ** (×8).—Only the outer part of the cornea is represented. The vessels are seen to enter the edge of the cornea and form loops. From these vessels the cornea is supplied with lymph through the medium of its cell spaces (v. Recklinghausen's canals). Preparation by Thiersch. (Merkel.)

FIG. 7. **Nerve Distribution in the Epithelial Layer of the Cornea** (×300).—Beneath the anterior homogeneous lamina, the nerves lose their medulla and form a plexus—*the subepithelial plexus*—from the branches of which fine non-medullated fibres penetrate between the epithelial cells to form a plexus (*intra-epithelial*), and in part end free. Gold chloride.

FIG. 8. **Corneal Connective Tissue, stained Blue** (×250).—The unstained areas are the lymph spaces, with the corneal corpuscles lying in them.

FIGS. 9-11. **Pigment Cells from the Choroid** (×400).

FIG. 9*a*. **Pigment Cells**, with long pigmented processes and a central nucleus.

FIG. 9*b*. **Pigment Granules**, more highly magnified.

FIG. 10. **Epithelial Cells from a Ciliary Process (surface view)**.

FIG. 11. **Lateral View of Cells from the same Situation.**—The pigmented cells lie externally; they are the continuation of the retinal pigment cells. The clear, non-pigmented cells lie internally, and are the continuation of the layers of the retina, which become modified at the *ora serrata*.

FIG. 12. **Cells from the Lamina Fusca of the Sclerotic** (×400).—These pigment cells lie in the looser connective tissue of the inner side of the sclerotic.

C 3. THE EYE—CHOROID, IRIS, CILIARY PROCESSES.

FIG. 1. **Iris from a Dark-coloured Eye** (×60).—The pigment cells lie in the deeper layers, especially round about the fibres of the *sphincter pupillæ* muscle, which, being arranged circularly, are seen in cross-section.

The thick layer of pigment on the posterior surface of the iris is the *uvea*, and is continuous with the pigment epithelium of the *pars ciliaris retinæ*. Hæmatoxylin, eosin. (Schmidt-Rimpler.)

FIG. 2. **A Portion of the same more highly magnified (150).**—The outlines of the pigment cells are more distinctly seen, and also the muscle fibres in transverse section, lying in the connective tissue forming the basis of the iris. Hæmatoxylin, eosin. (Schmidt-Rimpler.)

FIG. 3. **Cross-section of the Ciliary Process and the Parts adjacent to it** (×50).—The corneo-sclerotic junction with the *canal of Schlemm*, the *ligamentum pectinatum iridis* arising near it, and the iris in front. The ciliary muscle is separated from the sclerotic by a layer of pigment continuous with the *lamina fusca*; its fibres pass backwards to be inserted into the choroid.

Some of the fibres are seen in transverse section near the beginning of the iris, and constitute the *circular ciliary muscle* of Müller. The fibres of the *zonule of Zinn* are shown in their relation to the lens and to the ciliary body. Carmine. (Schmidt-Rimpler.)

FIG. 4. **Section of the Choroid** (×120).—The most external layer is the *lamina suprachoroidea*, which contains layers of large pigment cells, and is in relation with the lamina fusca of the sclerotic, from which it is separated in part by a small lymph space. The vascular layer contains fewer pigment cells, but numbers of large vessels (violet in the figure). Internal to this is the *chorio-capillaris*, or capillary layer of the choroid, covered by a thin membrane, *the membrane of Bruch* (*lamina basalis*). Hæmatoxylin, eosin. (Schmidt-Rimpler.)

FIG. 5. **Entrance of a Vena Vorticosa** (×20).—These vessels perforate the sclerotic obliquely to reach the choroid.

The vessel itself and the large vessels in the choroid are thickly enveloped by pigment. Carmine. (Schmidt-Rimpler.)

FIG. 6. **Horizontal Section through the Anterior Part of the Eye (diagrammatic)** (×7).—The lens is strongly arched, as is the case in young individuals.

The various structures are indicated in the diagram.

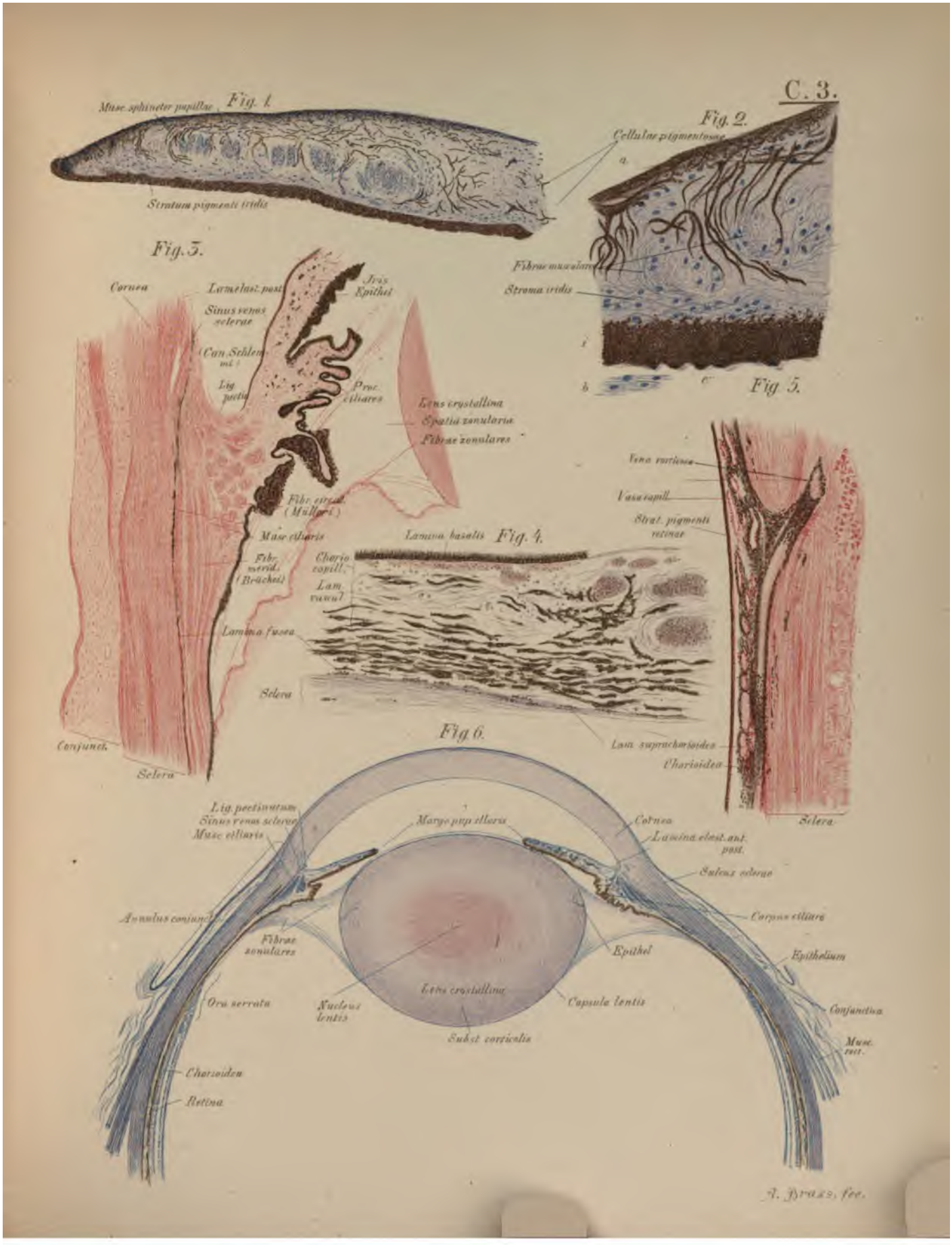
C. 3.
Fig. 1.
Musc. sphincter pupillae
Stratum pigmenti iridis
Fig. 2.
Cellulae pigmentosae
a
Fibrae musculares
Stroma iridis
i
b
c
Fig. 5.
Fig. 3.
Cornea
Lam. elast. post.
Sinus venos sclerae
(Can. Schlemmi)
Lig. pectin.
Iris
Epithel
Proc. ciliares
Lens crystallina
Spatia zonularia
Fibrae zonulares
Fibr. circul. (Müllori)
Musc. ciliaris
Fibr. merid. (Brücheii)
Lamina fusca
Conjunct.
Sclera
Lamina basalis
Fig. 4.
Chorio capill.
Lam. vascul.
Sclera
Vena vorticosa
Vasa capill.
Strat. pigmenti retinae
Lam. suprachorioidea
Chorioidea
Sclera
Fig. 6.
Lig. pectinatum
Sinus venos sclerae
Musc. ciliaris
Margo pupillaris
Cornea
Lamina elast. ant. post.
Sulcus sclerae
Annulus conjunct.
Fibrae zonulares
Corpus ciliare
Epithel
Epithelium
Ora serrata
Nucleus lentis
Lens crystallina
Capsula lentis
Subst. corticalis
Conjunctiva
Musc. rect.
Chorioidea
Retina
A. Braxs, fec.

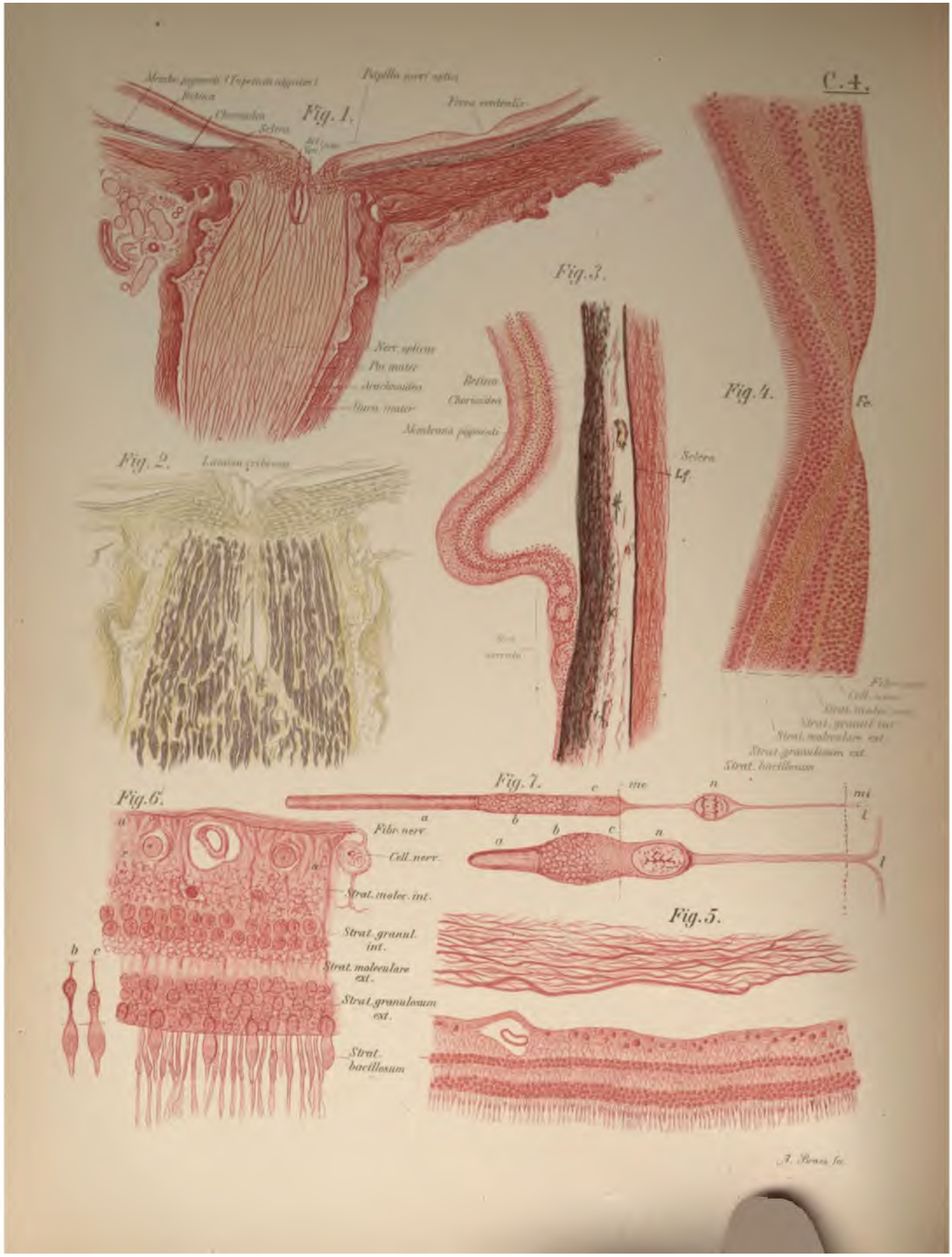
Fig. 1.
Sclera
Nerv. opticus
Pia mater
Arachnoidea
Dura mater
Fig. 2.
Fig. 3.
Retina
Chorioidea
Membrana pigmenti
Sclera
Lf.
Fig. 4.
Fe.
Fig. 6.
Fibr. nerv.
Cell. nerv.
Strat. molec. int.
Strat. granul. int.
Strat. molecular ext.
Strat. granulosum ext.
Strat. bacillosum
Fig. 7.
Fig. 5.
J. Brass fc.

C 4. THE EYE—OPTIC NERVE, RETINA.

FIG. 1. **Section through the Entrance of the Optic Nerve** (×10).—The *arteria centralis retinæ* and its accompanying vein are shown in section in the upper part. The optic nerve is shown in longitudinal section, and perforates the sclerotic at the *lamina cribrosa;* connective-tissue septa are seen dividing the nerve into bundles.

On the left-hand side of the section the retina, choroid, and sclerotic are shown separated from one another.

On the right the fovea centralis is shown, and the thickening of the choroid in this situation. Carmine. (Schmidt-Rimpler.)

FIG. 2.—**Optic Nerve stained by Weigert's Method** (×16).—This specimen shows the change from medullated to non-medullated fibres, the optic nerve fibres losing their medulla just before passing through the lamina cribrosa. (Schmidt-Rimpler.)

FIG. 3. **Region of the Ora Serrata** (×50).—The retina has separated from the choroid, and the latter also from the sclerotic.

At the *ora serrata* the nervous structures of the retina stop abruptly, and the retina is continued forward as the *pars ciliaris retinæ*, which consists simply of two layers of epithelium (*cf.* Plate C 2, Fig. 11); and here there exists a more close union between the retinal layer and the choroid, because the last fibres of the zonule of Zinn take origin in this situation.

L.f. the lamina fusca attached to the sclerotic. Carmine. (Schmidt-Rimpler.)

FIG. 4. **Section through the Fovea Centralis** (×70).—The external and internal limiting membranes are both curved, so that the retina in this situation is thinnest, though it is at its thickest in the surrounding part, the *macula lutea.*

At the *fovea centralis* there are no rods, and the cones are much elongated; the other layers of the retina are much thinner, and almost disappear, except that beneath the cone-layer the external nuclear layer is well marked; its nuclei belong to the cone fibres.

The molecular layers of the retina are stained orange. Picrocarmine. (Schmidt-Rimpler.)

FIG. 5. **Cross-section of the Retina, after a Preparation by H. Virchow** (×75).—The nerve cells are distinctly seen in the ganglionic layer. Carmine. (Sobotta.)

FIG. 6. **Part of the Last Preparation more highly magnified (225).**—In the upper part a few fibres of the nerve-fibre layer are represented; on the right a nerve cell of the ganglionic layer is isolated; in the middle lies a bloodvessel, which has retracted, and therefore appears in a clear space. The other layers are indicated in the figure.

a, A supporting fibre, or *fibre of Müller*.

b, An isolated *cone element*, the nucleus of which lies in the outer nuclear layer.

c, An isolated *cone element*, its nucleus being situated more deeply in the outer nuclear layer.

Between the nucleus and the outer part of the cone element is a constriction. All the cone cells show a darkly stained area around the nucleus. Carmine. (Sobotta.)

FIG. 7. **A Rod and Cone from the Last Preparation isolated (×1000),** compared with the same elements in the fresh retina, and slightly schematized.—The dotted lines, *me* and *mi*, indicate the borders of the outer and inner nuclear layers respectively.

The upper one is a *rod element*, and consists of the rod itself and the rod fibre with its nucleus; the rod fibre ends in a knob-like thickening within the outer molecular or inner nuclear layer.

The lower figure is a *cone element*, and consists of similar parts, except that the cone fibre divides into branches.

a, The outer segment, cylindrical in the case of the rod, conical in the cone.

b, Zone of granular protoplasm, joining on to the outer segment.

c, Zone of very fine granules; this becomes constricted at the external limiting membrane, and the rod fibre or cone fibre is given off into the outer nuclear layer.

The rod fibre is quite thin, and has its nucleus deeper in the outer nuclear layer; the nucleus itself has its chromatin in most cases in two distinct transverse discs.

The cone fibre is thicker; the nucleus is generally near the external limiting membrane, and its chromatin is less regularly arranged than in the nucleus of the rod fibre. Carmine. (Sobotta.)

C 5. THE EYE—RETINA (continued).

FIG. 1. **Diagram or Scheme of the Retina, after Kallius.**—The retina, like the cerebellum, presents an extremely complicated structure, and still further researches are needed to elucidate many of its details. The varicose optic nerve fibres (non-medullated) proceed to the large ganglion cells, *r*, *s*, *t*, *u*, *v*, *w*, and form the axis cylinder processes or neurites of those cells (*chief processes of Kallius*).

The dendritic processes of these cells, which have no less important functions, ramify in the manner represented, their branches lying between those of the so-called *parareticular* cells, *l*, *m*, *n*, *o*, *p*, *q*, which are shown in violet. Moreover, in the same zone also are the ramifications of the axis cylinder processes (chief processes) of the *bipolar cells*, *c*, *d*, *e*, *f*, *g*, *h*. Between these are large *horizontal cells*, *i*, *k*, whose dendritic processes ramify for the most part like those of the bipolar cells, in that zone, which contains also the knob-like swellings and ramifications of the rod and cone fibres, which are represented as described in the last plate.

a, Rod elements.
b, Cone elements.
x, Müller's supporting fibre, showing spaces for the cells of the nuclear layers, and in the rod and cone fibre layer is the basket-like network. It possesses a nucleus of its own in its centre.
z, Pigment cells of the retina.

Layers of the retina, after Kallius:

I. Pigment layer.
II. Layer of rods and cones.
III. Membrana limitans externa.
IV. Granular or nuclear layer.
V. Outer reticular layer.
VI. Outer ganglionic layer.
VII. Inner reticular layer.
VIII. Inner ganglionic layer.
IX. Optic nerve fibre layer.

FIG. 2. **Inner Ganglionic Cell** (*i.e.*, **from the VIII. layer of Kallius) from the Retina of the Ox** (×**120**).—The chief process is coiled on itself at *a*. Golgi's method. (Kallius.)

FIG. 3. **Parareticular Cells from the Retina of the Ox** (×**120**).—Golgi's method. (Kallius.)

FIG. 4. **Bipolar Cells, Lateral and Surface View** (×**200**). — Golgi's method. (Kallius.)

FIG. 5. **Section of the Retina of the Ox** (×**100**).—On the left-hand side four *parareticular cells* are shown, on the right five *bipolar cells*. Golgi's method. (Kallius.)

Fig. 1.

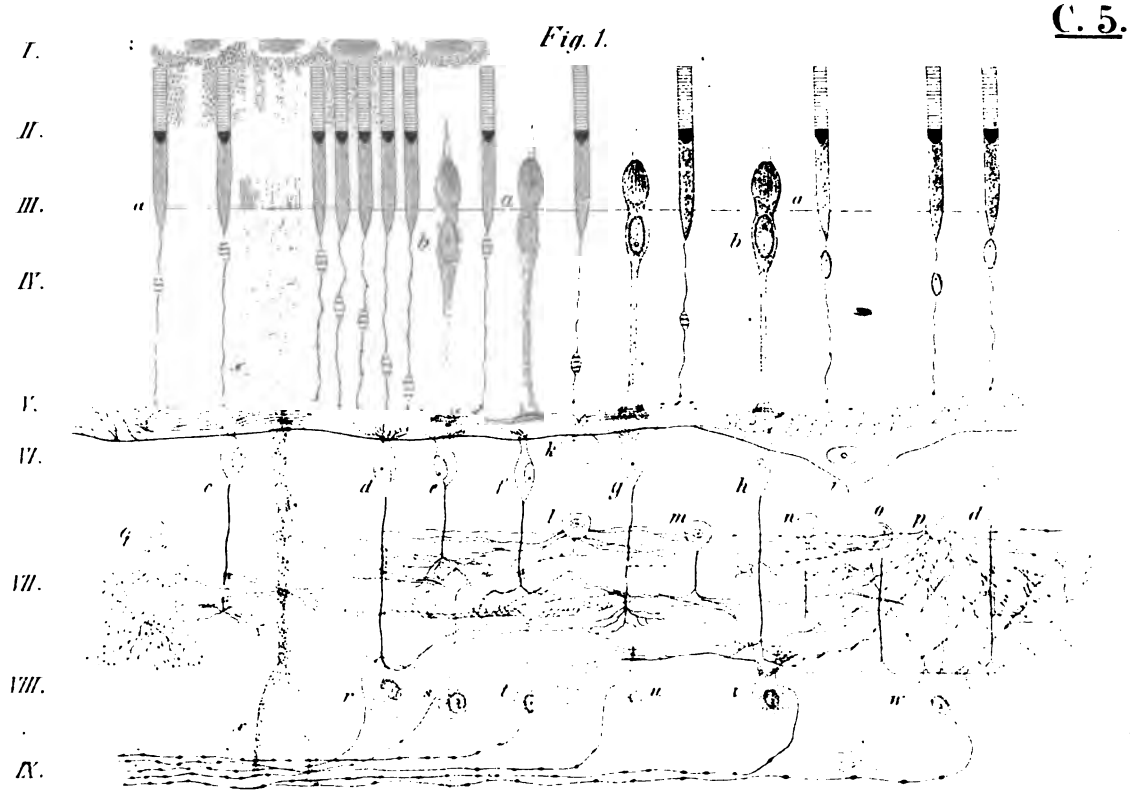

Fig. 2.

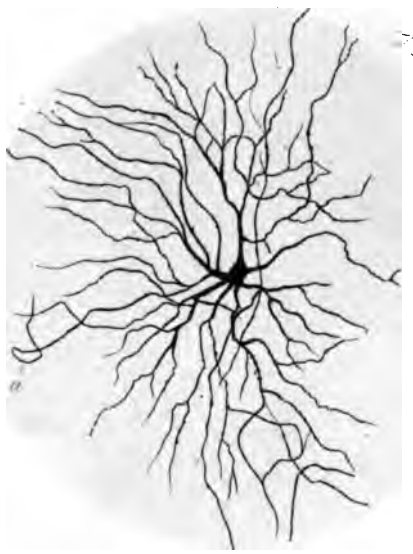

Fig. 3.

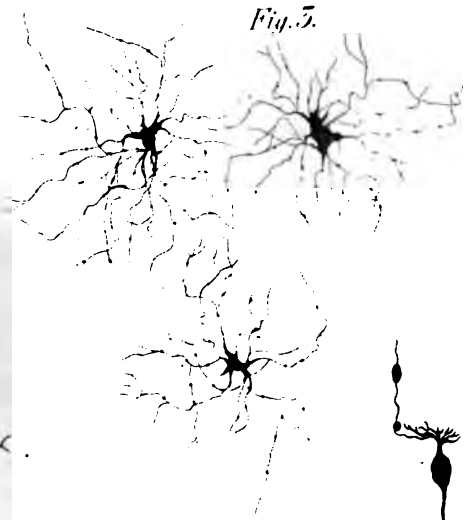

Fig. 4.

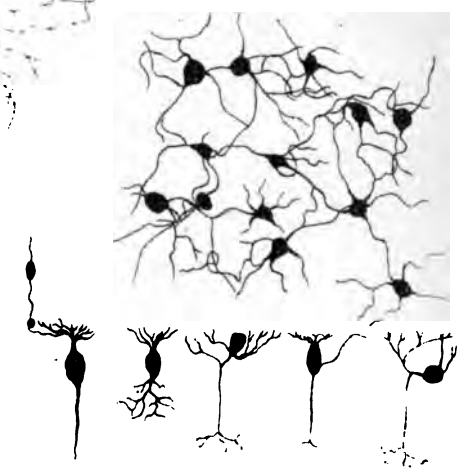

Fig. 5.

C. 6.

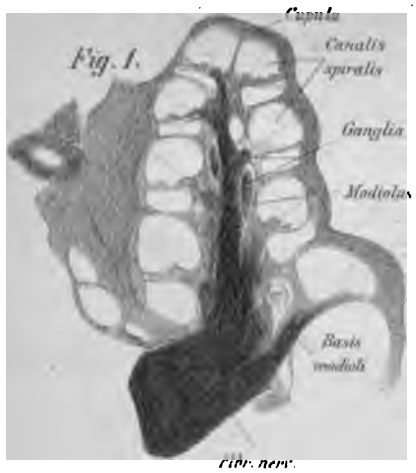
Fig. 1.
Canalis spiralis
Ganglia
Modiolus
Basis vestibuli
Fibr. nerv.

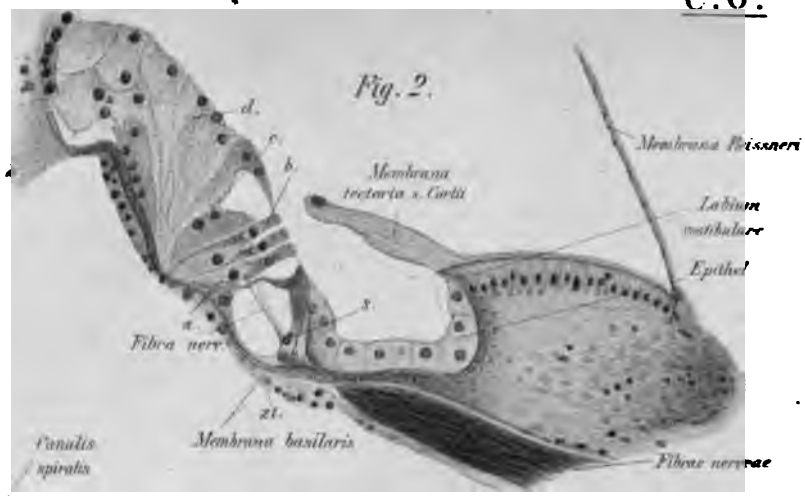
Fig. 2.
Membrana Reissneri
Membrana tectoria s. Cortii
Labium vestibulare
Epithel
Fibra nerv.
Canalis spiralis
Membrana basilaris
Fibrae nerveae

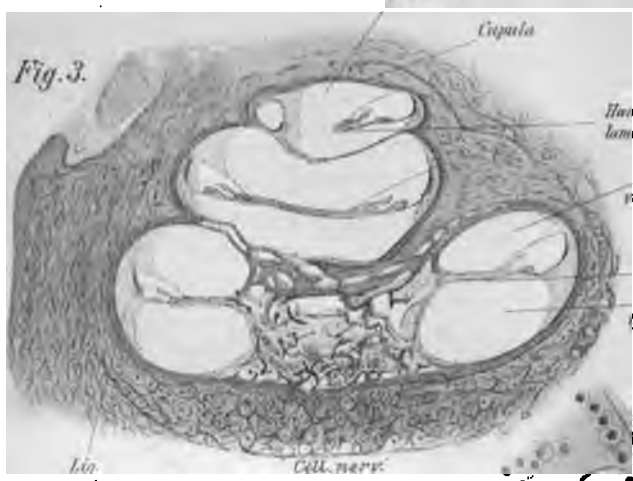
Fig. 3.
Cupula
Hamulus lamin. spir.
Scala vestibuli
Lamina spiralis ess.
Scala tympani
Lig. spirale
Cell. nerv.

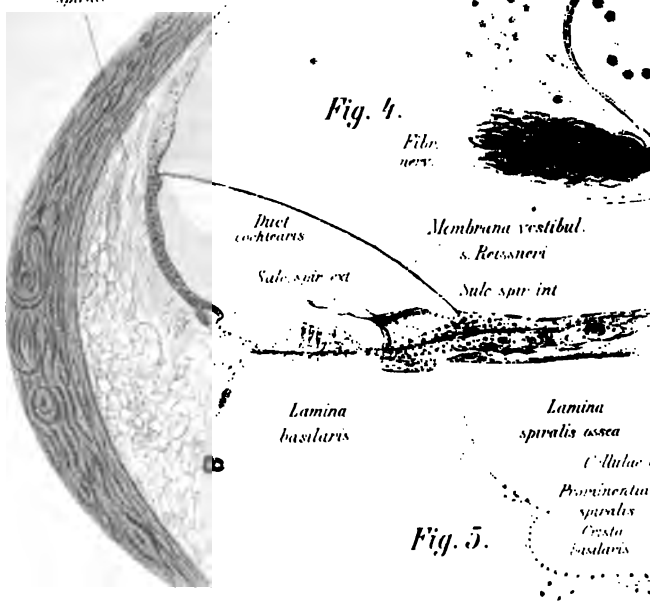
Fig. 4.
Fibr. nerv.
Ductus cochlearis
Membrana vestibul. s. Reissneri
Sulc. spir. ext
Sulc. spir. int
Lamina basilaris

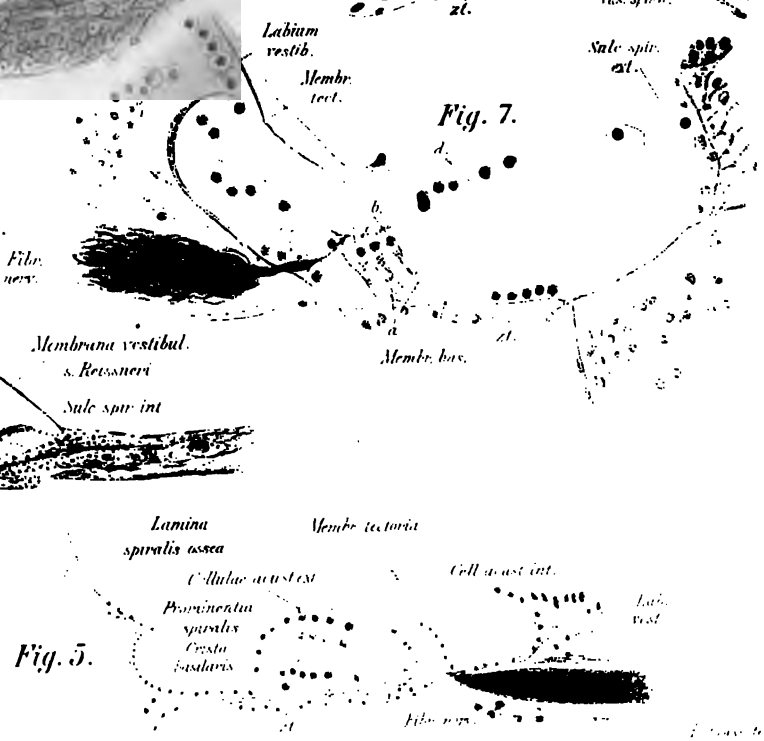
Fig. 5.
Lamina spiralis ossea
Membr. tectoria
Cellulae acust. ext.
Cell. acust. int.
Prominentia spiralis
Crista basilaris

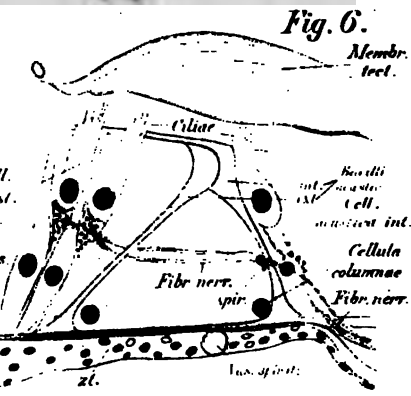
Fig. 6.
Membr. tect.
Cellulae
Cell. acust. ext.
Cell. acust. int.
Cellula columnae
Fibr. nerv. spir.
Fibr. nerv.
M. b.
zt.
Vas. spiral.

Fig. 7.
Labium vestib.
Membr. tect.
Sulc. spir. ext.
Fibr. nerv.
Membr. bas.
zt.

C 6. THE EAR—COCHLEA AND ORGAN OF CORTI.

FIG. 1. **Cross-section of the Cochlea of the Porpoise** (×12).—The darkly-stained nerve fibres of the *cochlear division* of the auditory nerve lie in the centre, and to the right and left of it the *canal of the cochlea* is cut across eight times as it winds round the modiolus. Osmic acid, hæmatoxylin, eosin. (Sobotta.)

FIG. 2. **Part of the Canalis Cochleæ from the same Preparation** (×240).—The basilar membrane and organ of Corti are shown, and part of the membrane of Reissner. The basilar membrane extends from the lamina spiralis to the side of the cochlea, and the following structures rest upon it:

The organ of Corti.

a, *Cells of Deiters*, or supporting cells, between the bases of the outer hair cells.

b, The auditory or *hair cells*.

c, *Hensen's supporting cells*.

d, *Cells of Claudius*, filling up the space near the outer wall of the canalis cochleæ.

A layer of nerve fibres is seen passing under the lamina spiralis.

s, Section of a nerve fibre running in a spiral course; nerve fibres are seen crossing the *tunnel of Corti* to reach the outer hair cells.

zt, The lining membrane of the scala tympani.

The membrana tectoria, or *membrane of Corti*, extends from the lamina spiralis over the organ of Corti. Osmic acid, hæmatoxylin, eosin. (Sobotta.)

FIG. 3. **Section of the Human Cochlea** (×8).—The section was made to one side of the *modiolus*, so that the upper windings are cut through longitudinally, and not separated on the two sides as in the case of the lower coil, which is cut twice in transverse section.

The *lamina spiralis ossea* is cut across radially in the lower section, and, with the membrana basilaris, is seen to divide the bony cochlea into two, the lower half being the *scala tympani*.

The upper half is again divided by the *membrane of Reissner*, which separates the membranous *canalis cochleæ* from the *scala vestibuli* above.

In the middle coil the section has caught the lamina spiralis ossea tangentially. (Merkel.)

Fig. 4. **Canalis Cochleæ from the Last Figure isolated and more highly magnified (40).**—The portion represented is the lowest section on the left-hand side.

The general arrangement is as described in Fig. 2; the *organ of Corti* is seen resting on the *basilar membrane;* the latter is connected to the external wall of the bony cochlea by the *ligamentum spirale*, composed of connective tissue, while at its internal end it is fixed to the lamina spiralis ossea. The roof of the canal is formed by Reissner's membrane. (Merkel.)

Fig. 5. **Diagram of the Organ of Corti constructed from Figs. 3 and 4 (×100).**—The tunnel of Corti is shown, with one hair cell on its inner side and a series on the outer side. The *membrana tectoria* is not in direct apposition to the hair cells, as it is said to be in the normal condition.

Fig. 6. **The Tunnel of Corti of the Last Figure more highly magnified.**—The inner rod is seen to be in shape something like a human ulna, and is prolonged into a thin membrane—the *membrana reticularis;* the outer rod is in shape like a swan's head and neck; together they form a triangular tunnel-shaped space—the *tunnel of Corti.*

At the bottom of the rods, resting upon the basilar membrane within the tunnel of Corti, are two cells, from which the rods have been formed.

The nerve fibres pass obliquely across the tunnel, and probably form ramifications around the outer hair cells (*auditory cells*).

Deiter's cells, not represented in this figure, rest on the basilar membrane and support the hair cells (*cf.* Plate C 7, Fig. 7).

The membrana tectoria presents a striated appearance, and on its under surface are spiral grooves; at its free border is a small enlargement, in which in all the specimens I have examined I find a highly refractive spiral fibre. I note this in order to direct further observation to it.

Fig. 7. **Cross-section of the Basilar Membrane and Corti's Organ in the Rat (×135).**—The entrance of the nerve fibres and their passage to Corti's organ is distinct; the references are as in Fig. 2. (Merkel.)

C.7.

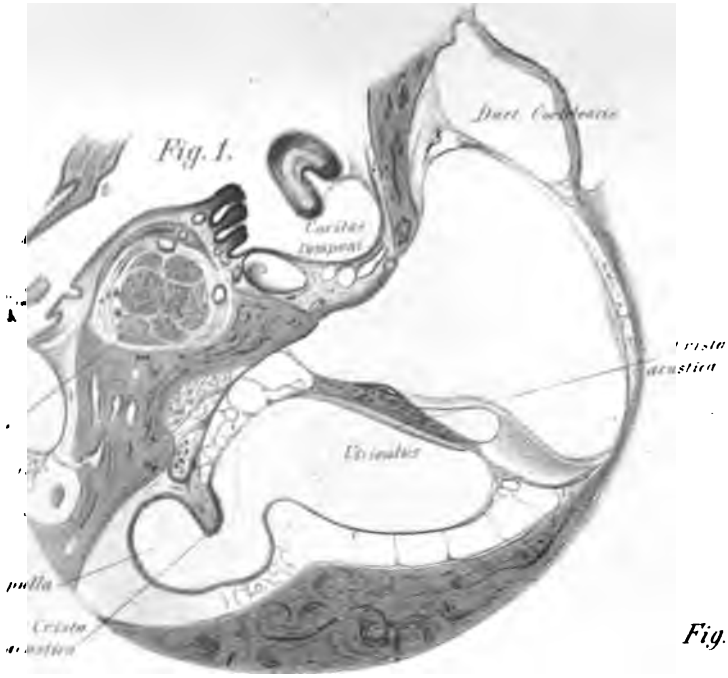



Fig. 5.

Fig. 4.

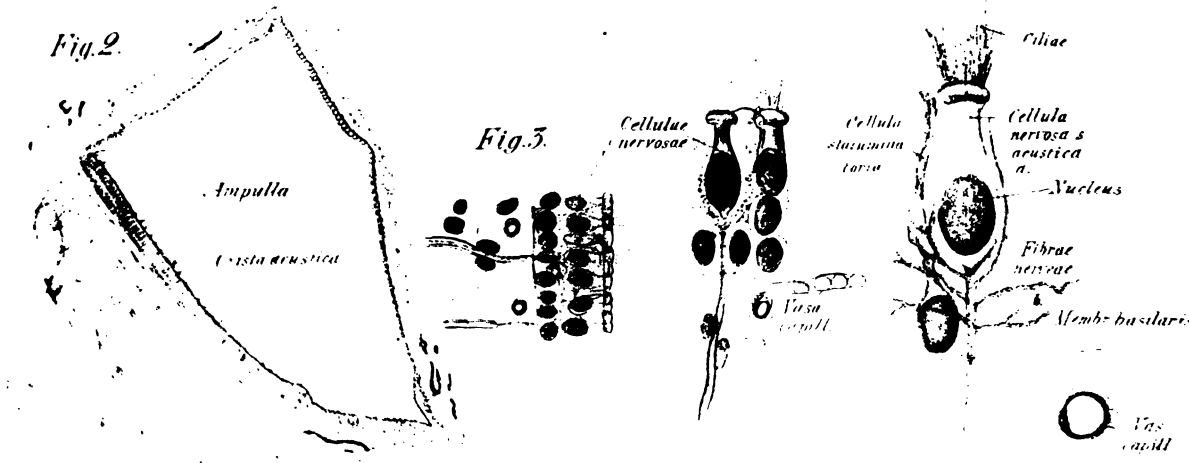

Fig. 6.

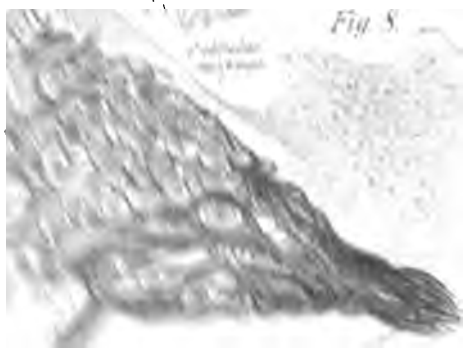

Fig. 8.

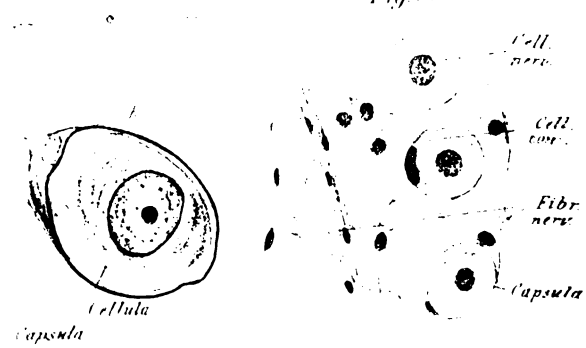

C 7. THE EAR—SEMICIRCULAR CANALS; AMPULLÆ. AUDITORY CELLS.

FIG. 1. **Section through the Membranous Labyrinth** (×15).—The *utricle* (with its *macula*), the *ampulla* of one of the semicircular canals (with its projecting *crista acustica*) opening into it, and the *canal of the cochlea* on its way to open into the *saccule*, are shown. Above is the cavity of the *tympanum*, and just below it the auditory nerve in transverse section. (Merkel.)

FIG. 2. **Section through an Ampulla from the Sheep** (×57).—On the left is the *crista acustica*, with the thick connective tissue beneath it in which the nerve fibres with their double contour are seen; they lose their medulla a short distance before passing to the hair cells.

a, Epithelium without hair cells. Osmic acid. (Merkel.)

FIGS. 3, 4, 5. **Neuro-epithelial Structures of the Ampullæ.**

FIG. 3. **Epithelium of the Crista in Position** (×230).—From the left two nerve fibres pass to it, having just lost their medullary sheath. The cilia, or hairs of the hair cells, project through a distinct *cuticle*, or membrane.

FIG. 4. **Two Hair Cells** (×450), with the tuft-like auditory hairs, and the supporting cells lying beneath them. These supporting cells—the *fibre cells of Retzius*—are nucleated, rest on the basement membrane, and extend to the cuticle.

FIG. 5. **Hair Cell and Fibre Cell somewhat diagrammatically represented.** — The auditory hairs, or cilia, lie in the gelatinous *otolith membrane*, in which small calcareous particles—*the otoliths*—are embedded. The latter are small crystalline bodies, consisting chiefly of calcium carbonate.

The nucleus of the auditory or hair cell is oval (round in man); the cell itself is pear-shaped. On the end bearing the cilia is a thicker part or border, which comes into contact with a similar process from the supporting or fibre cell.

The supporting cell is represented red; its nucleus lies near the basement membrane. The nerve fibres, shown in violet, are derived from the axis cylinder of a nerve fibre which has just lost its medullary sheath; these nerve fibrils ramify around the hair cells and give off processes both around them and directly to them.

FIG. 6. **The Epithelium from the Part marked *a* in Fig. 2** (×250).—The cells gradually diminish in height till they become quite flat, these flat cells lining the rest of the canal. Osmic acid. (Merkel.)

FIG. 7. **Auditory or Hair Cells.**—*a*, Auditory cell from the utricle, with a rounded nucleus; the thickened border described above is seen, and the hairs are arranged in a cone. A nerve fibre spreads out beneath the lower part of the cell to form a broad expansion, while another fibre is applied to the side of the cell.

b, Auditory cell from the organ of Corti, resting on what is by some histologists regarded as a bifurcated cell.

c, Auditory or hair cell from the organ of Corti; a nerve fibre is seen to pass directly to the cell; lying beside it are two supporting cells, over which nerve fibres (stained darkly) are seen to pass.

d, An auditory cell from the organ of Corti, after Hensen and Retzius.

I., The cuticularized end process, which joins the end process of the Deiters' cell, *e*.

II., The striated corpuscle of Hensen.

III., Lower granular part of the cell protoplasm.

e, Deiters' supporting cell, with a central spiral fibre.

I., End process.

FIG. 8. **Nerve Cells from the Spiral Ganglion of the Rat** (×**200**).—The nerve fibres enter the ganglion from below; on the right they pass off from the ganglion to the organ of Corti. The *spiral ganglion* is situated at the base of the lamina spiralis ossea. Osmic acid. (Merkel.)

FIG. 9. **Nerve Cells from the Human Spiral Ganglion** (×**600**).—The cells are enclosed by connective-tissue capsules; a few nerve fibres, a capillary vessel, and a number of stellate connective-tissue cells, are also shown.

a, A nerve cell, bipolar, without a capsule.

b, A nerve cell from the rat with a capsule (×1500). Osmic acid. (Merkel.)

D.—THE NERVOUS SYSTEM.

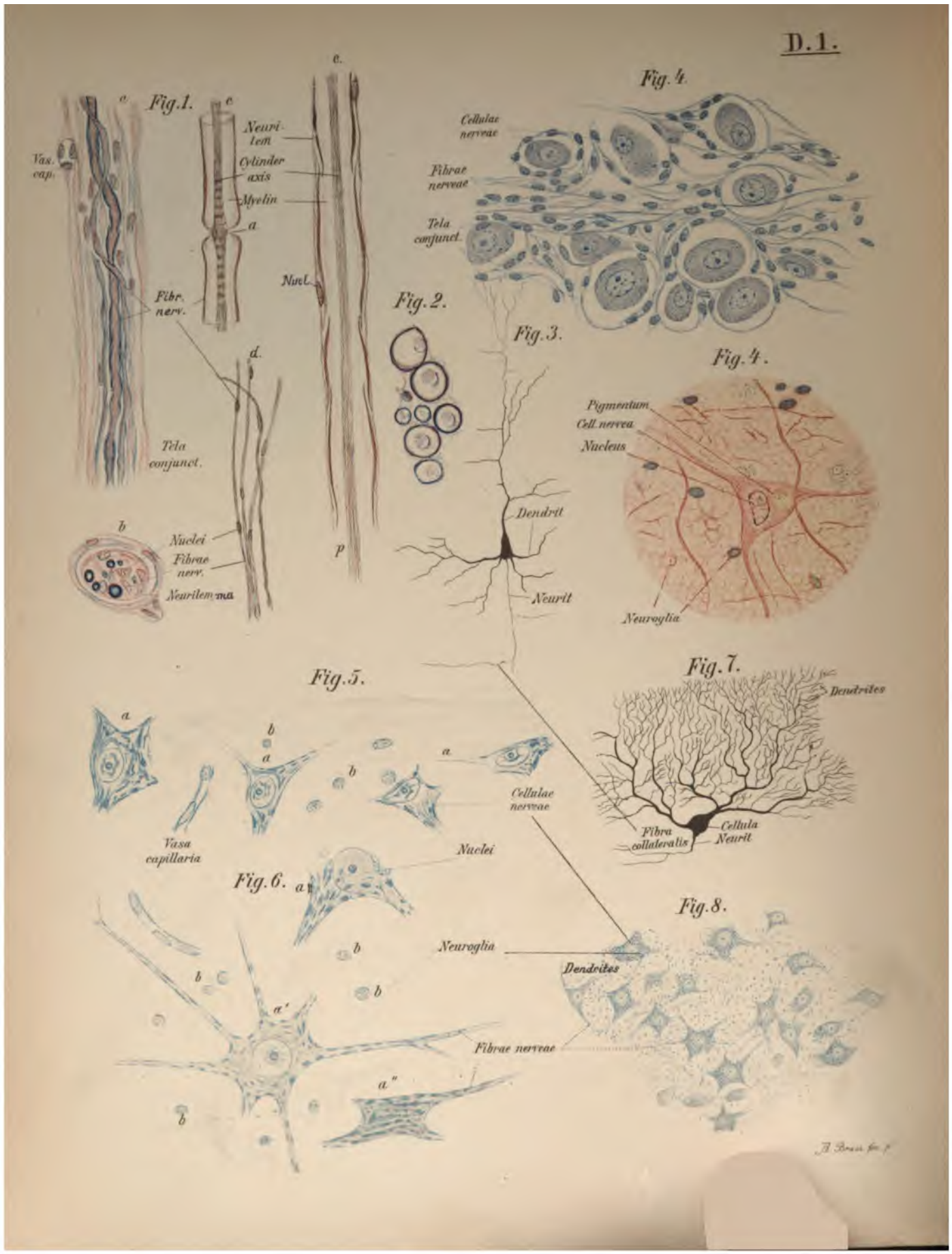
Fig. 1.
c
Vas. cap.
Fibr. nerv.
Tela conjunct.
b
Nuclei
Fibrae nerv.
Neurilemma
d.
c.
Neurilem
Cylinder axis
Myelin
a
Nucl.
p
Fig. 2.
Fig. 3.
Dendrit
Neurit
Fig. 4.
Cellulae nerveae
Fibrae nerveae
Tela conjunct.
Fig. 4.
Pigmentum
Cell. nervea
Nucleus
Neuroglia
Fig. 5.
a
b
Vasa capillaria
Cellulae nerveae
Nuclei
Fig. 6.
a'
a''
Fig. 7.
Dendrites
Fibra collaeralis
Cellula Neurit
Fig. 8.
Neuroglia
Dendrites
Fibrae nerveae

D 1. THE NERVOUS SYSTEM—NERVE CELLS AND NERVE FIBRES.

FIG. 1. **Nerve Fibres after Treatment with Various Reagents.**

(*a*) **A Small Nerve Bundle of Three Fibres in Longitudinal View** (×**350**).—The constituent fibres are indented at the sides, but not in any regular manner (*cf. e*). These indentations, or varicosities, are peculiarities of the white sheath (myelin), which appears bluish-black after treatment with osmic acid. This *white or medullary sheath* encloses the *axis cylinder*, which is here stained red.

Each fibre is surrounded by a spinal nucleated sheath (*the nucleated sheath of Schwann*), which also accompanies it after it leaves the nerve bundle, and is commonly known as the *neurilemma*.

The medullary or white sheath is applied to each fibre a short distance from the nerve cell from which it is derived, and extends to within a short distance from its ending on a muscle fibre, or in a sensory end-organ; it consists of a fatty material, myelin, and presents at intervals interruptions, first described by Schwann, but shown to be constant by Ranvier, and hence known as *nodes of Ranvier*.

At these nodes the neurilemma and axis cylinder are in contact, so that reagents can more readily reach the latter, whose structure is in these situations more easily studied.

The fibres of a nerve bundle are collectively enclosed by a connective-tissue sheath outside the neurilemma, called *Henle's sheath*, which is also prolonged over the individual fibres. Its free surface possesses an epithelial investment.

In the brain and spinal cord we find, in place of the neurilemma, the nerve cement, or *neuroglia* (*cf.* Plate D 14).

(*b*) **Cross-section of a Similar Small Nerve Bundle** (×**350**).—The medullary sheath surrounds each axis cylinder as a distinct dark ring; the whole bundle is surrounded by Henle's sheath.

(*c*) **Part of a Nerve Fibre with a Node of Ranvier** (×**600**).—Owing to the action of reagents, the medullary sheath has separated from the axis cylinder, which is somewhat shrivelled; the neurilemma is seen externally as a delicate membrane. The axis cylinder has a fibrillated structure, and shows at the node at *a* a swelling, probably produced by the reagents used.

(*d*) **Non-medullated Fibres** (× 600), each with a sheath, the nuclei of which are very distinct.

(*e*) **A Medullated Nerve Fibre**, after the action of Müller's fluid and absolute alcohol and staining with carmine (× 600).

The axis cylinder, much shrunken, presents a longitudinal fibrillation (a special neurokeratin sheath to the axis cylinder, the *axilemma*, is described by Kühne). The medullary sheath is divided into *medullary segments* by *incisures of Lantermann*—by some observers regarded as normal, by others as artificial products (*cf.* Plates D 7 and D 13). In nerves examined in the fresh state they are not to be seen.

To briefly summarize the structure of a medullated nerve fibre:

1. The axis cylinder, consisting of longitudinal fibrillæ, enclosed in a neurokeratin sheath, the axilemma.
2. The white substance, or medullary sheath.
3. The nucleated sheath of Schwann, or neurilemma.
4. Henle's connective-tissue sheath.

The last two are not found in the white fibres of the central nervous system. (*a*), (*b*), Flemming's solution, acid carmine; (*c*), (*d*), (*e*), Müller's fluid, absolute alcohol, acid carmine.

Fig. 2. **Cross-section of Nerve Fibres from the Spinal Cord** (× 600).—Each fibre presents externally a ring of compact, deeply-stained white substance; within this a clear space, in which there is an appearance of delicate concentric rings, owing to light refraction.

The axis cylinders appear finely granular in cross-section, and have no distinctly marked border. Weigert-Pal method. (Sobotta.)

Fig. 3. **Nerve Cell from the Cerebral Cortex** (× 250).—A precipitate of reduced chromate of silver is deposited in the body of the cell and its processes. Golgi's method of staining.

From the upper part of the cell, and also from the angles at the base, pass off ramifying protoplasmic processes, or *dendrites*, the branches ending free and not anastomosing. From the base of the cell a single axis cylinder process leaves it; in its course it gives off lateral branches, the *collaterals* of Ramon-y-Cajal. The *axis cylinder processes*, unlike the dendrites, are often very long, even more than a metre in length, and they are more uniform in diameter than the dendrites.

Fig. 4. **Longitudinal Section of a Spinal Ganglion from a Seven-Months Fœtus**

(×**400**).—The nerve cells lie in connective-tissue capsules, as rounded cells apparently isolated. At first each developing cell, or neuroblast, possesses two distinct processes, but after a time they unite together for a little distance, and so a **T**-*shaped junction* is formed, the union always occurring as far as a node of Ranvier.

One of the smaller cells in the figure possesses a short process directed towards the right. A few nerve fibres are seen passing between the cells, but their structure is not yet well marked. Chromic acid, alcohol, hæmatoxylin.

Fig. 4*a*. **A Nerve Cell without a Capsule, from the Anterior Horn of the Spinal Cord** (×**400**).—The cell is multipolar, and three of its processes lie in the plane of the section. Within the cell itself is its nucleus and some yellowish pigment.

The violet bodies are the nuclei of the *neuroglia cells* supporting the nerve tissues. Hæmatoxylin, eosin. (Ziemke.)

Fig. 5.—**Cells from the Posterior Horn of the Lumbar Region of the Cord of a New-born Child** (×**400**).—*a*, Nerve cells. *b*, Neuroglia cells.

The nerve cells are smaller than those of the anterior horn, and they contain large masses of deeply-staining material, which is also continued a little way along the nerve-fibre processes. Whether these masses are artificial products is still a matter of dispute. Methylene blue, Nissl's method. (Sobotta.)

Fig. 6. **Nerve Cells from the Anterior Horn of the same Preparation** (×**400**).—The nerve cells are distinctly larger than those of the posterior horn.

a, A nerve cell of which only a part is shown:—its large round nucleus and two processes.

a′, A cell with six processes; its nucleus is spherical and contains a darkly-stained nucleolus.

a″, A cell of which only the surface is caught in the section; it presents a peculiar striated appearance, owing to the masses of deeply-staining material.

Fig. 7. **A Nerve Cell, or Purkinje's Cell, from the Cerebellar Cortex.**—It possesses large numbers of ramifying protoplasmic processes, or *dendrites*, which pass upwards and spread out widely; from the lower part a single axis cylinder process, with collaterals, is given off.

Fig. 8. **Cells from the Anterior Horn of the Spinal Cord** (×**125**).—It affords an example of cells with processes passing off on all sides, though less numerous than those in the last specimen. Methylene blue, Nissl's method. (Sobotta.)

D 2. SPINAL CORD—MEDULLA OBLONGATA.

Fig. 1. **Transverse Section of the Spinal Cord in the Thoracic Region from a Seven-Months Fœtus** (× 12).—The distinction between grey and white matter can be readily [illegible] and the large size of the grey relatively to the white matter in the fœtal [illegible] compared with the relations existing in the adult cord of the same region (Fig. 3).

The nerve cells are just distinguishable in the anterior horn of the grey matter as fine [illegible] Plate [illegible], Figs. 3 and 4.) Chromic acid, alcohol, hæmatoxylin.

Fig. 2. **Transverse Section of the Sacral Part of the Cord of an Adult** (× 7).—Note the large preponderance of grey matter, that the posterior horns are about the same size as the anterior, and that the grey commissure is very wide. Müller's fluid, picrocarmine. Freudenstein.

Fig. 3. **Transverse Section of the Thoracic Part of the Cord of an Adult** (× 7).—The small size of the grey matter and the prominence of the lateral horn are to be observed. Müller's fluid, picrocarmine. Freudenstein.

Fig. 4. **Transverse Section of the Cervical Part of the Cord of an Adult** (× 7).—The anterior horn is large, the posterior smaller, but has a large amount of the *substantia gelatinosa* of Rolando at its apex. Müller's fluid, picrocarmine. Freudenstein.)

Fig. 5. **Transverse Section of the Cervical Enlargement of the Spinal Cord.**—Müller's fluid, picrocarmine. (Freudenstein.)

Fig. 6. **Transverse Section of the Lower Part of the Medulla Oblongata** (× 7).—The section shows the upper limit of the decussation of the pyramids, and the commencement of the *sensory* or *suprapyramidal decussation*; the *external arcuate fibres* can also be seen winding round the outer part of the pyramids.

The method of staining has differentiated the collections of nerve cells (stained [illegible]) from the nerve fibres, which in section appear yellowish-brown.

The substantia gelatinosa of Rolando (*substantia grisea posterior*) is pushed later- [illegible] to the growth dorsalwards of the grey nuclei of the *funiculus gracilis* and [illegible]

[illegible] to the substantia gelatinosa is the *ascending root of the fifth nerve*.

[illegible] canal is about in the middle of the section, and in the grey matter [illegible] the *nucleus of origin of the hypoglossal nerve* is to be seen.

[illegible] matter, and extending widely into the lateral columns, is the [illegible] formed by the intersection of the grey matter by white fibres. [illegible] (Freudenstein.)

[illegible] 2 to 6 is the same, so that the size and relations of corresponding [illegible]

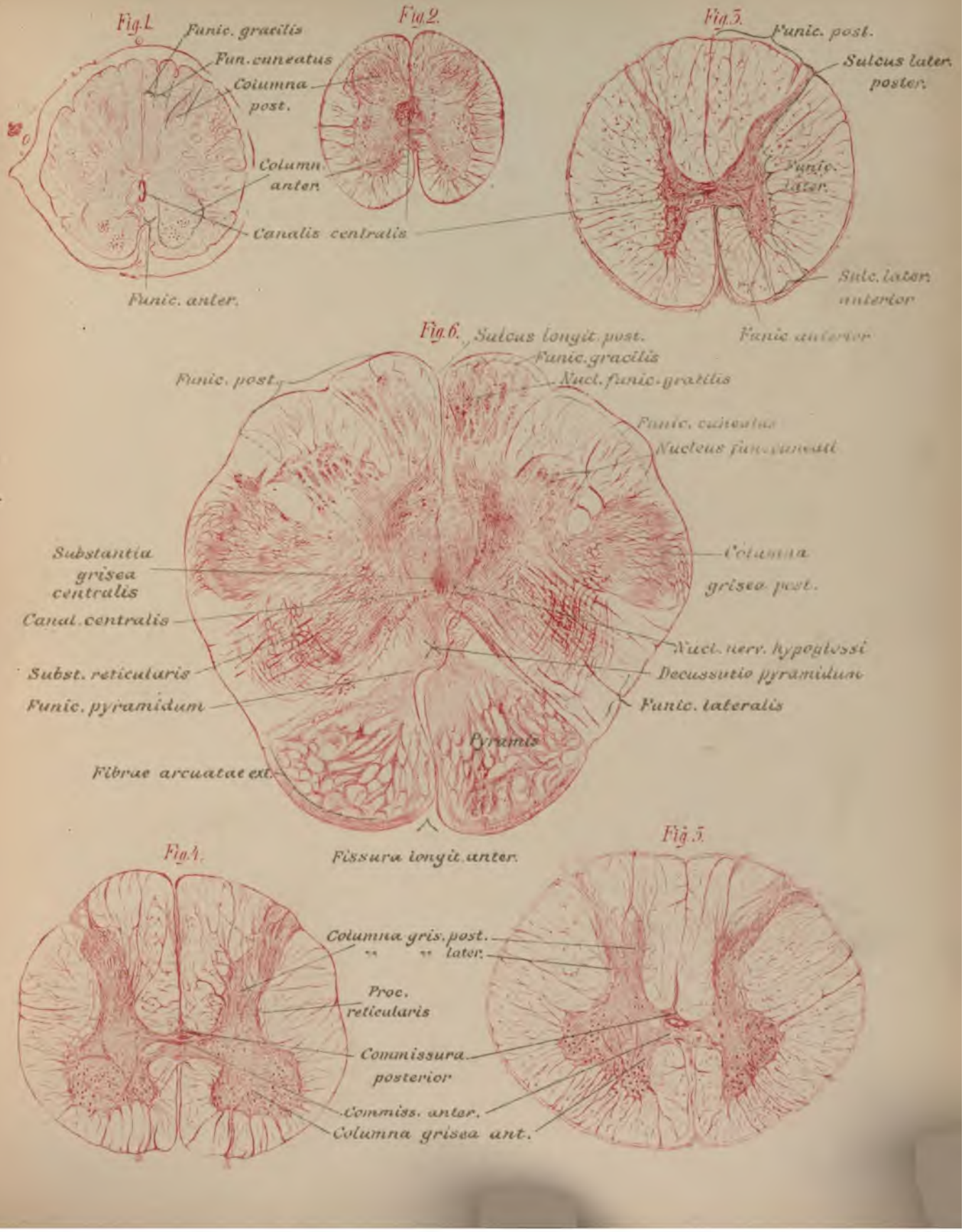
Fig. 1.
Funic. gracilis
Fun. cuneatus
Columna post.
Column anter.
Canalis centralis
Funic. anter.
Fig. 2.
Fig. 3.
Funic. post.
Sulcus later. poster.
Funic. later.
Sulc. later. anterior
Funic. anterior
Fig. 6.
Sulcus longit. post.
Funic. gracilis
Funic. post.
Nucl. funic. gracilis
Funic. cuneatus
Nucleus fun. cuneati
Substantia grisea centralis
Columna grisea post.
Canal. centralis
Nucl. nerv. hypoglossi
Subst. reticularis
Decussatio pyramidum
Funic. pyramidum
Funic. lateralis
Pyramis
Fibrae arcuatae ext.
Fissura longit. anter.
Fig. 4.
Fig. 5.
Columna gris. post.
" " later.
Proc. reticularis
Commissura posterior
Commiss. anter.
Columna grisea ant.



D. 2.

Fig. 1.

Fig. 2.

Fig. 3.

Fig. 6.

Fig. 4.

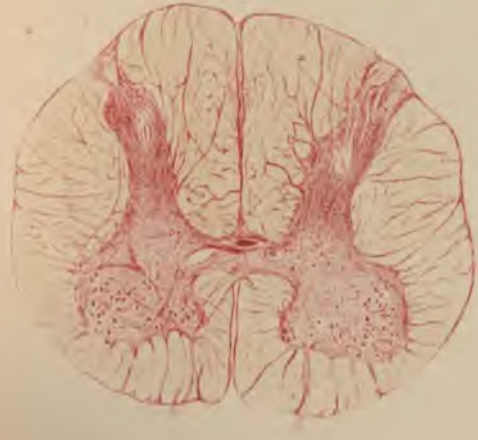

Fig. 5.

Fig. 1.

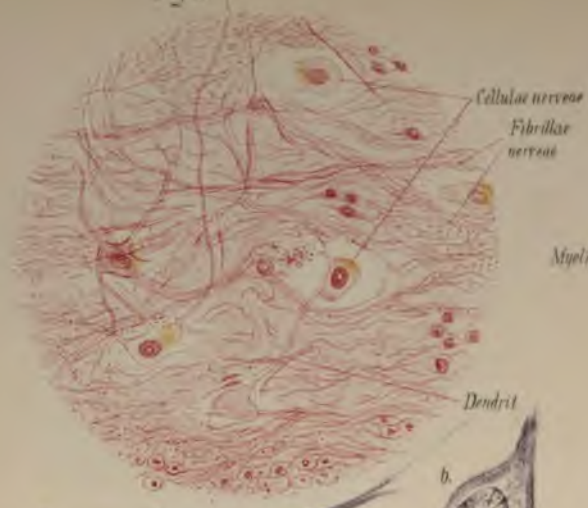

Fig. 2.

Fig. 3.

Fig. 4.

Fig. 5.

Sulc. long. post.
Sulc. intermed. post.
Sulcus lat. post.
Funiculus gracilis
" cuneatus
" pyram. later.
" Cerebelli later.
Columna gr. post.
Columna lat.
Canalis central.
Column. grisea ant.
Funiculus anterior
Fun. ant. pyramidis
Sulcus lat. ant.
Fissura long. anter.

Fig. 5.

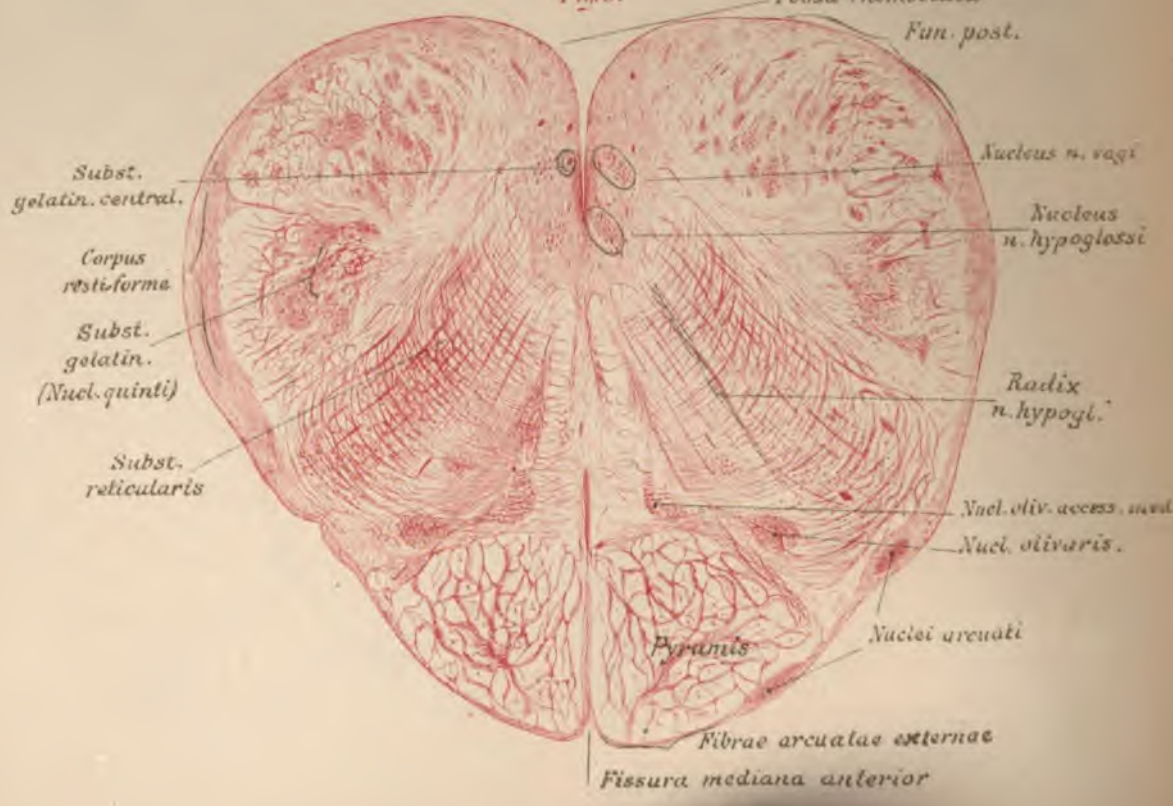
Fossa rhomboidea
Fun. post.
Subst. gelatin. central.
Nucleus n. vagi
Nucleus n. hypoglossi
Corpus resti-forme
Subst. gelatin. (Nucl. quinti)
Radix n. hypogl.
Subst. reticularis
Nucl. oliv. access. med.
Nucl. olivaris.
Nuclei arcuati
Pyramis
Fibrae arcuatae externae
Fissura mediana anterior

D 3. NERVE ELEMENTS FROM CORD AND MEDULLA—MEDULLA OBLONGATA (continued).

FIG. 1. **Part of the Anterior Horn of the Spinal Cord of an Adult** (×200).—Taken from a body one day after death. Nerve cells and their processes can be seen, and both medullated fibres and very fine fibrillæ. The staining substance in the cells is not arranged as in those from more recent specimens. Müller's fluid, picrocarmine.

FIG. 2. **From the White Matter of Burdach's Tract, from the same Specimen as Fig. 1.**—The medullated fibres are seen to vary considerably in size, some being large and others very small. Each fibre is separated from its neighbours by the nerve connective tissue (*neuroglia*), stained pink, which also forms a delicate sheath for the fibres, which do not possess a neurilemma in the central nervous system.

The medullary sheath is stained greyish, and presents here a peculiar laminated appearance (possibly artificial in origin). The axis cylinders, stained red, are somewhat shrunken, and may lie in the centre of the medullary sheath, or to one side.

FIG. 3. **Three Nerve Cells isolated from the Spinal Cord of a Five-Months Fœtus (prepared shortly after Birth).**—*a* shows small collections of deeply stained material at the outer part of the cell, and in some parts the protoplasm itself presents a laminated appearance.

b, A cell with three processes in the field of vision, and a few masses of deeply-stained material, *chr*, arranged in the outer part.

c, A nerve cell, with the neuroglia supporting it; it presents only two processes in the plane of the section. ½ per cent. chromic acid, graduated alcohols (40 per cent. to absolute), stained weak hæmatoxylin.

FIG. 4. **Part of the Posterior Horn from a very Thin Transverse Section of the same Preparation as Fig. 3.**—The nerve cells are shown supported by neuroglia, and show masses of deeply-staining material in the outer part of the cell (*cf.* Plate D 1, Figs. 5, 6, and 8, and Plate D 6, Figs. 1 and 2).

FIG. 5. **Cross-section of the Medulla Oblongata of an Adult, just above the Opening out of the Central Canal into the Fourth Ventricle** (×7).—The central canal has gradually shifted dorsalwards, carrying with it the substantia gelatinosa centralis, and the nuclei of origin of the cranial nerves, and now that the central canal has opened out into the fourth ventricle, or *fossa rhomboidea*, these nuclei come to lie in its floor.

The *nucleus gracilis* and *nucleus cuneatus* are still present, but are much smaller than in Plate D 2, Fig. 6, while the white fibres of the inferior cerebellar peduncle, or *restiform body*, are much more numerous; below this, the *substantia gelatinosa* of Rolando, with the *ascending root of the fifth nerve*, are distinctly visible.

In addition to the cranial nerve nuclei, of which the twelfth and the tenth are visible, the latter being above and external to the former, there are certain fresh areas of grey matter as follows:

1. *The Olivary Nucleus.*—Just above the pyramid, two small areas of grey matter are seen; these are the commencement or lower end of the olivary nuclei, the inner one being the *accessory olive*, the outer the *olivary nucleus* itself, which becomes much larger as it is traced upwards (*cf.* Plate D 5, Fig. 1).

2. *The External Arcuate Nuclei.*—Near the surface of the medulla, just external to the pyramids, are two small collections of grey matter, in connection with the external arcuate fibres as they pass from the gracile and cuneate nuclei round the medulla, and up the anterior median fissure to join the fillet.

The main longitudinal tracts of white matter seen in the section are:

i. The *restiform body* above.

ii. The *pyramids* below.

iii. The *fillet* just above the pyramids.

The remainder of the section is for the most part made up by the *formatio reticularis*.

At the upper part of the supplementary leaf, two diagrammatic cross-sections of the spinal cord are given, that on the left from the cervical enlargement, that on the right from the lower thoracic region.

The arrangement of the grey and white matter is shown, and its division into functional tracts is indicated by different shadings.

D. 4.

D. 4

Fig. 1.

Fig. 3.



Fig. 2.

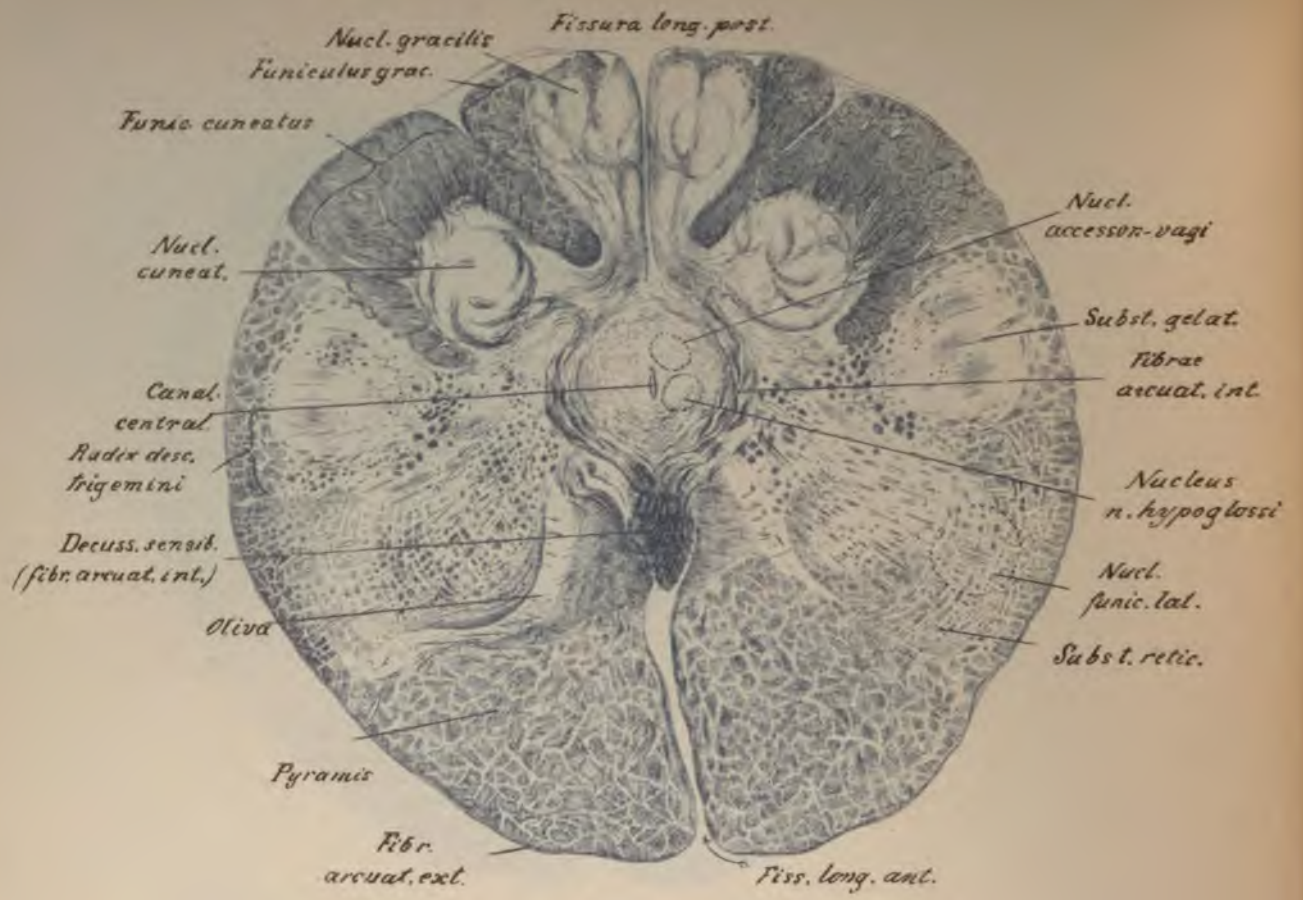
Nucl. gracilis
Fissura long. post.
Funiculus grac.
Funic. cuneatus
Nucl. cuneat.
Nucl. accesson-vagi
Subst. gelat.
Fibrae arcuat. int.
Canal. central.
Radix desc. trigemini
Nucleus n. hypoglossi
Decuss. sensib. (fibr. arcuat. int.)
Nucl. funic. lat.
Oliva
Subst. retic.
Pyramis
Fibr. arcuat. ext.
Fiss. long. ant.

Fiss. long. post.
Funic. gracilis
Funiculus cuneatus
Nucl. fun. grac.
Columna grisea, post.
Canalis centralis
Funic. lateralis
Columna grisea ant.
Decussatio pyramidum
Fiss. long. ant.
Funic. ant.

D 4. MEDULLA OBLONGATA (continued).

FIG. 1. **Transverse Section of Medulla Oblongata** (×9).—From about the same position as that of Plate D 2, Fig. 6.

The Weigert-Pal method of staining enables the course and relations of the bundles of white fibres to be more readily made out than in the latter specimen, which was stained with picrocarmine.

The **grey matter** in this specimen is counterstained by magenta, and includes :

The *nucleus gracilis.*

The *nucleus cuneatus.*

The *central grey matter,* with the nuclei of origin of the vago-accessory and of the hypoglossal nerves.

The lower part of the *olivary nucleus.*

The *substantia gelatinosa* of Rolando.

Formatio reticularis, with the *nucleus lateralis* in its outer part, near the surface of the medulla.

The **white fibres** run both longitudinally (*i.e.,* at right angles to the plane of the section) and transversely (directly in the plane of the section), and are stained a dark purple.

The chief longitudinal bundles are :

The *funiculus gracilis*—prolongation of Goll's column.

The *funiculus cuneatus*—prolongation of Burdach's column.

The *ascending or sensory root* of the fifth (just external to the substantia gelatinosa of Rolando).

The *pyramids.*

The fibres running in the plane of the section are :

The *internal arcuate* fibres, passing round the central grey matter to the *supra-pyramidal or sensory decussation.*

A thin layer of *external arcuate* fibres, passing outside the pyramids and along the anterior fissure to the sensory decussation. Weigert-Pal method. (Sobotta.)

FIG. 2. **Transverse Section of the Medulla Oblongata just above the Cord** (×9).—The commencement or lower level of the *decussation of the pyramids* is well seen. A large

bundle of white fibres passes from the anterior column of the right side of the medulla to the lateral column of the left (right of the figure), almost separating the anterior horn from the body of the grey matter.

The decussating bundles pass alternately, so that only a few fibres are seen passing to the right.

The posterior horns of grey matter are small, and pushed ventralwards by the large development of the posterior columns, which are here divided into the *funiculus gracilis* and the *funiculus cuneatus;* in the former the grey nucleus is just beginning to appear, and this enlarges in ascending through the medulla, while the white fibres get less (*cf.* Fig. 1, *supra*).

The substantia gelatinosa of Rolando at the apex of the posterior horn is well developed. Weigert-Pal method. (Sobotta.)

FIG. 3. **The Central Canal from Fig. 1, with the Surrounding Substantia Gelatinosa Centralis** (×135).—The epithelium of the central canal is well shown, and around it, either scattered or collected into little groups, are the nuclei of the neuroglia.

The *substantia gelatinosa centralis* is free from nerve fibres; but just below it, in the lower half of the figure, fine medullated fibres appear (stained black). Weigert-Pal method. (Sobotta.)

NOTE.—In the outline sketch of Fig. 1, *Radix desc. trigemini* should be *Radix ascend. trigemini.*

D.5.

Fig. 1.

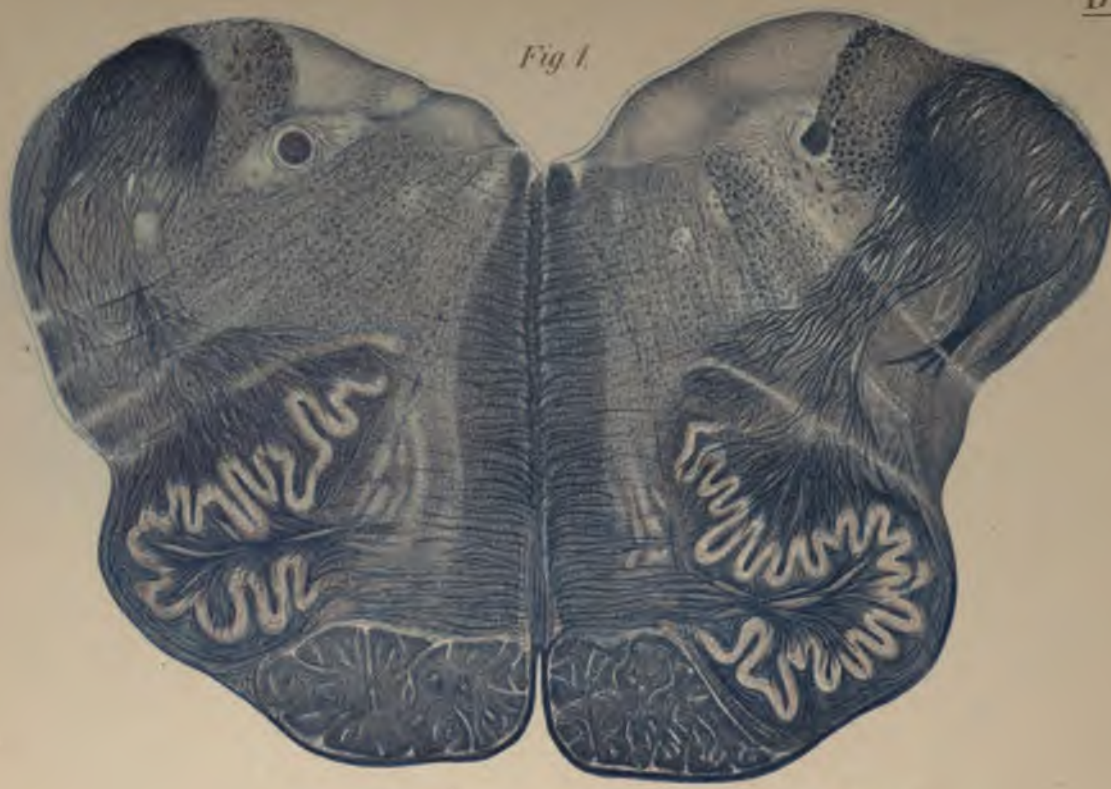

Fig. 2.

Fig. 3.

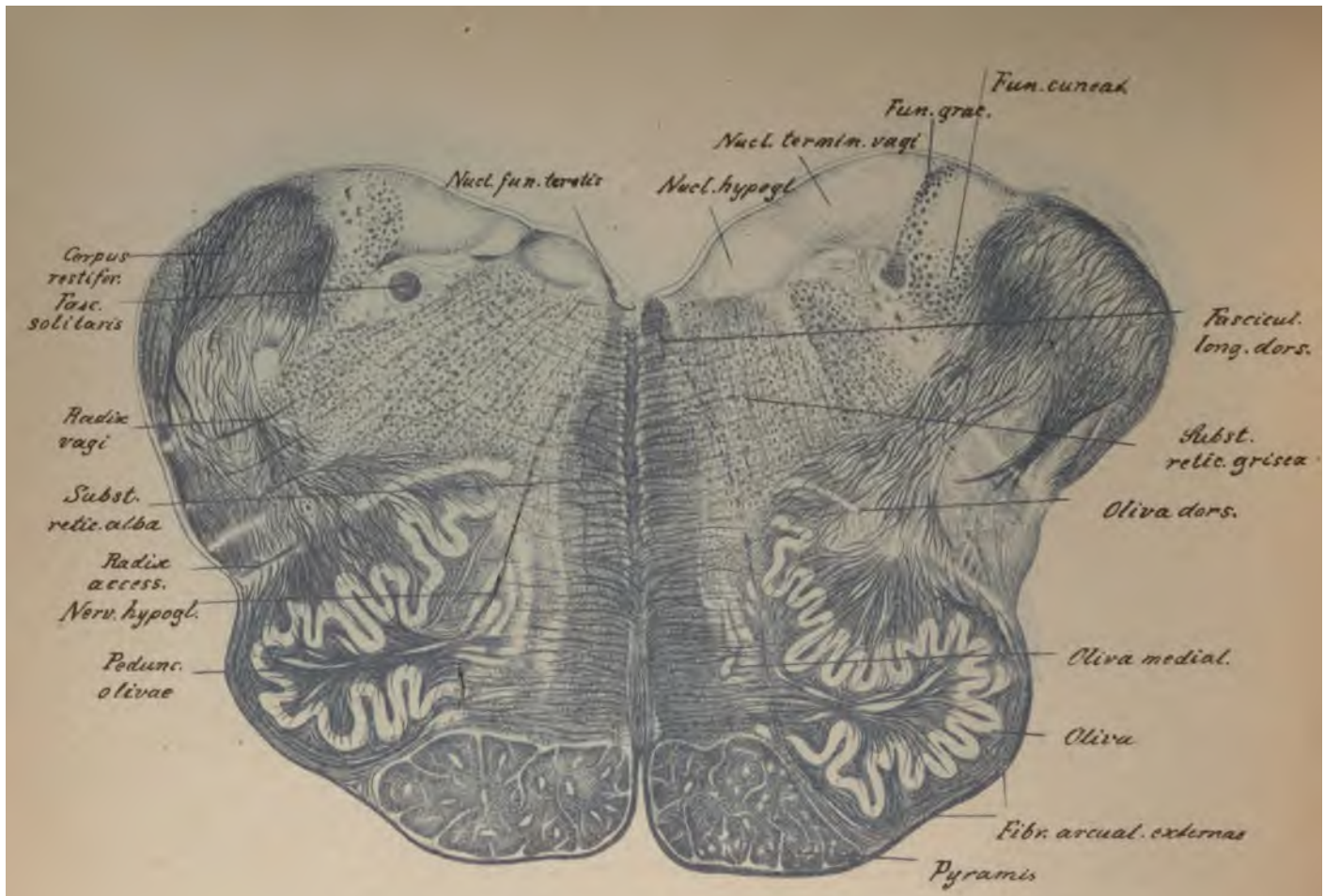
Fun. cuneat.
Fun. grac.
Nucl. termin. vagi
Nucl. fun. teretis
Nucl. hypogl.
Corpus restifor.
Fasc. solitaris
Fascicul. long. dors.
Radix vagi
Subst. retic. grisea
Subst. retic. alba
Oliva dors.
Radix access.
Nerv. hypogl.
Pedunc. olivae
Oliva medial.
Oliva
Fibr. arcual. externae
Pyramis

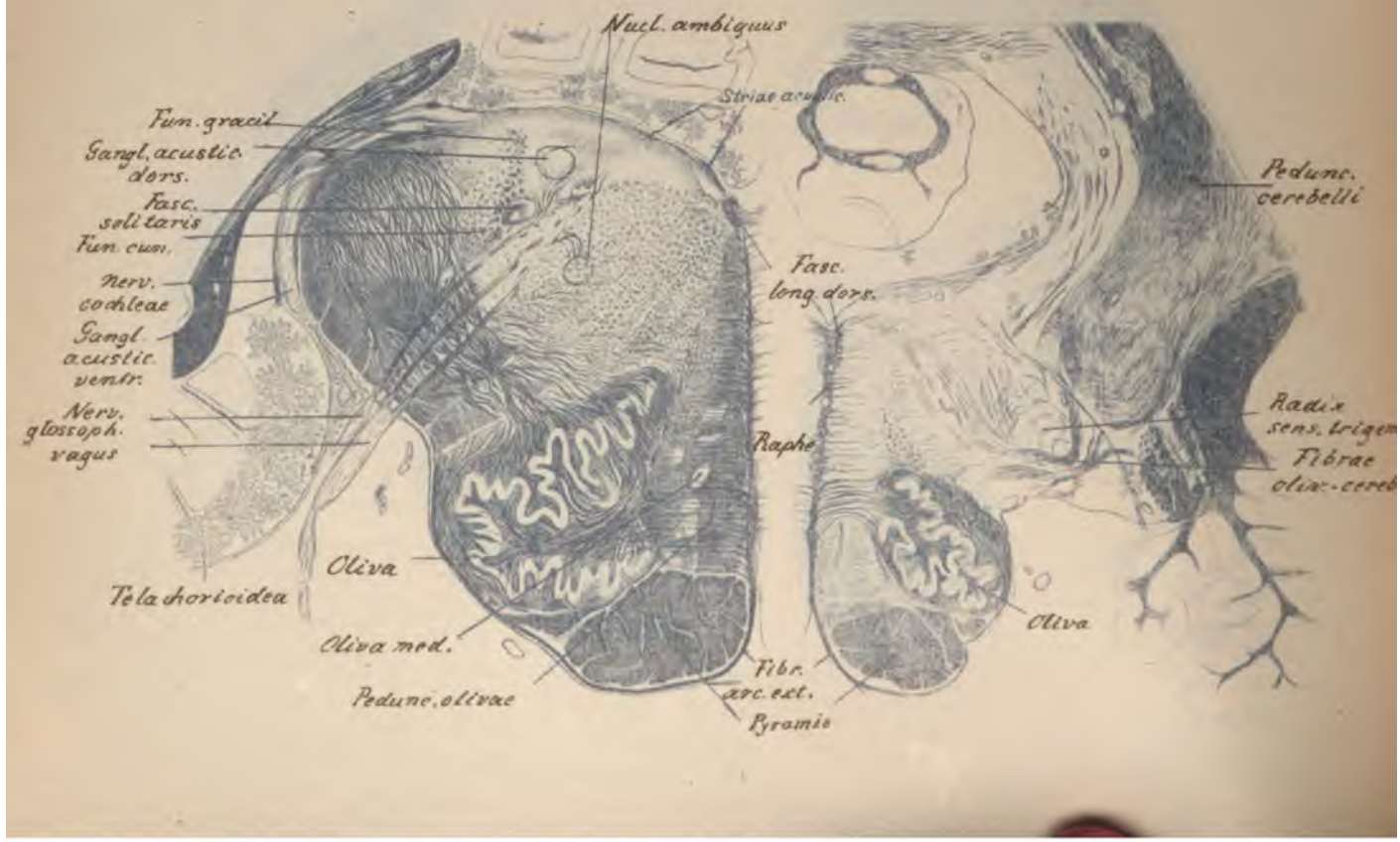
Nucl. ambiguus
Striae acustic.
Fun. gracil.
Gangl. acustic. dors.
Fasc. solitaris
Fun. cun.
nerv. cochleae
Gangl. acustic. ventr.
Nerv. glossoph. vagus
Pedunc. cerebelli
Fasc. long. dors.
Raphe
Radix sens. trigem.
Fibrae olivo-cerebell.
Oliva
Tela chorioidea
Oliva med.
Pedunc. olivae
Fibr. arc. ext.
Pyramis
Oliva

D 5. MEDULLA OBLONGATA (continued). COMMENCEMENT OF PONS VAROLII.

FIG. 1. **Transverse Section of the Medulla Oblongata just above the Commencement of the Fossa Rhomboidalis** (× 6·5).—The relations of the various structures show considerable differences from the specimen shown in Plate D 4, Fig. 1, owing to the opening out of the central canal to form the *fourth ventricle*, and to the nuclei of origin of the cranial nerves forcing the nuclei gracilis and cuneatus laterally, and also to the development of fresh nuclei of grey matter, such as the olive.

The chief collections of **grey matter** seen are :

The *nucleus gracilis*, and the *nucleus cuneatus*—much smaller than in the previous specimens.

The grey matter in the floor of the fourth ventricle, forming a projection, the *funiculus teres*, in which are :

The *hypoglossal nucleus*, placed close to the mid-line, but separated from it by the *nucleus of the funiculus teres*.

The nucleus of the *vagus and glosso-pharyngeal*, lying external to the hypoglossal.

Lying just beneath this nucleus is a longitudinal bundle of white fibres, the *fasciculus solitarius*, which forms an ascending root for the combined nucleus (vagus and glosso-pharyngeal), like that of the fifth nerve seen in Plate D 4, Fig. 1.

The *olivary nucleus*, or corpus dentatum of the olive.

This consists of a wavy line of grey matter closed towards the surface—open towards the mid-line—forming the *hilum*, at which a large number of fibres leave, forming the *peduncle of the olive*, and diverge towards the raphe, a few turning round the nucleus itself and forming a capsule (*siliqua olivæ*).

From its upper surface, internal arcuate fibres pass upwards to join the restiform body, and must be distinguished from the internal arcuate fibres which pass from the gracile and cuneate nuclei to form the fillet.

There are generally also two *accessory olives*—one dorsal, the other to the inner side of the main nucleus.

The most important collections of **white fibres** seen are :

The *pyramids*.

The *fibres of the hypoglossal*, passing between the olive and the accessory olive.

The *fibres of the vagus*, between the olive and the restiform body.

The *fasciculus solitarius*, referred to above.

The *arcuate fibres*, internal and external, the latter being well marked around the external surface of the olivary nucleus.

The *restiform body*, passing to the cerebellum.

The remainder of the section is composed chiefly of formatio reticularis, which in this situation consists of two parts—a lateral *formatio reticularis grisea*, containing nerve cells; a central *formatio reticularis alba*, from which nerve cells are for the most part absent. The longitudinal fibres of this latter portion in the upper part form the *posterior longitudinal bundle*, in the lower part the longitudinal fibres of the *fillet*. Weigert-Pal method. (Sobotta.)

FIG. 2. **The Left Half of a Section of the Upper Part of the Medulla Oblongata** (×5). —The combined vagus and glosso-pharyngeal nucleus is seen, and the fibres of the two nerves pass directly out just below the restiform body; immediately below the main nucleus is the *nucleus ambiguus*, which gives off fibres to the vagus root, and is therefore an *accessory vagus nucleus;* while just above the main nucleus is the fasciculus solitarius, which is now in close relation with it.

Above and to the outer side of the combined vago-glosso-pharyngeal nucleus is a large area of nerve cells, the *dorsal auditory nucleus* (*gang. acustic. dors.*), above which the transversely-running *striæ acusticæ* pass in their course to the cerebellum. The main or *cochlear division* of the auditory nerve (*nerv. cochleæ*) passes from the dorsal auditory nucleus above the restiform body, round which it winds, and another collection of nerve cells occurs in it, the ventral auditory nucleus (*gang. acusticæ ventr.*); some of the fibres of the auditory nerve leave the medulla ventrally to the restiform body, but they are not caught in this section.

The remaining parts of the section are closely similar to the corresponding parts in Fig. 1, the nucleus of the fasciculus teres and the posterior longitudinal bundle being especially well marked. Weigert-Pal method. (Sobotta.)

FIG. 3. **The Right Half of a Cross-section of the Medulla near the Commencement of the Pons** (×3·5).—To show the relations of the restiform body.

The restiform body forms the inferior peduncle of the cerebellum; the white fibres of which it is composed are seen passing upwards to the cerebellum.

The internal arched fibres from the upper surface of the olive (*fibræ olivæ cerebelli*) are seen winding round the ascending root of the fifth nerve (*radix sens. trigem.*) to join the restiform body. The remaining structures of the section are similar to the corresponding ones in Fig. 2. Weigert-Pal method. (Sobotta.)

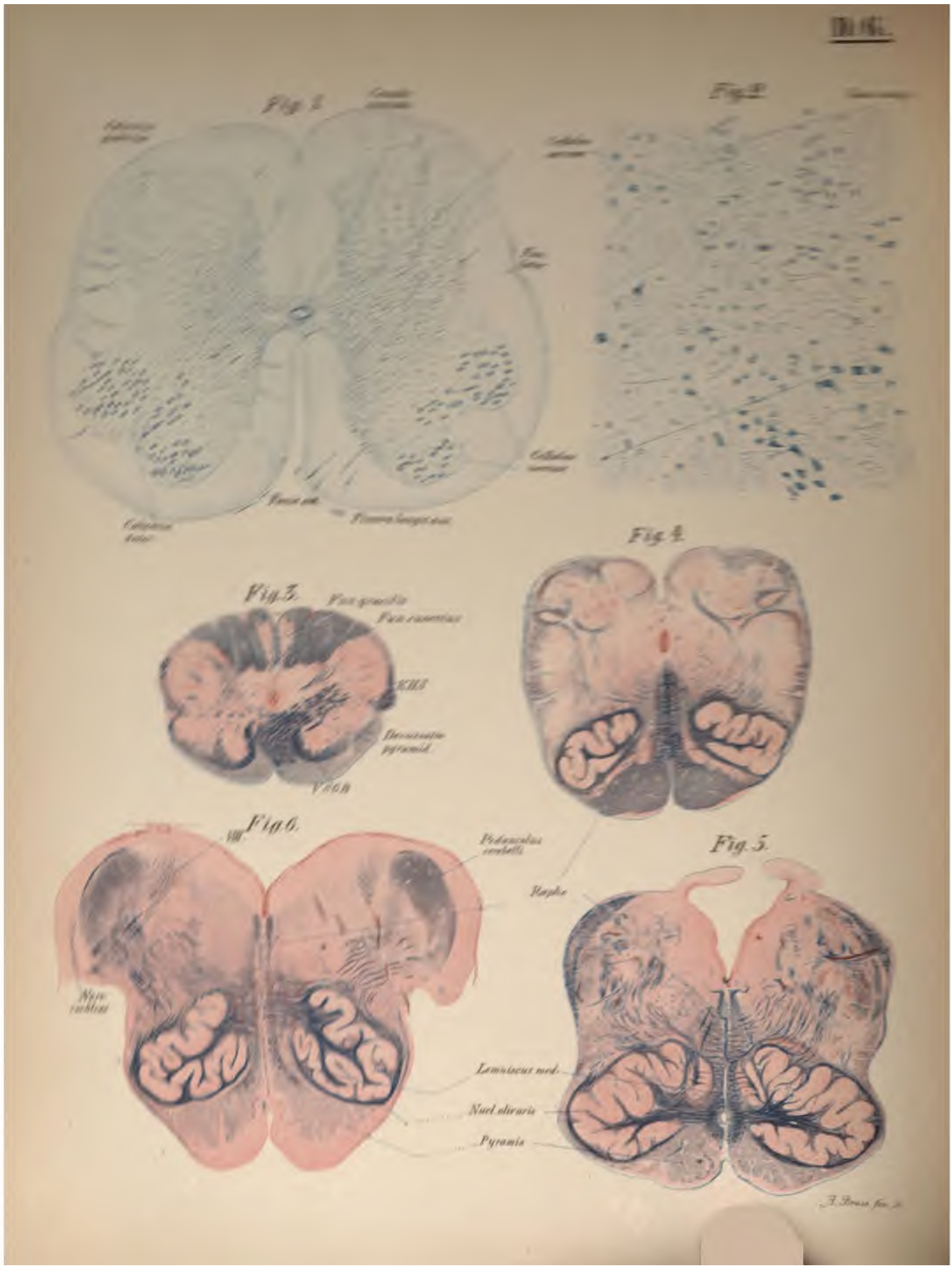
Fig. 1.
Fig. 2.
Fig. 3.
Fun. gracilis
Fun. cuneatus
Decussatio pyramid.
Fig. 4.
Fig. 5.
Raphe
Lemniscus med.
Nucl. olivaris
Pyramis
Fig. 6.
Pedunculus cerebelli
Nerv. cochlear.

D 6. SPINAL CORD AND MEDULLA OBLONGATA OF THE CHILD AT BIRTH.

FIG. 1. **Cross-section of the Lumbar Part of the Cord of a Newly-born Child (×20).**—The large size of the grey matter, especially of the posterior horns, in relation to the white matter, which is small in quantity in this region, is noticeable. The large deeply-stained nerve cells of the anterior horn are arranged in three distinct groups. Methylene blue, Nissl's method. (Sobotta.)

FIG. 2. **Part of the same Section more highly magnified (50).**—The cells in the lower part of the section are motor in function, those in the upper part sensory. The latter are smaller, and their processes less distinct. Methylene blue, after Nissl. (Sobotta.)

FIG. 3. **Cross-section of the Medulla Oblongata of the New-born Child at the Commencement of the Decussation of the Pyramids (×6).**—The medullated fibres are stained violet; the grey matter and those tracts of nerve fibres which have not yet acquired their medullary sheath are red.

The grey matter is very similar to that of the fully-developed medulla, and some medullated fibres are seen crossing from the pyramids to the lateral column, which is, however, red, as the pyramidal tract has not yet assumed its medullary sheath. All the other tracts are myelinated. (The pyramidal fibres are the last to become medullated.)

K H S, Lateral cerebellar tract.

V S G B, Anterior column ground bundle. Müller's fluid, stained Weigert-Pal method, counterstained carmine. (Sobotta.)

FIG. 4. **Cross-section of the Medulla at the Commencement of the Olive (×6).**—The grey matter of the olive is well developed, but only a few of the fibres belonging to it are medullated. The pyramids and a few of the fibres crossing at the raphe are also stained—that is, have acquired their medullary sheath. Preparation as for Fig. 3.

FIG. 5. **Cross-section of the Medulla just above the Opening out of the Central Canal into the Fourth Ventricle (×6).**—The pyramids, the olives, and the restiform bodies are distinctly visible, the olive possessing already its peduncle and its internal arched fibres directed towards the restiform body. A few fibres of the hypoglossal nerve root can be seen passing downwards towards the inner side of the olive from the grey matter in the floor of the triangular space, *the fourth ventricle;* and to the outer side

of the olive, a few fibres of the vagus and glosso-pharyngeal passing just below the restiform body. Preparation as for Fig. 3.

FIG. 6. **Cross-section of the Medulla of the Child at the Level of the Origin of the Cochlear Division of the Auditory Nerve** (× 6).—The restiform body (*pedunculus cerebelli*) is seen to be partly medullated. To its inner side lies the dorsal nucleus of the auditory nerve—VIII. (*cf.* Plate D 5, Fig. 2); the dorsal root, or cochlear division of the nerve, passes above the restiform body, and has not yet acquired its medullary sheath; a few medullated fibres are seen passing beneath the restiform body; they belong probably to the vagus, or glosso-pharyngeal.

The vestibular or ventral root of the auditory nerve is not shown. Preparation as in Fig. 3.

NOTE.—All the above specimens are obtained from the nervous system of the child at birth. Since so many of the fibres have not yet acquired their medullary sheath, the appearances presented by these sections differ considerably from the corresponding sections in the adult.

Nerve cells are present in large numbers, as Figs. 1 and 2 demonstrate; as a result of this and the lack of white fibres, the nuclei of grey matter appear much larger in proportion than in the adult, as is readily seen in the case of the olivary nucleus in Figs. 4, 5, and 6.

The situation of Fig. 3 is between the sections Figs. 1 and 2, Plate D 4, while Fig. 5 corresponds to that of Fig. 1, Plate D 5.

[illegible] MEDULLATED FIBRES AND THEIR ARRANGEMENT

FIG. 1. **Arrangement of Fibres in the Raphe of the Medulla Oblongata of the New-born Child (× 75).** [illegible]

[illegible] Weigert-Pal; counterstained [illegible]

FIG. 2. **Strands of Fibres at the Margin of the Olivary Nucleus of a New-born Child (× 75).**—[illegible] and contains only few medullated fibres. [illegible] Prepared as above. (Sobotta.)

FIG. 3. **Nerve Cells and Fibres of the Olivary Nucleus in the New-born Child more highly magnified (400).** [illegible] and each presents a large nucleus with a [illegible] the nuclei of which are well shown. The medullated fibres are much less numerous, and very fine in comparison with those in the same situation in the adult. Prepared as above. (Sobotta.)

FIG. 4. **Arrangement of the Fibres in the Olivary Nucleus of the Adult (× 75).**—Each nerve cell is surrounded by a network of medullated fibres, and the margin of the whole fold (or part of the olive) has a large strand of fibres winding round it. Weigert-Pal method. (Sobotta.)

FIG. 5. **Fibres from the Raphe in an Adult (× 400).** The individual fibres vary considerably in thickness, and are seen running for the most part in the plane of the section, some horizontally, others vertically or obliquely. A few are cut across transversely; and here, again, the difference in diameter is noticeable.

The fibres are supported by a bed of neuroglia, the nuclei of which are stained red.

None of the fibres are uniform in contour; all possess indentations, the *incisures of Lantermann*, but these show no regular arrangement. Many of the fibres present small bulgings, or varicosities, in their course, probably the result of the action of the reagents used in preparing the specimens. Weigert Pal: counterstained magenta. (Sobotta.)

FIG. 6. **Nerve Cells and Fibres from the Nucleus of the Vagus in the same Preparation (× 400).** The large multipolar nerve cells supported by neuroglia are well shown. The fibres are very fine, some of the finest being only just distinguishable; the difference in size compared with those of Fig. 5 is worthy of notice, both figures being represented under the same degree of magnification. Weigert Pal: counterstained magenta. (Sobotta.)

Fig. 1.

Fig. 2.

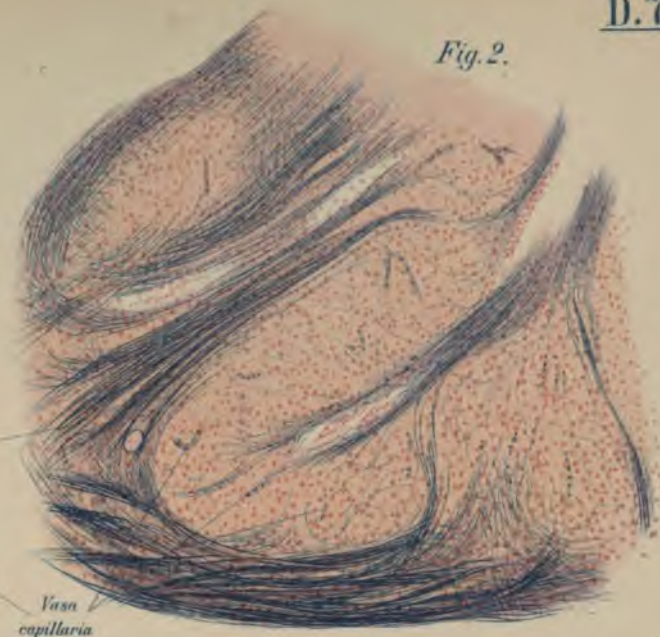

Neuroglia

Fig. 3.

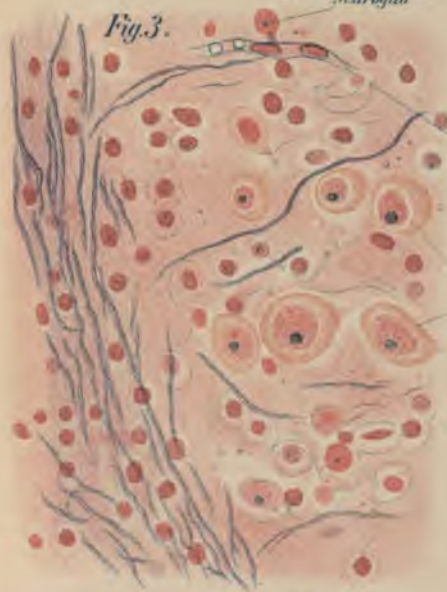

Vasa capillaria

Fig. 4.

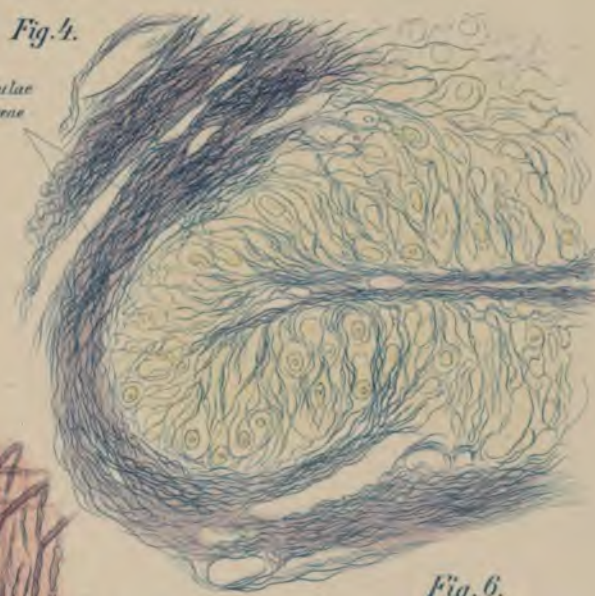

Cellulae nerveae

Fig. 5.

Fig. 6.

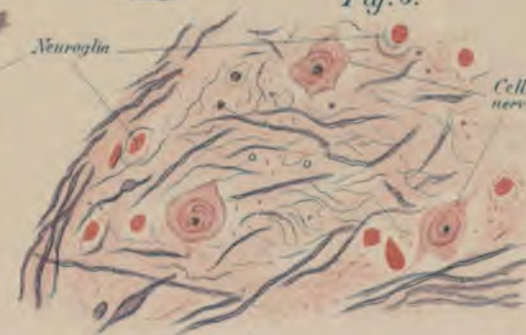

Neuroglia

Cell. nerv.

B. Brass fec.

Fig. 1.

Fig. 2.

A. Brauns fec.

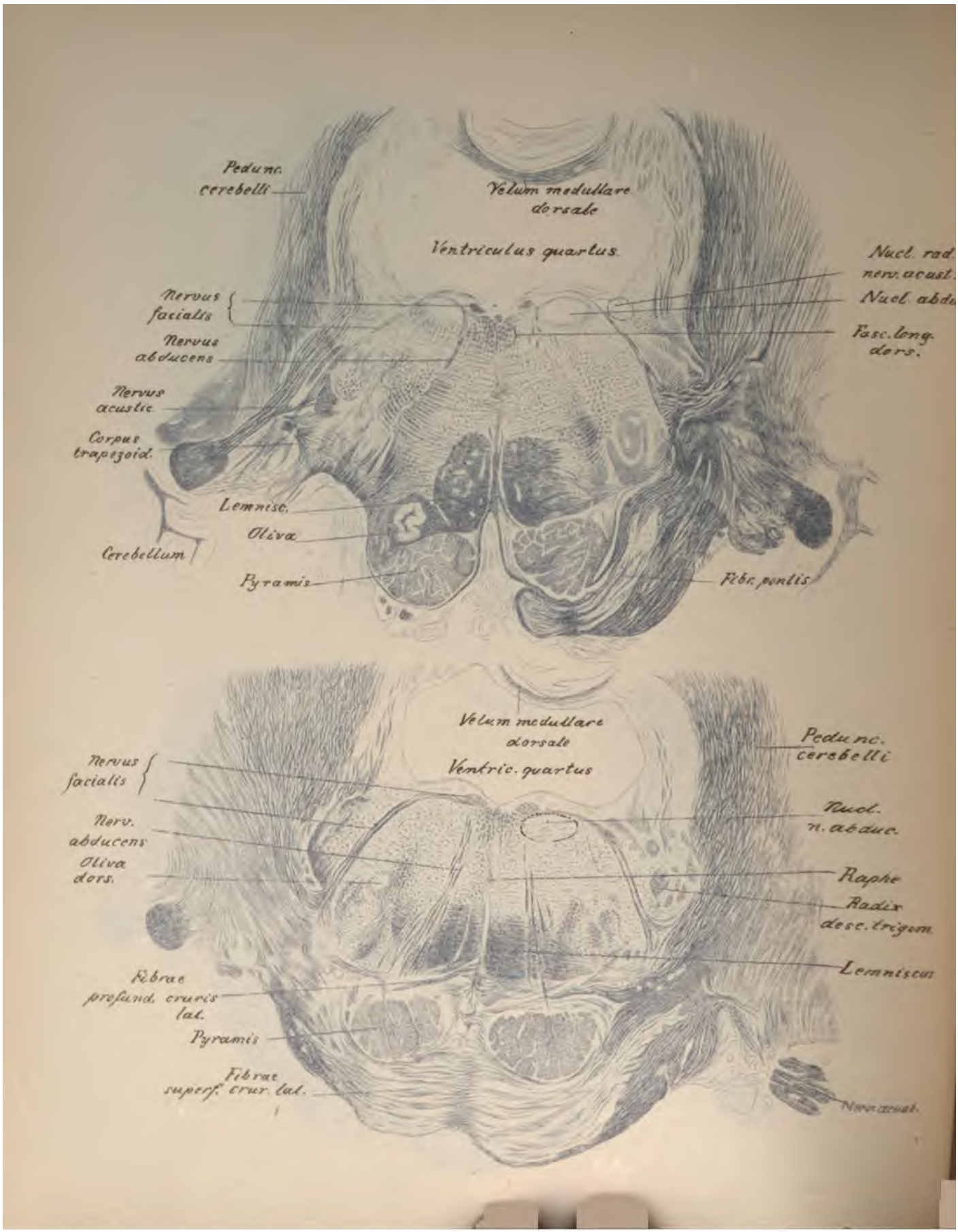
Pedunc. cerebelli
Velum medullare dorsale
Ventriculus quartus
Nucl. rad. nerv. acust.
Nucl. abdu
Nervus facialis
Nervus abducens
Fasc. long. dors.
Nervus acustic.
Corpus trapezoid.
Lemnisc.
Oliva
Cerebellum
Pyramis
Fibr. pontis
Velum medullare dorsale
Ventric. quartus
Pedunc. cerebelli
Nervus facialis
Nucl. n. abduc.
Nerv. abducens
Oliva dors.
Raphe
Radix desc. trigem.
Lemniscus
Fibrae profund. cruris lat.
Pyramis
Fibrae superf. crur. lat.
Nerv. acust.

D 8. PONS VAROLII AND FOURTH VENTRICLE.

FIG. 1. **Cross-section (somewhat oblique) through the Upper End of the Medulla Oblongata (on the left) and the Commencement of the Pons (on the right) (×4).**—The more important structures to be observed on the left side of the figure are :

Collections of **grey matter**:

1. The posterior end of the *nucleus of the sixth nerve* (*nucl. abduc.*), just external to the posterior longitudinal bundle (*fasc. long. dors.*).

2. Two of the *nuclei of the auditory nerve*—one just external to the sixth nucleus, the continuation of the *lateral nucleus;* the other in the auditory root itself, the *ventral nucleus.*

3. Two indistinct collections of grey matter, below and external to the sixth nucleus and just above the trapezium, the upper being the *nucleus of the facial* (*seventh*) *nerve*, the lower the commencement of the *superior olive.*

4. The *olivary nucleus* (*oliva*) is just caught at its extreme upper limit.

The chief collections of **white fibres** are :

1. The fibres of the *restiform body*, ascending up to the cerebellum round the outer boundary of the fourth ventricle (*pedunc. cerebell.*).

2. The fibres of the *auditory nerve*, just beneath it; some of the upper fibres appear to go to the restiform body itself.

3. Below this, the *ascending root of the fifth nerve* is still visible as a small compact bundle in transverse section.

4. The fibres of the *trapezium* (*corp. trapezoid*), winding round the superior olivary nucleus.

5. Just beneath the floor of the fourth ventricle, to the inner side of the nucleus of the sixth nerve, is a small longitudinal bundle of white fibres (*nervus facialis* in the figure), composed of fibres from the facial nucleus, running longitudinally; they then bend round and run in the plane of the section, winding round the nucleus of the sixth, at first dorsal to it, then lateral, as shown in the figure.

6. The fillet (*lemniscus*) and the pyramid are both well defined.

On the right side of the section the grey matter is arranged in a very similar manner, except that the olive itself has ended, and the superior olive is more developed.

The chief difference from the opposite side consists in the large numbers of transversely arranged fibres coming from the cerebellum and passing over the surface of

the medulla, enclosing the pyramid; these are the *superficial transverse fibres of the pons*; a few are seen to cross the auditory nerve root to enter deeply as *deep transverse fibres*. Weigert-Pal, counterstained magenta. (Sobotta.)

Fig. 2. **Section of the Pons at about the Widest Part of the Fourth Ventricle** (×4).—The general arrangement of the structures is similar to that of the right half of Fig. 1. The chief points to be noticed are:

The nucleus of the sixth nerve (*nucl. n. abduc.*) appears a little smaller, and the fibres of the root of the nerve itself are seen passing downwards near the fillet internal to the superior olive and the facial fibres.

The lateral nucleus of the eighth nerve is still to be seen outside the fibres of the facial root.

The superior olive is now well developed (*oliva dors.*).

Considerable changes have occurred in the arrangement of the fibres. The pyramid no longer forms a compact bundle on the surface; it is now separated from the surface by a thick layer of fibres passing from the middle peduncle of the cerebellum on one side to that on the other, the *superficial transverse fibres of the pons* (*fibra superf. crur. lat.*).

The pyramids themselves also show indications of being separated into smaller bundles, and are separated from the fillet, which now occupies a somewhat more dorsal position, by the deep transverse fibres of the pons (*fibra profund. crur. lat.*). These transverse fibres, superficial and deep, are the characteristic feature of the pons.

Most of the fibres of the restiform body have passed upwards to the cerebellum. The fibres of the facial root are distinctly seen winding round the nucleus of the sixth nerve.

The ascending root of the fifth (wrongly marked *radix desc. trigem.* in the figure) and the posterior longitudinal bundle are both well defined. Weigert-Pal, magenta. (Sobotta.)

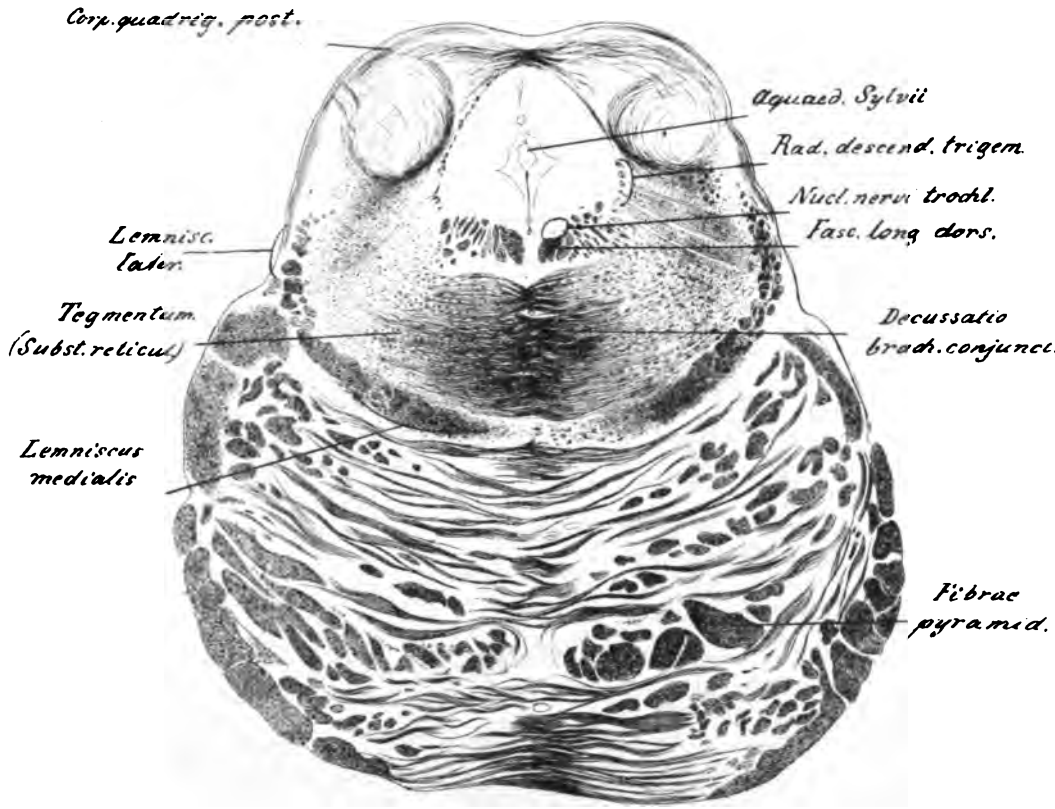
Corp. quadrig. post.
Aquaed. Sylvii
Rad. descend. trigem.
Nucl. nervi trochl.
Fasc. long dors.
Lemnisc. later.
Tegmentum. (Subst. reticul.)
Decussatio brach. conjunct.
Lemniscus medialis
Fibrae pyramid.

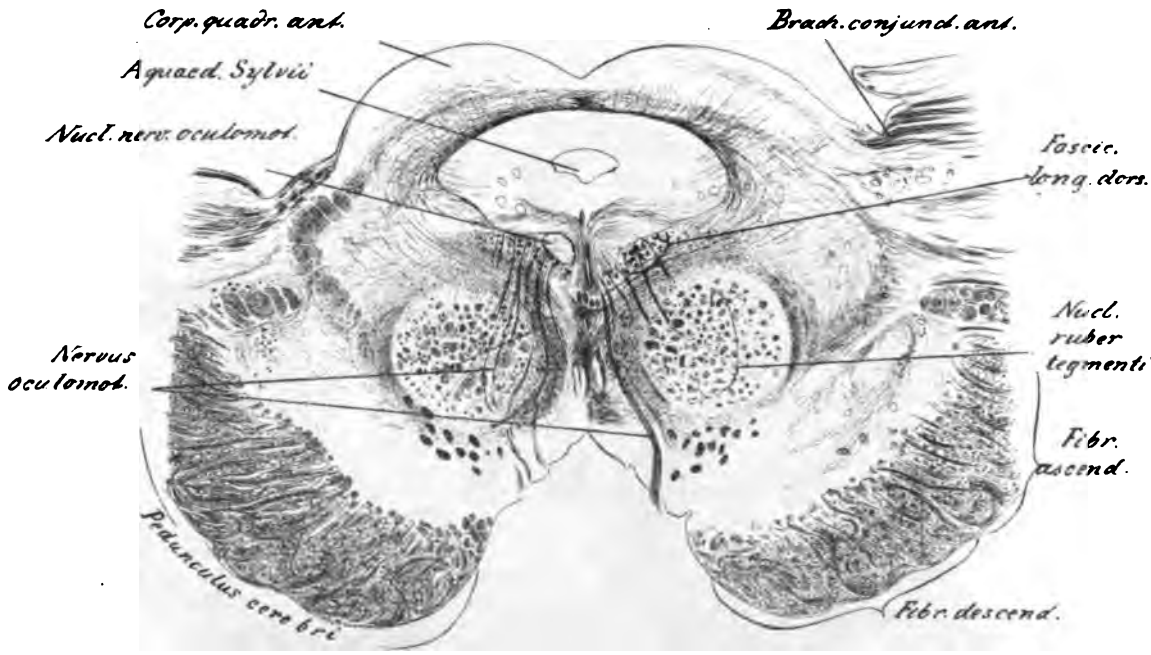
Corp. quadr. ant.
Brach. conjunct. ant.
Aquaed. Sylvii
Nucl. nerv. oculomot.
Fascic. long. dors.
Nucl. ruber tegmenti
Nervus oculomot.
Fibr. ascend.
Pedunculus cerebri
Fibr. descend.

D 9. PONS AND CORPORA QUADRIGEMINA.

FIG. 1. **Cross-section of the Pons and Posterior Corpora Quadrigemina** (×3).—The chief collections of **grey matter** are:

i. The nucleus of the *posterior corpus quadrigeminum*, with a thin covering of white fibres.

ii. The nucleus of the fourth nerve (*nucl. nerv. trochl.*), lying below the floor of the aqueduct of Sylvius.

iii. The central *grey matter of the aqueduct.*

The arrangement of the **white fibres** differs considerably from that in the lower part of the pons and the medulla.

From above downwards we find:

i. Some transverse fibres over the central grey matter—the *posterior commissure.*

ii. A small bundle of fibres (longitudinal), lying beside the central grey matter —the *descending root* of the fifth nerve (*radix descend. trigem.*).

iii. The *posterior longitudinal bundle* (*fasc. long. dors.*), just below the nucleus of the fourth nerve.

iv. A layer of white fibres, both transverse and longitudinal, extending nearly down to the level of the transverse fibres of the pons, constituting the tegmental system of fibres, or *tegmentum.* It is practically a continuation upwards of the formatio reticularis of the medulla, but also contains fibres from the superior peduncle of the cerebellum (*decussatio brach. conjunct.*).

v. Beneath this is the *fillet*, which forms a narrow curved band of longitudinal fibres, divided into two portions—the mesial or median fillet (*lemniscus medialis*), and the lateral fillet (*lemniscus lateralis*).

Below the fillet is the ventral, or pyramidal, part of the pons. The pyramidal fibres are now separated into small bundles—the *pyramidal bundles of the pons*—by the transverse fibres. Weigert-Pal, magenta. (Sobotta.)

FIG. 2. **Cross-section of the Mid-brain through the Anterior Corpora Quadrigemina** (×3·3). —The transverse fibres of the pons are no longer present; the pyramidal fibres are collected together into the middle third of the *crura cerebri*, which have separated from one another, leaving a space—the *posterior perforated space*—between them.

The collections of **grey matter** shown are :

i. The nucleus of the *anterior corpus quadrigeminum*, with thin layers of white matter within it.

ii. The *central grey matter*, with the nucleus of the third nerve in its lower part.

iii. The *red nucleus* of the tegmentum, a large spherical mass of grey matter (*nucl. ruber tegmenti*), through which the fibres of the third nerve pass on their way from the nucleus to the posterior perforated space.

iv. The *substantia nigra*, a large mass of pigmented grey matter, separating the upper, or tegmental, part of the crus from the lower part, or crusta.

The tracts of **white fibres** are :

i. The anterior cerebellar peduncle (*brach. conj. ant.*).

ii. The *posterior longitudinal bundle* and the *fillet*, together with fibres decussating across the raphe, constituting the tegmental system of fibres.

iii. The fibres of the root of the third nerve (*nervus oculomotorius*).

iv. The longitudinal fibres of the *pes*, or *crusta*, the pyramidal fibres occupying the middle third, the frontal cortical fibres being to the inner side, the occipital cortical to the outer side. Weigert-Pal, magenta. (Sobotta.)

FIG. 3. **Part of the Tela Choroidea Inferior from the Preparation of Plate D 5, Fig. 2 (× 30).**—The branching processes (a 'basket work') of pia mater contain bloodvessels, and are covered by an epithelium, which is a continuation of that lining the central canal and the ventricles. Magenta. (Sobotta.)

FIG. 4. **Part of the same more highly magnified (100).**—The epithelial layer is seen in section, enclosing connective tissue and bloodvessels.

FIG. 5. **Cross-section of the Aqueduct of Sylvius, from Fig. 1 (× 20).**

FIG. 6. **Epithelium from the Lining Membrane of the Aqueduct of Sylvius (× 400).** —In the wall four neuroglia cells and a small capillary are seen in section. Magenta. (Sobotta.)

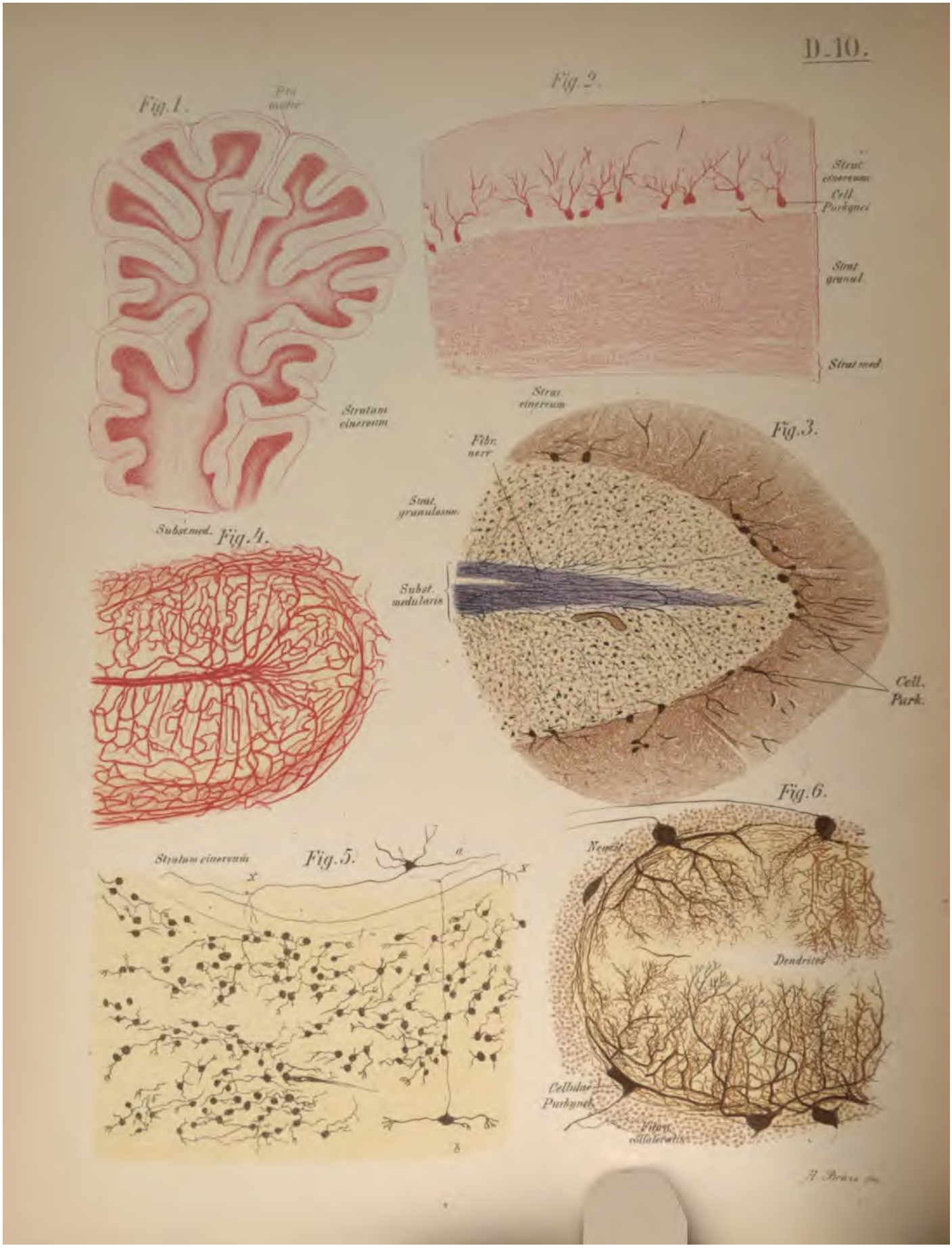
Fig. 1.
Pia mater
Stratum cinereum
Fig. 2.
Strat. cinereum
Cell. Purkynei
Strat. granul.
Strat. med.
Fig. 3.
Strat. cinereum
Fibr. nerv.
Strat. granulosum
Subst. medularis
Cell. Purk.
Fig. 4.
Subst. med.
Fig. 5.
Stratum cinereum
a
b
Fig. 6.
Neurit.
Dendrites
Cellulae Purkynei
Fibra collateralis

D 10. CEREBELLUM.

FIG. 1. **Section of the Upper Part of a Lamina of the Cerebellum** (×6).—The direction of the section is transverse, and at right angles to the margin of the lamina.

The white substance branches in an arborescent manner, and sends in processes to the folds of the lamina; outside the white matter is the *granule layer*, stained deeply owing to the large number of nuclei in it; outside this is the clear *molecular layer*, enclosed in its turn by the *pia mater*, which sends processes between the folds. Borax carmine. (Tuczek.)

FIG. 2. **Section of Cortex Cerebelli** (×75).—*Purkinje's cells* are deeply stained; their ramifying dendritic processes are shown spreading out into the molecular layer.

The nuclei of the cells of the granule layer can be made out, and the white matter internal to this layer. Borax carmine. (Tuczek.)

FIG. 3. **Apex of a Small Lamina treated by the Weigert-Pal Method** (×60).—The medullated fibres of the white centre are stained violet, the granule layer is yellowish, and the molecular layer brown.

The white matter is seen to be pointed—that is to say, it diminishes in quantity towards the apex of the fold; this is due to the fact that fibres are continually being given off into the grey matter, as shown in the figure. Some of the fibres branch among the small nerve cells of the *granule layer*; others go to join the *cells of Purkinje*, of which they form the axis cylinder processes, and a third set pass into the *molecular layer*. (Tuczek.)

FIG. 4. **Arrangement of the Bloodvessels at the Apex of a Fold** (×40).—The situation is similar to that represented in Fig. 3.

A dense network is formed by the lateral branches of the main vessel which passes up the centre of the lamina, and capillary loops are formed which surround the cells of Purkinje. Carmine injection. (Tuczek.)

FIG. 5. **Cells from the Granule Layer** (×200).—The cells in the granule layer are, for the most part, small nerve cells, though occasionally larger ones are found. They are more or less spherical, and possess several dendritic or protoplasmic processes, which branch, but soon end in somewhat claw-like fashion; the axis-cylinder processes of these cells are much longer, and pass outwards into the molecular layer, where they each divide into two small fibres which run horizontally; such a cell is shown at *b*.

a is a cell in the lower part of the molecular layer, a so-called *basket cell*, with its axis-cylinder process *x*. These cells generally lie near the cells of Purkinje, and give off protoplasmic processes into the molecular layer; their axis-cylinder processes pass horizontally, and break up into a basket-work of fibrils, which surround the bodies of the cells of Purkinje. Golgi's method. (Tuczek.)

FIG. 6. **Six Cells of Purkinje at the Bottom of a Furrow between two Laminæ** (× 90).—The bodies of the cells are more or less flask-shaped; from their outer surface large numbers of dendritic or protoplasmic processes are given off into the molecular layer, forming a dense network, which is incompletely represented in the figure; these processes do not anastomose, and they lie for the most part in a plane transverse to the laminæ, comparatively few being seen in a section along the lamina.

Each cell gives off from its base an axis-cylinder process, which passes into the white centre, giving off *collaterals* in its course, as shown in the figure. Golgi's method. (Tuczek.)

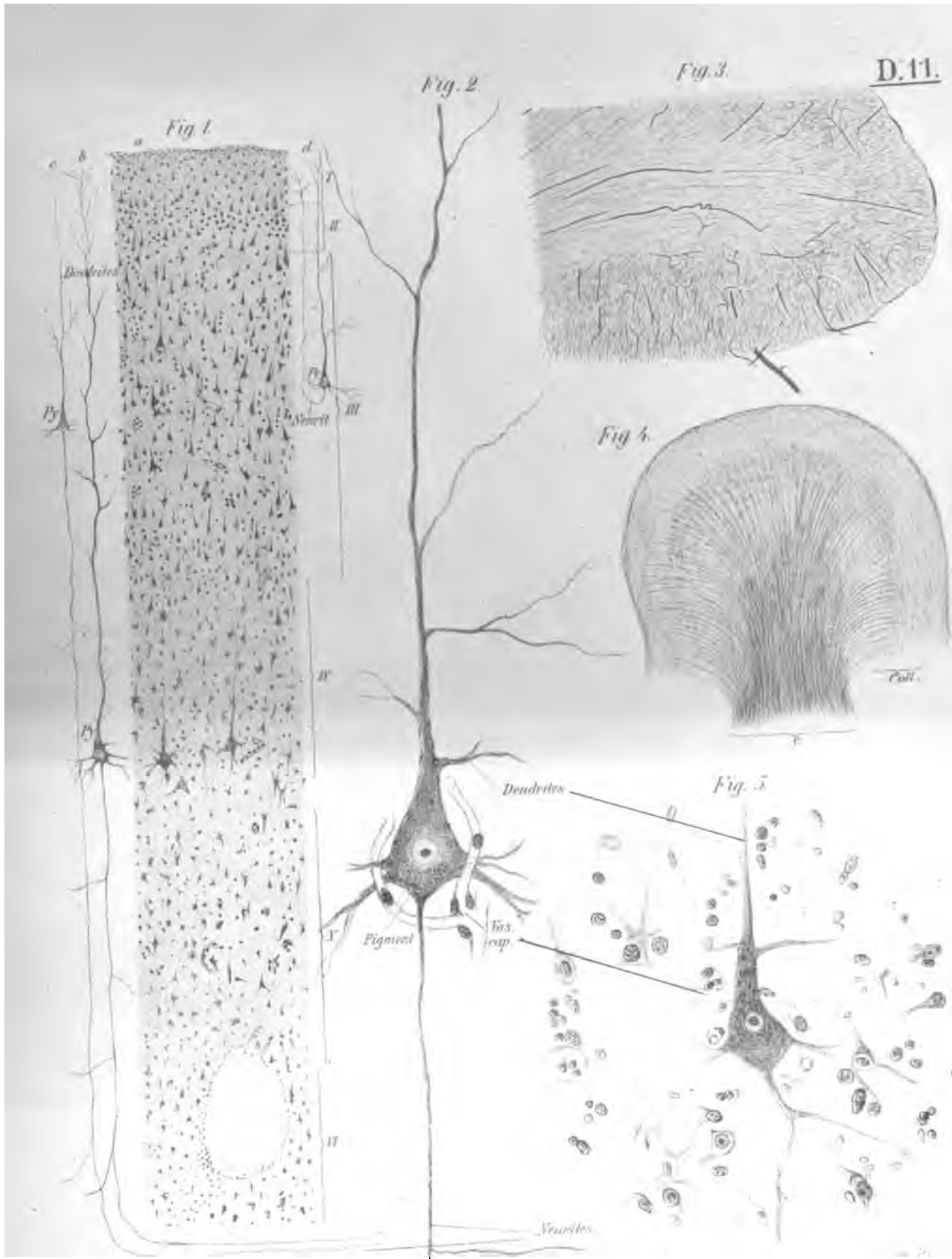
D.11.
Fig. 1.
Fig. 2.
Fig. 3.
Fig. 4.
Fig. 5.
Dendrites
Neurit
Py
Pigment
Vas. cap.
Neurites
Coll.

D 11. THE CORTEX CEREBRI.

FIG. 1. **Section of the Cortex Cerebri at Right Angles to the Surface of a Convolution** (×30).—(*a*) General view of the whole section.

The minute structure is best studied by considering successive strata or layers.

I. and II. together form the outer stratum or **molecular layer.**

Immediately beneath the surface, which is covered by pia mater, is a thin layer of medullated fibres, which runs parallel to the surface, and is well shown in Fig. 4.

A few small nerve cells and neuroglia cells occur in this layer, to which also some of the chief dendritic processes of the pyramidal cells extend.

III. The layer of **small pyramidal cells.** This is seen to be of considerable thickness, and contains large numbers of cells, such as those shown in detail in *c* and *d*.

IV. The layer of **large pyramidal cells.** The cells are larger in the deeper part of this stratum than in the upper part, and smaller cells, granule cells, are seen to lie between them.

V. Layer of **polymorphous cells.** These cells are more abundant in the sensory type of convolution.

VI. Transition to the white substance; the layer often contains numbers of irregular or fusiform cells, and is hence known as the layer of **fusiform cells.**

Between the layers II. and III. a few fibres pass parallel to the surface, for the most part collaterals from the axis-cylinder processes of the pyramidal cells; they are sometimes referred to as the *striæ of Gennari*, and are best marked in the neighbourhood of the calcarine fissure, where they are known as the *striæ of Vicq d'Azyr*.

FIG. 1*b*. **A Large Pyramidal Cell.**—Its upper part is prolonged into the chief dendritic process, or *dendron*, which gives off numerous lateral branches; from the body of the cell several smaller lateral dendrites are given off; from the base of the cell, directed towards the white matter, passes the axis-cylinder process (*the chief process of Kallius*). This process bends round at right angles into the white matter, to form either an association, commissural, or projection fibre; it gives off numerous *collaterals* in its course, both in the grey and white matter. (The complete structure, cell, dendrites, axis-cylinder, and collaterals, is sometimes referred to as a *neuron*, but this term has also been applied to the axis-cylinder process alone.)

Fig. 1*c*. **A Small Pyramidal Cell**, with a short chief-dendron, and a correspondingly longer axis-cylinder process, which bends round into the white matter.

Fig. 1*d*. **A Small Pyramidal Cell**, the axis-cylinder process of which bends round on itself and passes towards the surface. Methylene blue after Nissl. (Tuczek.)

Fig. 2. **Large Pyramidal Cell as it appears in Stained Preparations** (× **600**).—Between the nucleus and the axis-cylinder process is some pigment, the significance of which is not known. In the outer part of the cell are some masses of deeply-stained material like those shown in Plate D 1, Figs. 5 and 6. The axis-cylinder process is finer and more uniform in calibre than the various dendrites. Around each cell winds a blood capillary, a point worthy of notice, since the smaller nerve cells do not stand in so close a relation to the bloodvessels. Methylene blue. (Tuczek.)

Fig. 3. **The Arrangement of the Vessels in a Cerebral Convolution** (× **12**).—In the white matter the vessels are not numerous, and run for the most part longitudinally; in the grey matter the vessels are more numerous, many entering from the pia mater, forming a capillary network; innumerable small capillary loops surround the nerve cells, as described above. Carmine injection. (Tuczek.)

Fig. 4. **Arrangement of the Medullated Fibres in a Cerebral Convolution** (× **8**).—*c*, The white substance, consisting of medullated fibres, arranged for the most part longitudinally, and giving off small bundles of fibres which enter the grey matter and extend almost to the surface, getting smaller the nearer they get to the surface, since many of their fibres join the pyramidal cells. Near the margin, the layer of white fibres, described above (Fig. 1) as running parallel to the surface, is very distinctly seen.

In the middle of the grey matter lie rows of fibres also running parallel to the surface (*coll.*), and consisting chiefly of collaterals. Pal's method. (Tuczek.)

Fig. 5. **A Large Pyramidal Cell in Situ** (× **600**).—A number of small nerve cells, together with neuroglia and the nuclei of the capillary walls, are seen around the large cell. Nissl's method. (Tuczek.)

D 12. CORTEX CEREBRI—RESULTS OF GOLGI'S METHOD.

A peculiarity of the preparations made by the metallic reduction method of Golgi is that frequently only one kind of cell in a particular specimen shows the reaction—sometimes only the neuroglia cells, at others only one kind of nerve cell.

We have no evidence that the separate nerve cells are directly united together by their processes, or that any anastomosis takes place.

Fig. 1. **Pyramidal Cells and Neuroglia** (×70). — Only a few of the numerous fibres are shown, some being seen in cross-section, others in longer or shorter segments in the plane of the section. The bloodvessels also reduce the silver salts, and are thus marked out as dark lines; they generally have neuroglia cells in close relation to them (*cf.* Fig. 6). Golgi's method. (Tuczek.)

Fig. 2. **Cells and Fibres from the Layer of Polymorphous Cells** (×70).—A considerable number of nerve cells and a few neuroglia cells are shown. The cell indicated by the asterisk has its axis-cylinder process bent on itself, and directed upwards towards the periphery. Golgi's method. (Tuczek.)

Fig. 3. **Part of a Section through the Outer Part of a Cerebral Convolution** (×40).—The lower part of the section shows the best reduction, and the cells marked out are chiefly of the polymorphous and bipolar varieties. Golgi's method. (Tuczek.)

Fig. 4. **The Grey Matter of a Section through the Præcentral Convolution** (×60).—Golgi's method. (Sobotta.)

I. External zone with irregular precipitation.
II. Molecular layer; in this situation numerous neuroglia cells and bloodvessels are visible.
III. Layer of small pyramidal cells.
IV. Layer of large pyramidal cells.
V. Layer of polymorphous cells.

Fig. 5. **General Appearance of the Cerebral Cortex after Golgi's Method** (×20).—The outer surface is directed towards the left.

I. Molecular layer.
II. The layer of small pyramidal cells.
III. Striæ of Gennari (*cf.* Plate D 11, Fig. 1).
IV. The layer of large pyramidal cells.
V. The layer of polymorphous cells.
VI. The white centre.

A few bloodvessels passing from the surface into the deeper parts are distinguishable as dark lines. Golgi's method. (Tuczek.)

Fig. 6. **Three Neuroglia Cells** (×300).—They are seen to be closely connected with the wall of a bloodvessel by connecting processes. Golgi's method. (Tuczek.)

Fig. 1.
Fig. 2.
Fig. 3.
Fig. 4.

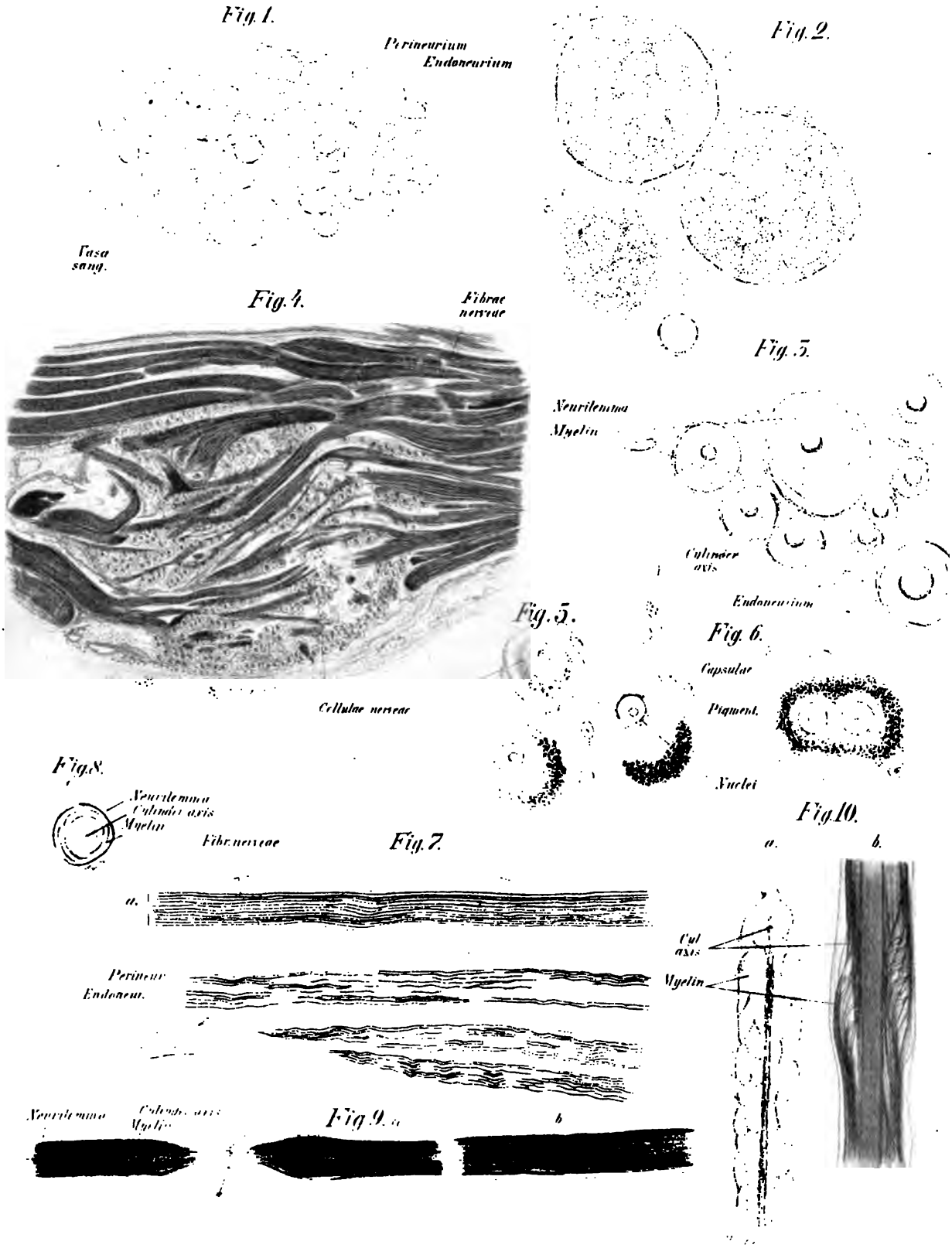
Fig. 1.
Perineurium
Endoneurium
Vasa sang.
Fig. 2.
Fig. 4.
Fibrae nerveae
Fig. 5.
Neurilemma
Myelin
Cylinder axis
Endoneurium
Fig. 5.
Fig. 6.
Capsulae
Pigment.
Nuclei
Cellulae nerveae
Fig. 8.
Neurilemma
Cylinder axis
Myelin
Fibr. nerveae
Fig. 7.
a.
Perineur.
Endoneur.
Fig. 10.
a.
b.
Cyl axis
Myelin
Neurilemma
Cylinder axis
Myelin
Fig. 9.
a
b

D 13. SYMPATHETIC AND PERIPHERAL NERVOUS SYSTEM—CELLS AND FIBRES.

FIG. 1. **Cross-section of the Sciatic Nerve** (×7).—This presents the typical structure of a nerve trunk, consisting of small bundles of nerve fibres separated by a connective-tissue sheath—the *perineurium*, which conveys the bloodvessels, lymphatics, and *nervi nervorum*. The sheath of the whole nerve is sometimes referred to as the *epineurium*.

These small bundles are also arranged in groups, which are given off from the main nerve from time to time, enclosed in their perineural sheath as smaller branches, so that in the sciatic nerve we can already distinguish the fibres which go to form the peroneal, tibial, and plantar nerves. Picrocarmine. (Tuczek.)

FIG. 2. **Four Nerve Bundles or Funiculi from the Last Specimen** (×60).—Two are large, a third is medium-sized, and between them is a very small one, consisting of only a few fibres.

The medullated fibres appear in section as circles of different sizes, and in the centre of each is the axis cylinder as a small darkly-stained point. The individual fibres are separated from one another by their own special sheath, the *neurilemma*, and by a delicate investment of connective tissue within the perineurium called the *endoneurium*. These connective-tissue sheaths give the nerve trunk its characteristic firmness, and serve to convey the bloodvessels. Picrocarmine. (Tuczek.)

FIG. 3. **Cross-section of Several Medullated Fibres** (×1200).—The fibres vary considerably in diameter; the white substance has a laminated appearance (*cf.* Figs. 9 and 10 and Plate D 3, Fig. 2). The axis cylinders also vary in size. Picrocarmine. (Tuczek.)

FIG. 4. **Section of a Spinal Ganglion** (×9).—The medullated nerve fibres pass through the ganglion in bundles arranged longitudinally; in the lower part large numbers of ganglion cells lie between the fibres. The whole ganglion has a capsule of dense connective tissue.

Each ganglion cell is unipolar, *i.e.*, has a single process which joins a nerve fibre by a T-shaped junction at a node of Ranvier; or the process may be regarded as bifurcating, one part going towards the central nervous system, the other towards the periphery. Weigert's method. (Tuczek.)

FIGS. 5 and 6. **Ganglion Cells from the Inferior Cervical Ganglion** (×250).—Each cell has a capsule composed of connective-tissue cells wrapped round it. On the right is a cell with two nuclei (not common in man). These ganglion cells give off several processes; one of these passing directly upwards is shown in the figure. The cells contain a considerable quantity of pigment granules in their protoplasm. Osmic acid. (Tuczek.)

FIG. 7. **The Fibres of a Cutaneous Nerve** (×40).—The small bundle of fibres of which the nerve is composed is surrounded by perineurium. The fibres are for the

most part very distinctly marked out, owing to the blackening of the white substance by the osmic acid.

At *a* (partly diagrammatic) the fibres are represented with their whole length in the plane of the section; the interruptions in the course of the fibres mark the situation of *Ranvier's nodes*. The perineurium contains numerous elastic fibres, and also in places a few fat cells. Osmic acid, borax carmine. (Tuczek.)

FIG. 8. **A Nerve Fibre from the Last Preparation in Transverse Section (×600).**—Examined with Winkel's system for homogeneous immersion (apochromat. 1·9 mm.). In the middle, stained red, is the axis cylinder; outside this is the white substance, presenting a very pronounced laminated appearance; the whole is enclosed by the delicate neurilemma. It is interesting to compare this with the appearance of the white sheath in longitudinal section (*cf.* Figs. 9 and 10). Osmic acid, borax carmine. (Tuczek.)

FIG. 9. **A Nerve Fibre examined from the Side (×600).**—The asterisk marks the situation of a node of Ranvier, at which the white substance is interrupted and the neurilemma slightly thickened, while the axis cylinder passes uninterruptedly through the constriction.

The white substance appears irregular and vesicular as a result of the action of reagents.

a shows the appearance when the microscope is focussed on the axis cylinder; the white substance appears laminated.

b, focussed on the white substance; the laminated appearance then appears to be the expression of a network. Osmic acid, borax carmine. (Tuczek.)

FIG. 10*a*. **A Nerve Fibre from the same Cutaneous Nerve (×1200).**—Prepared by Müller's fluid and stained with carmine.

The axis cylinder is small and shrunken; the white substance shows a corrugated or varicose structure.

FIG. 10*b*. **Nerve Fibre from Fig. 7 (×1200).**—Showing an *incisure of Lantermann* as it appears when examined with a Winkel's apochromatic system as above.

These appearances are probably the result of the action of the reagents used. Osmic acid, borax carmine. (Tuczek.)

D 14. NEUROGLIA.

FIG. 1. **Neuroglia Cells from the Olivary Nucleus of Fig. 3** (×50).—The cells are well marked at the margin of the grey matter of the nucleus, to which their fibrous processes form an investment, while only few cells are marked out in the grey matter itself. Golgi's method. (Sobotta.)

FIG. 2. **Some of the Cells more highly magnified (300).**—*a*, Cells from within the olive. *b*, Cells from the outer part.

Each cell consists of a cell body with a nucleus, and fibrous processes which can be traced right through the substance of the cell; these processes are here collected into sheaves or bundles. Golgi's method. (Sobotta.)

FIG. 3. **Cross-section of the Medulla Oblongata of a Newly-born Child** (×8).—This specimen shows the general arrangement of the neuroglia cells in the medulla oblongata; they form a supporting tissue which permeates the whole structure and they are most thickly distributed in between the two olives.

This specimen illustrates the fact previously stated, that frequently only one kind of cell is brought out by Golgi's method—in this case the neuroglia. (Sobotta.)

FIG. 4. **Diagram to illustrate the Origin and Development of Neuroglia in the Embryo (in the Spinal Cord).**—The cells lining the central canal, the *spongioblasts* of His, divide; only the part of the cell directly lining the canal retains its epithelial character; the outer part forms a meshwork, *myelospongium*, extending actually to the surface of the cord, as shown on the left side of the figure. Later the continuity of some of these fibres is broken, and neuroglia cells appear, probably derived by division of the spongioblasts, so that an appearance such as that shown on the right side of the figure is obtained.

FIG. 5. **Neuroglia Cells in the White Matter of a Cross-section of the Spinal Cord of an Adult** (×1000).—The medullated fibres are readily recognisable; lying between them, the stained nuclei of neuroglia cells can be made out, but the processes, so readily shown by the metallic method of staining, are not visible. Müller's fluid, acid carmine.

FIG. 6. **A Neuroglia Cell from Spinal Cord** (×1000).—Compared with those of the olivary body (Fig. 2), it has longer and thicker processes. Golgi's method.

FIG. 7. **Neuroglia Cells around a Pyramidal Cell of the Cortex Cerebri** (×400).—The differences between the two kinds of cells are sufficiently striking; but there are nerve cells, *e.g.*, in the molecular layer of the cerebellum, which may very closely resemble neuroglia cells in appearance.

D.14.

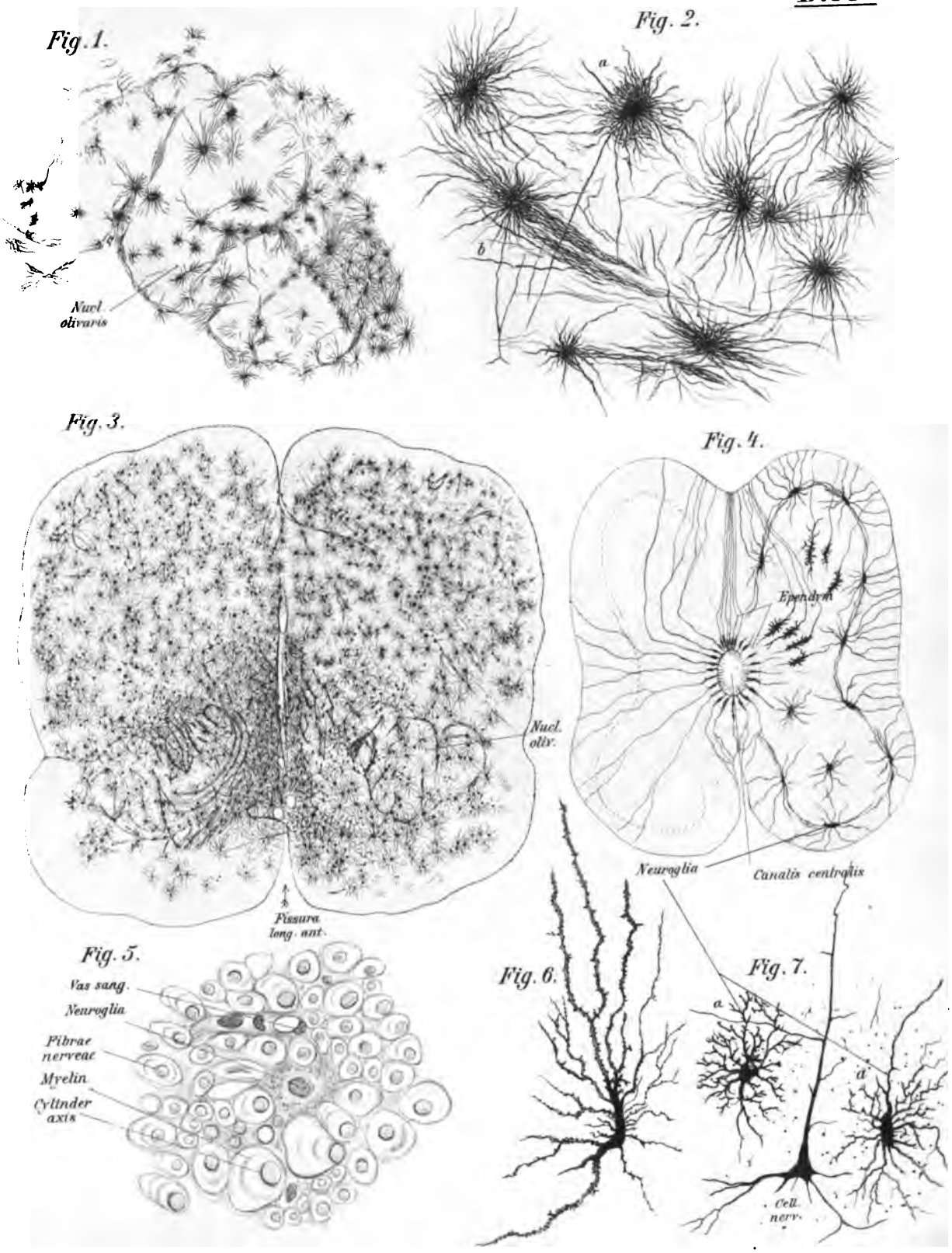

J. Brass fec.

E.—MUSCLE.

E 1. STRIATED MUSCLE—GENERAL OUTLINES: VASCULAR SUPPLY.

Fig. 1. Transverse Section of the Biceps of a Seven-Months Fœtus (×50).—The fibres are collected into bundles or *fasciculi*, which are united together by the *perimysium internum*, the external investment of the whole muscle being the *perimysium externum*, or *epimysium*.

These sheaths are composed of areolar tissue, and convey the bloodvessels and nerves to the muscle. This connective tissue also passes between the individual fibres as the *endomysium*, but it does not form a complete sheath to each fibre, as in the case of the endoneurium of a nerve. Chromic acid, alcohol, acid carmine.

Fig. 2. **Arrangement of Muscular Fibres in the Tongue of the same Fœtus (×200).**—The loose tissue between the muscular fibres is seen to consist of connective tissue fibres and cells with large nuclei.

The muscular fibres are small and not very numerous, but they show distinct oss-striation. Chromic acid, alcohol, hæmatoxylin.

Fig. 3. **Section of Injected Muscle from the Tongue of an Adult (×200).**—The fibres pear more closely packed together in comparison with those of Fig. 2 in the fœtus, rtly owing to the fact that the muscle fibres themselves have become four to six times ger in diameter.

The vessels are injected with red material, and are seen to lie in the connective ue, and consist of long capillaries arranged between the fibres, joined by shorter loops passing across them. Alcohol, hæmatoxylin.

Fig. 4. **Part of a Muscle Fibre from the Last Preparation (×400).**—The fibre shows the cross-striation distinctly, and indications of longitudinal fibrillation.

Fig. 5. **Bloodvessels of Muscle injected Blue (×60).**—Large vessels are seen crossing over the fibres, and giving off smaller branches which break up into capillaries running longitudinally between them. These are joined by the short transverse, communicating branches passing over and under the fibres (*cf.* Fig. 3). Berlin blue-gelatin injection, alcohol.

Fig. 6. **Attachment of Muscle Fibres to a Tendinous Intersection in a Seven-Months Fœtus (×250).**—The *tendon cells* are well shown lying in rows between the fibrous *tendon bundles*, and the muscle fibres are seen to become attached to the latter. Chromic acid, alcohol, acid carmine.

Fig. 7. **Part of the Last Specimen more highly magnified (650).**—The asterisk indicates the part examined. The tapering end of a muscle fibre joins on to a tendon fibre, the sarcolemma becoming continued on to the tendon bundle. The union is also assisted by the areolar tissue of the tendon becoming continuous with that between the muscle fibres.

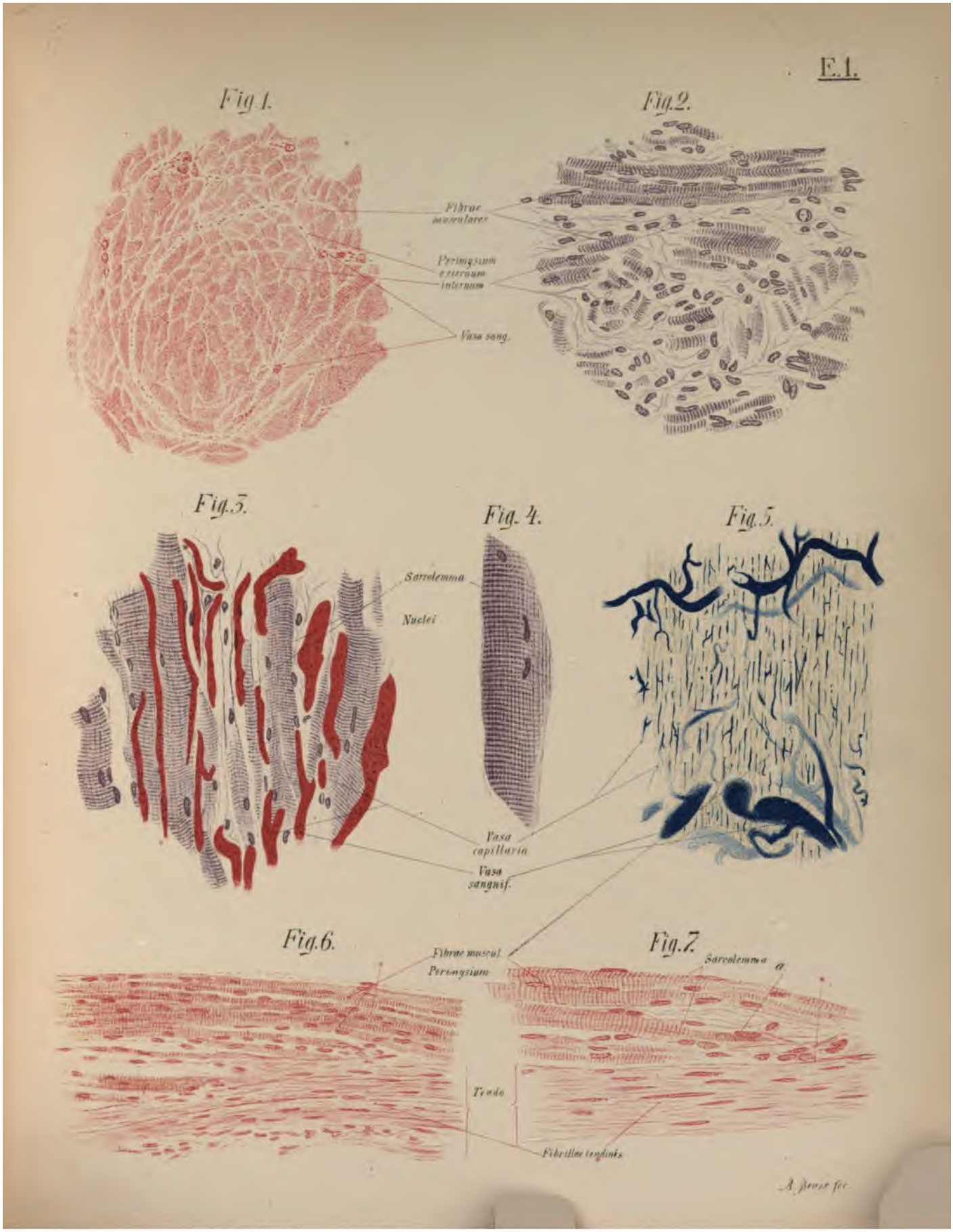
E.1.
Fig.1.
Fig.2.
Fibrae musculares
Perimysium externum
internum
Vasa sang.
Fig.3.
Fig.4.
Fig.5.
Sarcolemma
Nuclei
Vasa capillaria
Vasa sanguif.
Fig.6.
Fig.7.
Fibrae muscul.
Perimysium
Sarcolemma
a
Tendo
Fibrillae tendinis
A. Bruce fec.

E.2.

Fig. 1.

Cellulae mammularis

Subst. contractilis

Nuclei

Tela conjunct.

Fig. 2.

Fig. 3.

Fibrae mammularis

Tela conjunct.

Fig. 4.

Nuclei

Fig. 5.

Fig. 6.

a.

b.

Fig. 7.

a

b.

Sarcolemma

c.

Fibrillae

Subst. interfibrillaris

Fig. 8.

a.

b.

c

n

Fig. 9.

Nuclei

Fig. 10.

Subst. contract.

Fig. 11.

Fig. 12.

a.

b.

q

x

n

c

h

c

E 2. NON-STRIATED MUSCLE—HEART MUSCLE—DETAILS OF CROSS-STRIATED MUSCLE.

FIG. 1. **Heart Muscle Cells in Transverse Section** (×**700**).—These cells are cylindrical in shape, and are placed end to end to form fibres (*cf.* Figs. 2 and 5). The nucleus of each cell lies in the longitudinal axis, and not peripherally, as in striated muscle. Just around the nucleus is a small quantity of finely granular protoplasm, the remainder of the cell being made up of the contractile substance.

Heart muscle fibres possess no sarcolemma. Picrocarmine. (Ziemke.)

FIG. 2. **Cells from the same Preparation—Longitudinal Aspect** (×**250**).—The cells are placed end to end, and joined by intercellular substance (*cf.* Fig. 5) to form fibres, which are also united by lateral processes of the cells.

FIG. 3. **Cross-section of Non-striated Muscle Fibres from the Wall of the Stomach** (×**500**).—The fibres appear circular or oval in section; in some the nucleus is caught by the section, in others not. The fibres are joined together by intercellular material or cement substance, and in some places also by connective tissue. Flemming's solution, acid carmine. (Merkel.)

FIG. 4. **Non-striated or Plain Muscle Fibres in Longitudinal Section from the Muscular Coat of the Stomach** (×**1500**).—The nuclei are elongated and peculiarly constricted in places, an appearance presented by the nuclei of these cells in many vertebrates.

The outlines of the individual cells can only be indistinctly made out, owing to their close union with one another, but they can be separated by maceration in 20 per cent. nitric acid or 30 per cent. potash solution, which dissolves the intercellular substance. Flemming's solution, acid carmine. (Merkel.)

FIG. 5. **Heart Muscle Cells isolated** (×**500**).—The asterisks mark the intercellular material uniting the individual cells. The nucleus is oval or rod-shaped.

The cells show both longitudinal and transverse striation, the latter being less marked than that of striated or voluntary muscle.

The lateral processes are oblique; they also show the striations. Picrocarmine. (Ziemke.)

FIG. 6. **Two Muscle Fibres isolated from the Intestinal Wall** (×**750**).—The inner structural relations are for the most part disturbed by the reagents used to separate the fibres, so that the form of the cell is the chief point demonstrated. Caustic potash, ½ per cent. hydrochloric acid, acid carmine, glycerin.

FIG. 7. **Details of the Structure of the Striated Muscle of a Young Salamander Tadpole** (×**600**).

FIG. 7*a*. **Longitudinal Aspect.**—The delicate *sarcolemma* is seen enclosing the *contractile substance*; immediately beneath it is the nucleus, or *muscle corpuscle*.

The contractile substance presents alternate light and dark bands, giving the appearance of cross-striation. In addition there is a distinct longitudinal fibrillation visible; these fibrillæ are the muscle columns, or *sarcostyles*. This appearance is well shown by placing the freshly-removed, still-living muscle in hot 5 per cent. sublimate solution.

Cornea
Epithelium
Fig. 1.
Sclera

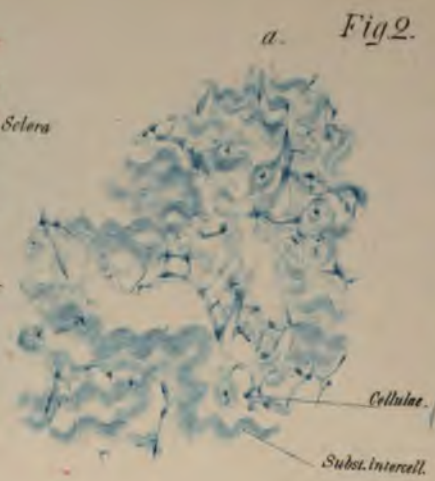
a.
Fig. 2.
Cellulae.
Subst. intercell.

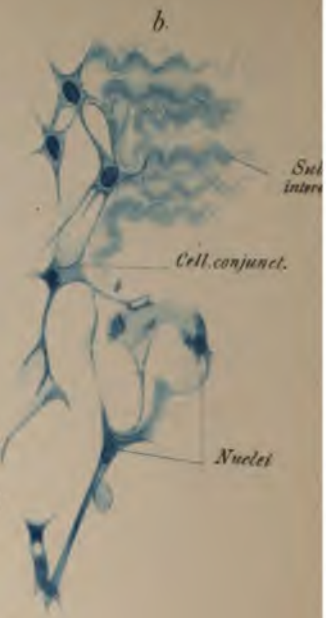
b.
Cell. conjunct.
Nuclei

Fig. 3.
Fibrae elasticae

Fig. 4.
Tela conjunctiva
Vasa sang.

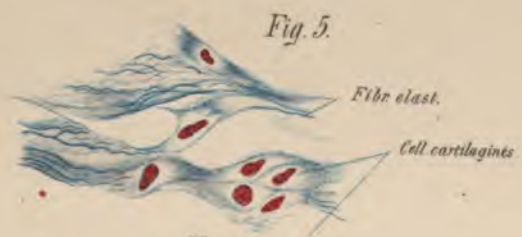
Fig. 5.
Fibr. elast.
Cell. cartilaginis

Fig. 6.

Fig. 8
Subst. intercell.

a.
Fig. 7.
b.
Nuclei
Protopl.
Subst. intercellularis

c.

A. Brau fec.

F 1. THE CONNECTIVE TISSUES. CELLS AND FIBRES.

A TYPICAL connective tissue consists of cells (*connective-tissue corpuscles*) and *fibres* (white and yellow elastic) embedded in a ground substance, or *matrix*, which may be variously modified. The different connective tissues agree in that they are all derived from the mesoblast and have a supporting function, and differ in the relative quantities of the above-mentioned elements present, and the changes which they have undergone.

FIG. 1. **Corneo-sclerotic Junction from the Eye of a Six-Months Fœtus** (×120).—Large numbers of spindle-shaped connective-tissue corpuscles are seen in the sclerotic; they are arranged irregularly, and prolonged into fine fibrils at both ends. In the cornea they are arranged in regular rows, and are known as *corneal corpuscles*. The fibres in the sclerotic are mainly white fibres, and are densely packed together, running in various directions; in the cornea they are arranged in laminæ, between which lie the rows of corneal corpuscles. Chromic acid, acid carmine.

FIG. 2. **From the Whartonian Jelly of the Umbilical Cord of a Fœtus at Term.**—This is an example of *jelly-like connective tissue*, in which the cellular and fibrous elements are reduced to a minimum, the chief constituent being the intercellular or ground substance.

FIG. 2*a*. **A Small Piece of the Tissue** (×700).—A few small connective-tissue corpuscles are seen scattered about in the intercellular substance, which appears partly in the form of wavy lines.

FIG. 2*b*. **More highly magnified (1000).**—A few stellate connective-tissue cells with long processes are seen; the ground substance, in fine wavy lines, seems to stand in very close relation to the cells and their processes. Methylene blue. (Ziemke.)

Figs. 3 and 4 illustrate the structure of *elastic tissue*, in which the yellow elastic variety of fibres are largely developed, the white fibres and connective-tissue corpuscles being present in relatively small amount.

FIG. 3. **Longitudinal Section of the Ligamentum Nuchæ** (×125).—The longitudinally arranged unstained elastic fibres are seen to be separated by white fibres and a few cells (stained red). Carmine. (Freudenstein.)

FIG. 4. **Cross-section of Ligamentum Nuchæ** (×250).—The elastic fibres appear in section as highly-refractive unstained polygonal areas, separated from one another by

loose areolar tissue (stained red), in which run large and small vessels (*vasa sang.*). Carmine. (Freudenstein.)

Figs. 5 to 8. Yellow Elastic Cartilage.—Cartilage may be regarded as connective tissue, in which the matrix has become altered in such a way as to be much firmer than in the simple connective tissues. In this variety of cartilage the matrix also possesses large numbers of yellow elastic fibres.

Fig. 5. **Cells and Fibres from the Outer Layers of a Piece of Yellow Elastic Cartilage** (×500).—The elastic fibres are stained blue; part of the cell is blue, the nucleus deep red.

Fig. 6. **Cells from near the Edge** (×500).—The fibres in the matrix are stained violet, the nuclei red, the protoplasm of the cells unstained.

Fig. 7. **Cells and Fibres from the Deeper Layers** (×250).—The cells are rounded or [illegible] ir nuclei are stained red, their protoplasm blue. The matrix contains large [illegible] of [illegible] fibre[illegible] immediately around the cells, where it is

[illegible] le Car [illegible] (×250).
[illegible] ne blue, and methyl violet.

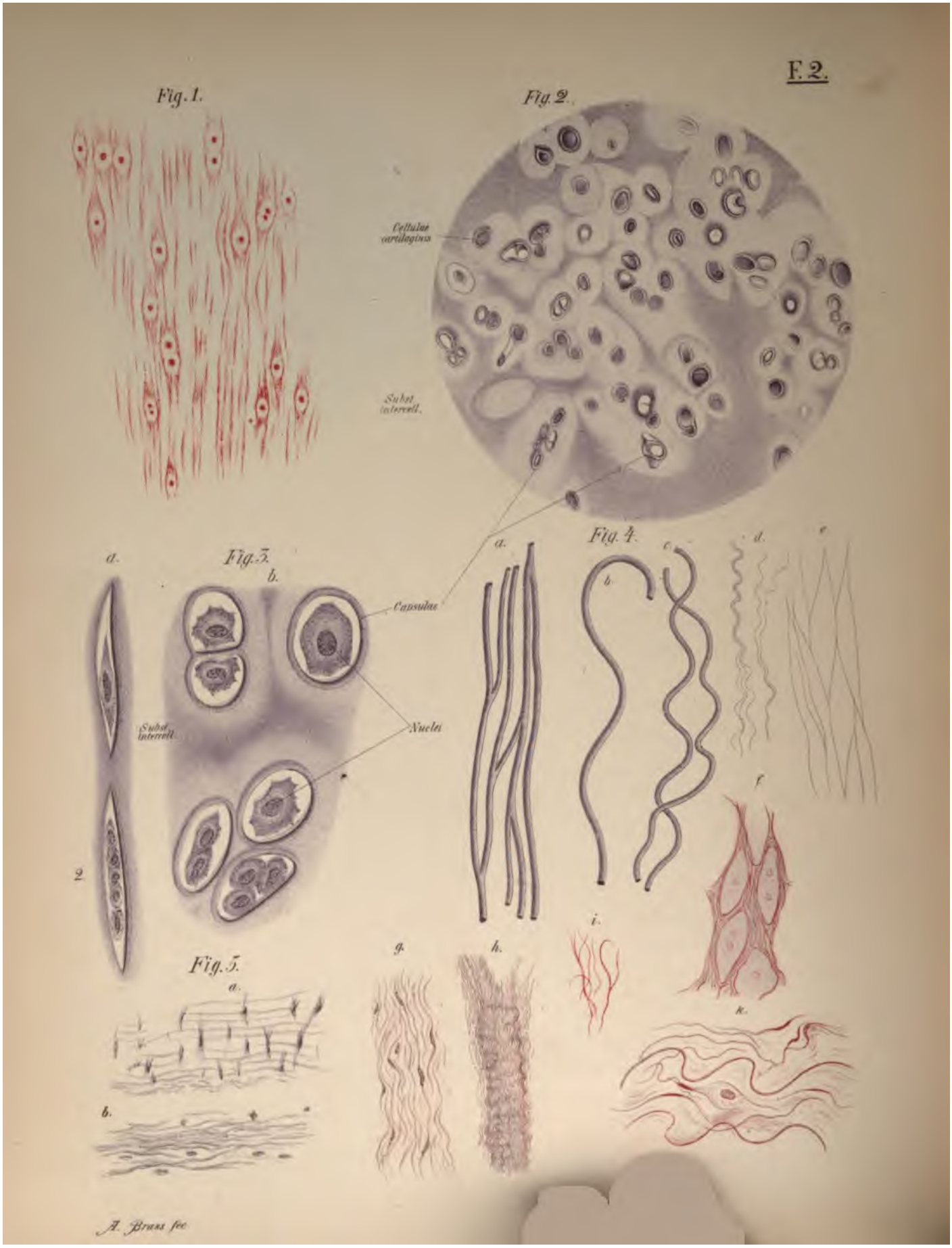
F. 2.
Fig. 1.
Fig. 2.
Cellulae cartilaginis
Subst. intercell.
Fig. 3.
a.
b.
Capsulae
Nuclei
Subst. intercell.
2
Fig. 4.
a.
b.
c.
d.
e.
f.
g.
h.
i.
k.
Fig. 5.
a.
b.
A. Brass fec.

F 2. FIBRO-CARTILAGE. HYALINE CARTILAGE. ELASTIC FIBRES.

FIG. 1. **Fibro-cartilage from an Intervertebral Disc (× 250).**—The cells are rounded, with deeply-stained nuclei, and lie in spaces, or *lacunæ*, surrounded by the matrix, which is permeated by bundles of fine white fibres arranged longitudinally, the part of the matrix immediately surrounding the cell, however, being clear and free from fibres. (Ziemke.)

FIG. 2. **Hyaline Cartilage (× 100).**—Many of the cells have dropped out, leaving the spaces, or lacunæ, in which they normally lie, empty. Each space is enclosed by a *capsule*—a specialized part of the matrix. The matrix immediately round the capsule is only faintly stained, and is probably the last produced; outside this the matrix stains more deeply, but it is quite clear and free from fibres, and in the unstained condition is either transparent, or ground-glass-like; hence the name *hyaline cartilage*. Methylene blue. (Ziemke.)

FIG. 3. **Hyaline Cartilage (articular variety) from the Head of the Femur of a Child (× 300)—*a*, Cells from the Periphery of the Cartilage.**—In the upper space lies a spindle-shaped cell (flat when seen from the surface); in the lower one five cells have arisen by division. These cells and groups of cells lie with their long axis parallel to the surface.

FIG. 3*b*. **Cells and Matrix from the Inner Part.**—The cells, which in the living condition completely fill the spaces, have retracted, so that some of them appear almost stellate. The part of the matrix immediately around the cell forms a special capsule to the cell; this is difficult to see, except in stained specimens. In some of the spaces there are two or more cells, derived by division of the original cartilage cell. They subsequently become separated, and each acquires a special capsule and becomes separated from the others by freshly-formed matrix. The commencement of this process is shown in the space above and to the left, where a capsular wall has formed between the two cells. Sublimate, methyl violet.

FIG. 4. **Various Forms of Fibres (chiefly elastic).**—*a*, Strong, thick, yellow elastic fibres, anastomosing with one another. (For transverse section, *cf.* Plate F 1, Fig. 4.)

b, *c*, Similar fibres isolated; when cut they curl at the ends.

d, Fine, wavy white fibres. (White fibres do not branch or anastomose.)

e, Network of fine elastic fibres.

f, The fibrous network of yellow elastic fibres in the ground substance of the cartilage of the external ear. The cartilage cells are large and lie in spaces, around which the fibres can be distinctly seen.

g, Fibres and connective-tissue cells from the tunica albuginea testis of the new-born child.

h, Fibrous tissue from the septum penis.

i, Elastic fibres teased from a bronchus.

k, Elastic fibres from the adventitia of a large artery from a new-born child. *a*—*e*, methyl violet; *f*—*k*, carmine.

FIG. 5. Sharpey's Perforating Fibres from a Metacarpal Bone (×150).—These consist of bundles of fibres for the most part calcified, which pass transversely or [illegible]iquely through the circumferential or peripheral lamellæ, many of them reaching [illegible] periosteum.

[illegible]e bundles of fibres are cut across obliquely; the outlines of the lamellæ can [illegible]t.

bu[illegible]en from the side. Nitric acid, methyl violet.

F. 3.
Fig. 1.
Fibr. elast.
Medulla ossium
Osteoblast.
Subst. ossium
Fig. 2.
Fibr. elasticus
Osteoblast.
Vasa sang.
Fibr. muscul.
Fibrae tendinis
Subst. ossium
Fig. 3
Cellula ossium
Medulla ossium
Cell. cartil.
Subst. ossium
Fig. 4.
cell. oss.
Osteoblast.
Fig. 5.
Capsulae
Fibr. elasticae
Osteoblast.
Cell. cartil.
c.g.
Fig. 6.
Vasa sang.
Osteoblast.
Sanguis
Medulla ossium
Endothel
Periost

F 3. DEVELOPING BONE.

FIG. 1. **Border of a Superficial Medullary Space, or Secondary Areola, from the Humerus of a Six-Months Fœtus (× 350).**—This space has been formed by the activity of the *osteoclasts* in eroding away the calcified cartilage, and is now occupied by fibres and cells derived from the *osteogenetic layer* of the periosteum; some of the fibres become calcified later to form lamellæ and Sharpey's fibres, while the cells, *osteoblasts*, become enclosed in bone to form *bone corpuscles;* this stage is seen at the left margin, where there is a layer of newly-formed bone substance, lined by a layer of osteoblasts, some of which are in process of being enclosed. Chromic acid, alcohol, acid carmine.

FIG. 2. **A Part of the Surface of the same Humerus (× 350).**—A few muscle and tendon fibres are seen below and to the left attached to the periosteum, which consists of two layers, an outer *fibrous* and an inner *osteogenetic* containing large numbers of osteoblasts, which are actively forming bone as described above.

These osteoblasts deposit a thin shell of bone around the calcified cartilage. In the upper part of the section a process from the periosteum is seen eating its way through this newly-formed shell of bone to reach the calcified cartilage.

This process consists of osteoblasts, osteoclasts, fibres (the *osteogenetic fibres*), with supporting tissue and bloodvessels (*vasa sang.*). This series of changes constitutes the *stage of irruption*. Chromic acid, alcohol, acid carmine.

FIG. 3. **Medullary Spaces from a Phalanx of a New-born Child (× 100).**—At the left of the section is an area of cartilage, the cells of which at the extreme margin are arranged irregularly, while those near the medullary spaces are arranged in longitudinal rows, the matrix between them being calcified, and the cell spaces, themselves much enlarged, forming the *primary areolæ*. As a result of the irruption of the processes of the periosteum, the calcified cartilage is absorbed, and the primary areolæ opened out to form larger spaces—*the secondary areolæ* or medullary spaces. At the same time the osteoblasts which accompany the periosteal processes begin to deposit calcareous matter on the walls of these medullary spaces, which thus become enclosed by *primary bony trabeculæ* as shown in the figure. *Medulla ossium* is the fœtal marrow filling up the newly-formed medullary space. *Cellula ossium*, the osteoblasts becoming enclosed to form bone corpuscles. Hæmatoxylin, eosin. (Ziemke.)

FIG. 4. **Cells from the Medullary Space of Fig. 1 (× 1000).**—The large oval and pear-shaped cells above are *marrow cells*, the other cells and fibres are connective-tissue elements, the cells subsequently becoming osteoblasts, the fibres osteogenetic fibres.

In the lower part of the figure three osteoblasts are seen, two being enclosed in newly-formed bone, the third nearly enclosed.

There is also a larger cell with two nuclei, but it seems to be an osteoblast, and not one of those large cells (*osteoclasts*) whose function is the absorption of the calcified cartilage, and later of the temporary bone.

FIG. 5. From a Phalanx of the Thumb of a Seven-Months Fœtus (×750).—Some cartilage cells lying in primary areolæ at the left of the section are seen to be invaded by the periosteal tissues forming the line of advancing ossification. The cartilage cells are disappearing, and their place being taken by fibres and cells from the periosteum; the latter are actively forming new bone. The commencement of the deposit of lime salts is recognised as a thin crescentic line of deeper red around these cells, or osteoblasts.

Two large giant cells, *c. g.*, stained [illegible]v, are also seen, and will probably serve absorbers or *osteoclasts*. Chromic [illegible] [illegible]hol, picrocarmine.

[illegible]. 6. Entran[illegible] esse[illegible] the Periosteum into the newly-formed Bone of [illegible]us (×[illegible] vess[illegible]om[illegible]h wider, and gives off branches, which [illegible]

depo[illegible]n [illegible] in the neighbourhood of the vessel is shown, the newl[illegible] [illegible]e being stained yellow. The vessel is seen to penetrate the layer of subperiosteal bone. Chromic acid, alcohol, picrocarmine.

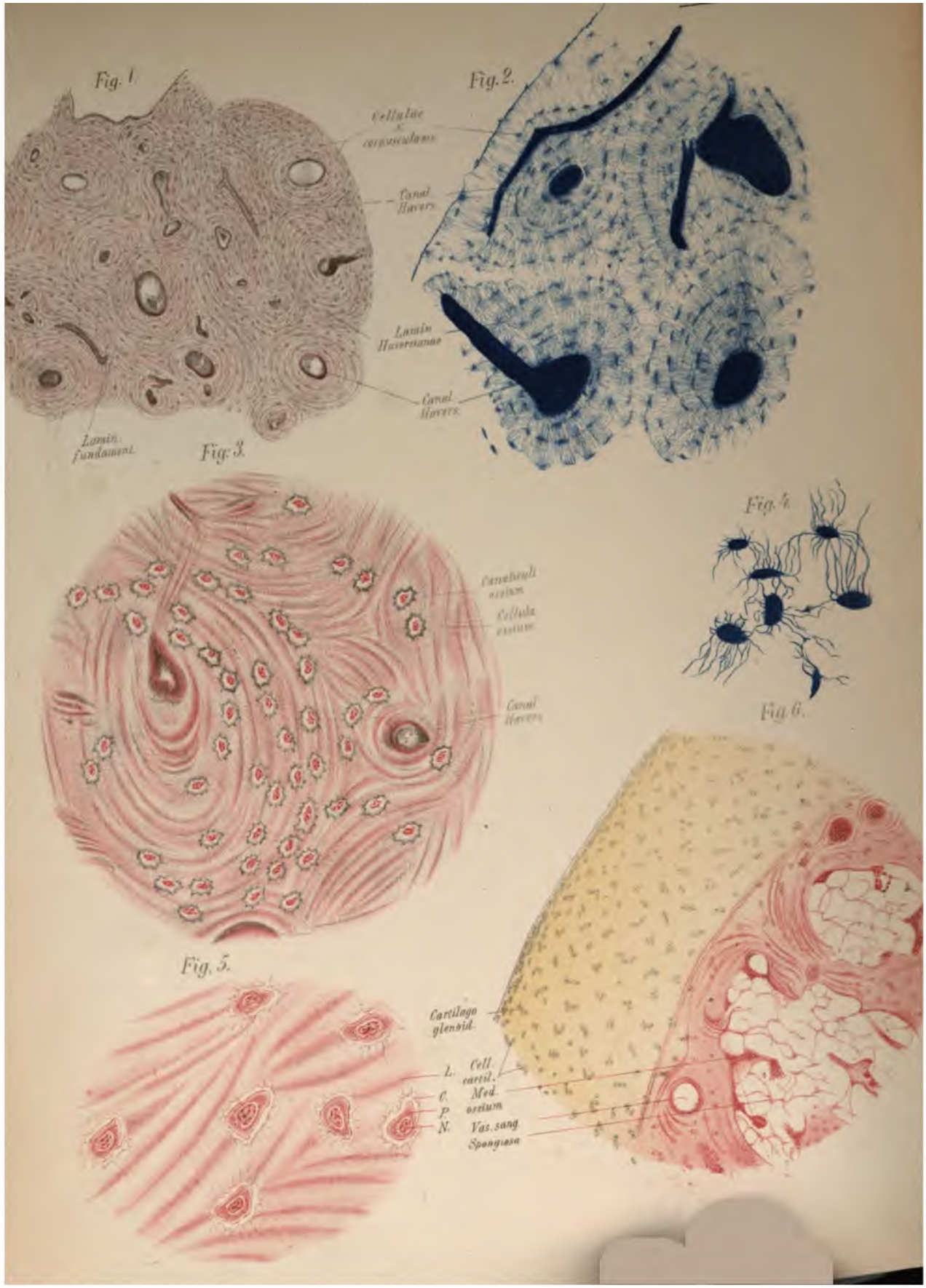
Fig. 1.
Fig. 2.
Cellulae & corpusculums
Canal Havers
Lamin Haversianae
Canal Havers
Lamin. fundament.
Fig. 3.
Canaliculi ossium
Cellula ossium
Canal Havers
Fig. 4.
Fig. 6.
Fig. 5.
Cartilago glenoid.
L.
C.
P.
N.
Cell. cartil.
Med. ossium
Vas. sang.
Spongiosa

F 4. BONE.

FIG. 1. **Transverse Section of a Long Bone (×50).**—Stained by carmine, dried, and then mounted in balsam. Part of the medullary cavity is seen in the upper part. Below this, several clear spaces of varying size are seen; these are the *Haversian canals*, in which the vessels of the bone are contained; they anastomose with one another by smaller oblique channels, some of which are seen in the section cut more or less obliquely. The bone itself is formed of calcified *lamellæ*, which have a definite arrangement as follows:

i. The greater number are arranged concentrically around the Haversian canals, and are known as *concentric or Haversian lamellæ*.

ii. Some are arranged around the medullary cavity—*perimedullary lamellæ*.

iii. Others beneath the periosteum—*subperiosteal or circumferential lamellæ* (not shown in the figure).

iv. Those filling up the spaces between the Haversian systems—*fundamental or interstitial lamellæ*. Lying between the lamellæ are the *lacunæ*, or the spaces occupied by the bone corpuscles.

FIG. 2. **Transverse Section of a Bone (×200).**—All the spaces in the bony structure have been filled with methylene blue solution. The Haversian canals and their communications are shown. Lying between the lamellæ, the *lacunæ* or spaces are seen in concentric rings; from these lacunæ radiate innumerable small channels—*canaliculi*, by which the bone corpuscles can derive nutriment from the vessels of the Haversian systems. The arrangement of these canaliculi can readily be made out. (Zeroni.)

FIG. 3. **Transverse Section of Decalcified Bone (×500)** (lateral illumination, and most of the light cut off).—Presents very similar characters to Fig. 2, but the lacunæ are occupied by bone corpuscles, each with its nucleus deeply stained. From the lacunæ fine canaliculi pass to neighbouring cells, and finally to the Haversian canals.

The bone corpuscles give off fine processes along these canaliculi. The Haversian canals are occupied by bloodvessels, nerves, and lymphatics. Carmine. (Ziemke.)

FIG. 4. **Seven Lacunæ from Fig. 2 (×500).**—By means of the higher magnification, the relation of the canaliculi of the different lacunæ to one another can be made out.

FIG. 5. **Bone Corpuscles from Fig. 3 examined by Transmitted Light and under a Higher Power (×1000).**—Carmine. (Ziemke.)

L, A bony lamella.
C, The border or capsule of the lacuna.
P, The cell substance.
N, Nucleus.

FIG. 6. **Cancellous Bony Tissue from a Metacarpal Bone, with its Articular Cartilage** (×70).—The cartilage is stained yellow, and shows the arrangement of its cells characteristic of articular cartilage, the superficial cells being parallel to the surface, the deeper ones scattered irregularly, the deepest being, as a rule, at right angles to the surface. Beneath the cartilage is a layer of compact bone, and internal to this the spongy bone, consisting of a network of fine bony trabeculæ filled up with bone marrow. Picrocarmine. (Ziemke.)

G.—ORGANS OF DIGESTION.

G 1

Fig. 1.

Fig. 3

Fig. 4.

Fig. 2

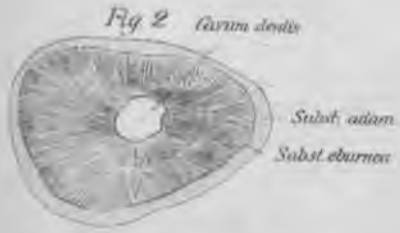

Fig. 5.

Fig. 9.

Fig. 6.

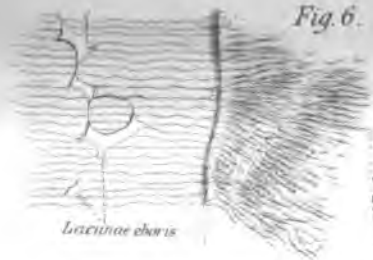

Fig. 7.

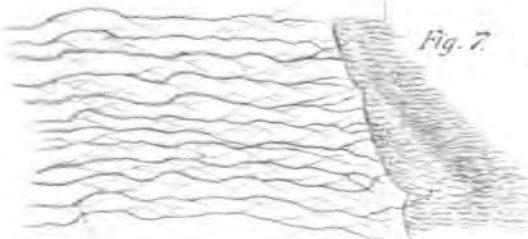

Fig. 8

Fig. 10.

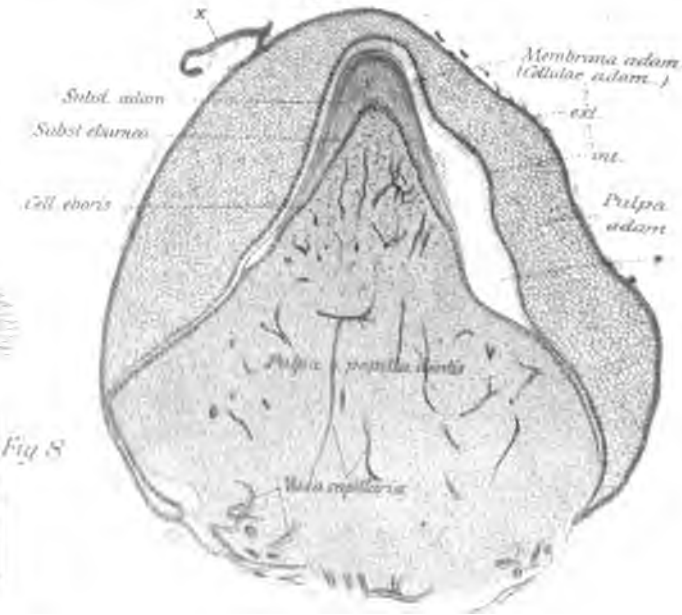

G 1. STRUCTURE OF TOOTH. DEVELOPMENT OF TOOTH.

FIG. 1. **Thin Section of a Lower Biscuspid, in situ** (×4).—The tooth is divided into three parts—the *crown*, or that part projecting into the mouth; the *neck*, the narrower part connecting the crown to the *root* or *fang*, the part embedded in the jaw.

A large irregular cavity is seen in the middle of the tooth, the *pulp cavity* (*cavum dentis*). The crown is seen to be covered by a layer of *enamel* (*subst. adamant.*), which thins off down to the neck, and forms a cap for the *dentine* (*subst. eburnea*), which forms the main part of the tooth structure. The dentine of the root is encased in a thin layer of bone—the *cement*, or crusta petrosa.

The root is united to the jaw by a very vascular structure, the *ligamentum circulare*. (Waldeyer.)

NOTE.—In Figs. 1 to 8 the various layers are indicated by slightly different tints, for the sake of clearness. The actual specimens do not show these different colours.

FIG. 2. **Cross-section of the Crown of a Canine Tooth** (×5).—The pulp cavity in the dentine, and the layer of dense enamel enclosing the latter, are shown. (Waldeyer.)

FIG. 3. **The Transition from the Crown to the Neck of Fig. 1** (×30).—The enamel faintly blue, the dentine grey, and the cement yellow. (Waldeyer.)

FIG. 4. **Part of the Enamel more highly magnified** (×100).—Showing the arrangement of the *enamel prisms*, which are here nearly horizontal. They are closely packed together and exhibit transverse markings, which are due to small curves or inequalities in thickness. Each prism extends through the whole thickness of the enamel (*cf.* Plate G 2, Fig. 10). (Waldeyer.)

FIG. 5. **Section of Dentine** (×500), showing the *dentinal tubules* cut across in various directions. (Waldeyer.)

FIG. 6. **Junction of Enamel and Dentine** (×100).—The dentinal tubules extend right up to the enamel; the part of the dentine in this situation is known as the *interglobular layer*, in which are small spaces—the *interglobular spaces* (*lacunæ eboris*) bounded by irregular lines. Some of the dentinal tubules communicate with these spaces. (Waldeyer.)

FIG. 7.—**Arrangement of the Dentinal Tubules at the Junction of Dentine and Enamel** (×240).—The dentinal tubules are seen to pass as fine parallel curving tubules to the enamel, a few of them even penetrating into it. Their inner ends open into the pulp cavity (not shown in the figure). They give off laterally very fine branching secondary tubules, which often anastomose with one another. (Waldeyer.)

FIG. 8. **Junction of Dentine and Cement** (×200).—In the dentine are seen the

dentinal tubules and interglobular spaces (more numerous in this situation than beneath the enamel); in the cement, bone lacunæ and canaliculi, but no Haversian canals, are present. All these spaces in a dried specimen like the present contain air, and therefore appear black. (Waldeyer.)

FIG. 9. **Section through the Lower Jaw of a Seven-Months Fœtus** (×7).—The tooth rudiment occupies a depression in the jaw (stained red), but is separated from the jaw itself by a strong connective-tissue capsule—the *tooth sac*. The epithelium of the mouth is seen above as a thin blue line, from which another line passes downwards to the enamel organ, along which the cells forming the enamel organ grew; and given off to the left of this is a small process—the enamel germ of the permanent tooth (*cf.* Plate G 2, Fig. 5). Hæmatoxylin, eosin. (Sobotta.)

FIG. 10. **The Tooth Rudiment of the Last Preparation** (×30).—At the spot marked * the enamel organ has become separated during the preparation; normally it is in contact everywhere with the dentine germ.

It forms a closed sac, and is developed as an invagination of the epithelium of the mouth, the communication or neck being subsequently thinned down to the line referred to in Fig. 9, and from which the *enamel germ of the permanent tooth, x*, is given off. The body of the enamel organ at first forms a flask-shaped mass of cells, and is itself invaginated by the *dentine germ*, derived from the mesoblastic tissue of the jaw.

The enamel organ in the figure is seen to consist of three layers: an inner and outer layer of enamel epithelium, between which is a jelly-like tissue composed of stellate cells constituting the *enamel pulp*. The enamel organ, like the epithelium from which it is derived, has no bloodvessels, and the enamel in the fully-formed condition has likewise no vascular supply.

It is the inner layer of epithelial cells which forms the enamel; they are known as *enamel cells* or *adamantoblasts*.

The vascular connective tissue of the papilla, which subsequently forms the pulp of the tooth, is at present very wide at the base, the root of the tooth being so far not formed. The most superficial cells of the papilla constitute a layer of dentine-forming cells—*odontoblasts*. Hæmatoxylin, eosin. (Sobotta.)

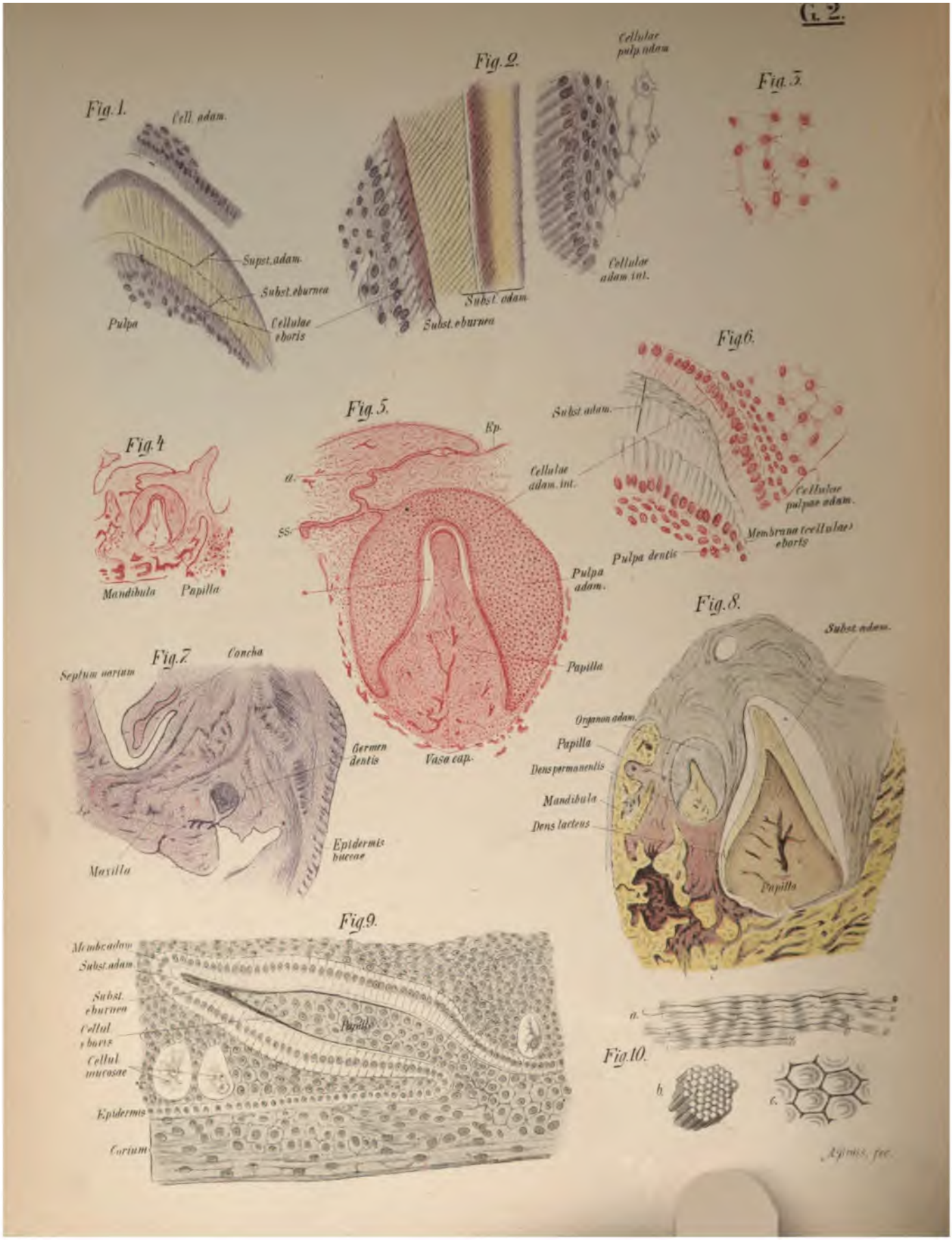
G. 2.
Fig. 1.
Cell. adam.
Supst. adam.
Subst. eburnea
Pulpa
Cellulae eboris
Fig. 2.
Cellulae pulp. adam
Subst. adam.
Subst. eburnea
Cellulae adam. int.
Fig. 3.
Fig. 4
Mandibula
Papilla
Fig. 5.
Ep.
a.
ss.
Cellulae adam. int.
Pulpa adam.
Papilla
Vasa cap.
Fig. 6.
Subst. adam.
Cellulae pulpae adam.
Membrana (cellulae) eboris
Pulpa dentis
Fig. 7.
Septum narium
Concha
Germen dentis
Epidermis buccae
Maxilla
Fig. 8.
Subst. adam.
Organon adam.
Papilla
Dens permanentis
Mandibula
Dens lacteus
Papilla
Fig. 9.
Membr. adam.
Subst. adam.
Subst. eburnea
Cellul. eboris
Cellul. mucosae
Epidermis
Corium
Papilla
Fig. 10.
a.
b.
c.
Aspinis, fec.

G 2. DEVELOPMENT OF TOOTH (continued).

FIGS. 1, 2. **Details of the Tooth-forming Structures.**

FIG. 1. **Apex of the Tooth Papilla of a Seven-Months Fœtus** (×150).—The epithelium of the enamel organ, or layer of enamel cells (*cell. adam.*), has separated from the newly formed enamel, with which it is normally in contact.

The enamel shows an outer and an inner zone, the former being incompletely differentiated. Beneath the enamel is a thin layer of dentine, formed by the layer of odontoblasts (*cell. eboris*) covering the tooth papilla. Hæmatoxylin. (Sobotta.)

FIG. 2. **Odontoblasts and Enamel Cells** (×250) (from the specimen of Plate G 1, Figs. 9 and 10).—On the left of the section is a part of the tooth pulp, which is covered by a layer of columnar cells, the *odontoblasts* (like an epithelium in appearance, though they are mesoblastic in origin); small processes of these cells, become enclosed in the dentinal tubules as *fibres of Tomes*.

The newly-formed dentine is seen to consist of two layers, the inner being incompletely calcified (the outer part is in the figure wrongly bracketed with the enamel).

Outside the enamel the cells composing the inner part of the enamel organ are seen, and comprise a layer of closely-set epithelial cells, the *enamel cells* or adamantoblasts, a layer of irregular cells (several deep), the *stratum intermedium* of Hannover, and then the branching stellate cells of the *enamel pulp*. Hæmatoxylin, eosin. (Sobotta.)

FIG. 3. **Cells from the Enamel Pulp of a Younger Fœtus** (*cf.* Fig. 5).—Each cell gives off branches which join to form a network; the nucleus is large and rounded. It is important to remember that these cells are epithelial in origin, like the enamel cells themselves. Carmine. (Sobotta.)

FIG. 4. **Section through the Tooth Rudiment of a Lower Incisor of a Four-Months Fœtus** (×15).—The tooth lies in a depression in the developing jaw, and presents similar characters to Plate G 1, Fig. 9, except that the various structures are less advanced in development. Carmine. (Sobotta.)

FIG. 5. **Part of the same more highly magnified (45).** — *Ep.*, epithelium of the mucous membrane of the mouth; a fold or thin track of these cells is seen to pass to the enamel organ, of which it forms the *neck*, *a*; this was originally much wider. At *ss* a process from the neck is seen in section, which has a wider blunt end, and is the rudiment of the enamel germ of the permanent tooth.

FIG. 6. **Apex of the Papilla from the same Specimen (×450).**—The details are as in Fig. 2.

FIG. 7. **Section through the Nasal Cavity, Upper Jaw, and Cheek of a Three-Months Fœtus (×15).**—A tooth rudiment (*germen dentis*) is shown, and the developing bony tissue is stained red. Hæmatoxylin. (Sobotta.)

FIG. 8. **Section of a Milk Tooth and a Permanent Tooth Rudiment, in situ (×15).**—They lie beside one another in a sinus in the developing jaw (stained yellow). The milk tooth (*dens lacteus*) is in a more advanced stage of development than the permanent tooth. (Waldeyer.)

FIG. 9. **Formation of a Cutaneous Tooth in a Selachian Embryo (Shark), after Hertwig.***—In this case the origin of the different layers of the tooth can be readily followed. The enamel organ is formed as a projection forwards of the deep layer of the epidermis, and the papilla from the corium follows it. The layers are then formed as above. The large cells in the epidermis are mucous cells.

FIG. 10. **Elements of the Enamel from a fully-developed Tooth.**—*a*, A small piece of enamel, with the enamel prisms seen in profile (×240). They are seen to be wavy or curved, and to present darker transverse markings.

b, A few enamel prisms seen from the side (×240).

c, A few prisms in transverse section (×750).

The hexagonal outlines of the prisms, which are solid, are shown, and their union to one another by cement substance.

* O. Hertwig, 'Lehrbuch der Entwickelungsgeschichte des Menschen und der Wirbelthiere,' Fig. 170.

Fig. 1.

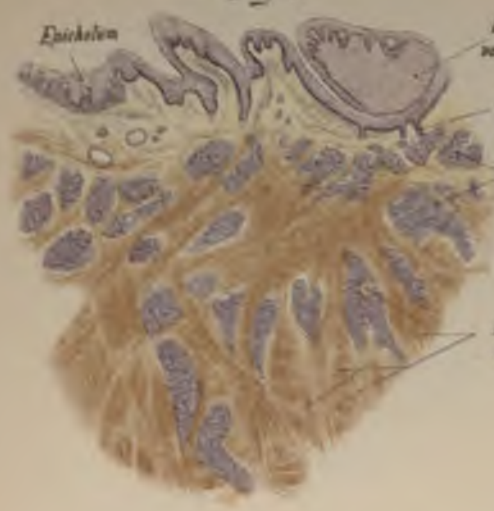

Fig. 2.

Fig. 3.

Fig. 4.

Fig. 7.

Fig. 6.

G 3. TONGUE.

FIG. 1. **Section through the Region of a Papilla Circumvallata** (×15).—The papilla itself is cut obliquely, so that in its lower part the epithelium of the trench is again caught in the section, and appears to separate the papilla from the remainder of the mucous membrane. Distinct secondary papillæ are seen on the surface of the main papilla. Opening into the trench are the ducts of small serous glands (*v. Ebner's glands*). The acini of these glands, and the epithelium of the mucous membrane, are stained violet, the bundles of muscle-fibres yellowish-brown. Hæmatoxylin. (Flemming.)

FIG. 2. **Section through a Part of the Tongue** (×15).—The epithelium is thick and stratified, the deepest layers being more deeply stained, and resting on a basement membrane, beneath which is a layer of subepithelial connective tissue. The muscle fibres are arranged in bundles stained reddish-brown, and are seen both in longitudinal and transverse section. Lying between these muscle bundles are the acini of mucous glands, the ducts of which pass upwards to open on to the surface (*ductus excret.*). Alcohol, alum-carmine. (Flemming.)

FIG. 3*a*. **Glands (v. Ebner's) from Fig. 1 more highly magnified (300).—Section through a Few Acini of the Glands.**—They are separated from one another by connective tissue. Each consists of a basement membrane, or *membrana propria*, lined by a layer of cells more or less cubical in shape. These cells stain readily, possess large rounded nuclei and finely granular protoplasm, which does not swell up as in the case of mucous glands (*cf.* Fig. 5).

FIG. 3*b*. **Section through one of the Ducts** (×300).—The cells are more regular and columnar in shape, and the lumen is larger than that of an acinus. Hæmatoxylin. (Flemming.)

FIG. 4. **General View of the Duct of a Mucous Gland from the Tongue** (×75).—The acini are about the size of fat cells, but their margins are more distinct. The duct is seen to take origin from the acini, and wind upwards through the connective tissue to the epithelium, where its walls become much thicker. Alcohol, alum carmine. (Flemming.)

FIG. 5. **Acini of a Mucous Gland from the Tongue** (×300).—The figure was drawn

from some mucous glands in the specimen of Fig. 1, near to v. Ebner's glands, but not shown in that figure.

The acini are lined by cells, which do not stain, since the protoplasm is distended with a non-staining material, mucin. The nuclei are small and flattened, and lie near the outer part of the cells. The duct is small, and lined by a single layer of flattened epithelium. Hæmatoxylin. (Flemming.)

Fig. 6. **Cells from the Glands represented in Figs. 2 and 4 (× 300).**—To the right are some acini in transverse section; the inner part of the cells is indistinct and unstained, being swollen out with mucin; the outer part contains the nucleus, and stains more readily. To the left are some acini in longitudinal section, and in the middle the duct, *D. E.* Alum carmine. (Flemming.)

Fig. 7. **Horizontal Section of a Circumvallate Papilla near the Deepest Part of the Furrow (× 15).**—In the two layers of epithelium, between which is the furrow, are seen several taste-buds as small clear spaces (*calyces gustus*).

Lying external to the papilla are v. Ebner's glands in section. Carmine. (Waldeyer.)

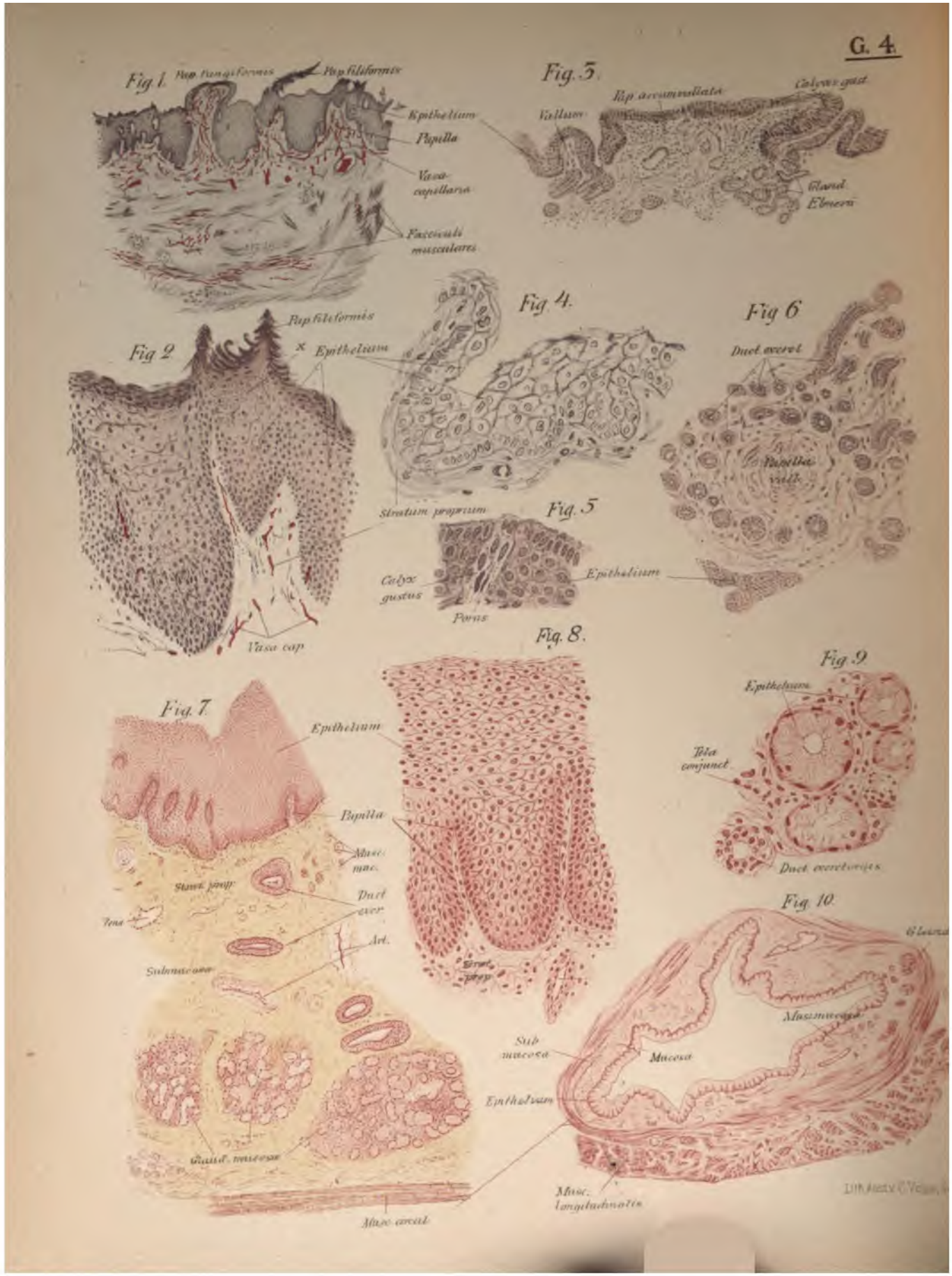
G. 4.
Fig. 1.
Pap. fungiformis
Pap. filiformis
Epithelium
Papilla
Vasa capillaria
Fasciculi musculares
Fig. 3.
Vallum
Pap. accumvallata
Calyx gust.
Gland. Ebneri
Fig. 2
Pap. filiformis
Epithelium
Stratum proprium
Vasa cap.
Fig. 4.
Fig. 5
Calyx gustus
Poras
Epithelium
Fig. 6
Duct. excret.
Papilla vall.
Fig. 7.
Epithelium
Papilla
Musc. muc.
Stratum prop.
Duct. excr.
Tela
Art.
Submucosa
Gland. mucosa
Musc. circul.
Fig. 8.
Stratum prop.
Fig. 9.
Epithelium
Tela conjunct.
Duct. excretorius
Fig. 10.
Gland.
Musc. mucosa
Sub mucosa
Mucosa
Epithelium
Musc. longitudinalis

G 4. TONGUE (continued). ŒSOPHAGUS.

FIG. 1. **Section through Fungiform and Filiform Papillæ of the Tongue (×18).**—The *fungiform papilla* is a blunt projection of the mucous membrane, possessing also secondary papillæ. It is seen to be occupied by connective tissue and bloodvessels from the subepithelial layer. The *filiform papilla* has a thick epithelial covering, which is prolonged upwards to a point, the upper part being made up of hard epithelial scales here arranged in an imbricated manner.

The vessels injected red, the tissues stained hæmatoxylin. (Reichenbach.)

FIG. 2. **Epithelium of the Mucous Membrane of the Tongue (×150).**—Two filiform papillæ are caught near their edges, so as not to be completely in view. The most superficial cells are flat, and more or less horny. On the filiform papillæ these cells form irregular spiny projections, giving the papillæ a rough appearance. The cells beneath these, as at *x*, are less flattened and have granular protoplasm; the deepest layers of cells are protoplasmic and stain readily; but the outlines of the individual cells cannot be well made out in this specimen. The deepest layer of all rests on the basement membrane. Injected with carmine-gelatin injection mass; stained hæmatoxylin. (Reichenbach.)

FIG. 3. **Section of a Circumvallate Papilla from a Seven-Months Fœtus (×60).**—The papilla with the trench around it is already well developed, and the epithelium at the sides of the trench contains taste-buds; v. Ebner's glands are also present. Chromic acid and alcohol, hæmatoxylin.

FIG. 4. **Part of the Mucous Membrane from the Outer Wall or Vallum of the Papilla shown in Fig. 3 (×400).**—The most deeply placed cells are narrow, closely packed together, and rest on the basement membrane (*stratum proprium*); the outer layers become flatter and flatter as we approach the surface, and ultimately become squamous. Chromic acid and alcohol, hæmatoxylin.

FIG. 5. **A Taste-Goblet from the same Preparation as Fig. 3 (×400).**—The basement membrane lies above; the taste-goblet appears as an oval-shaped clearer space extending from the basement membrane to the gustatory pore (*porus*). The cells of which it is composed possess large oval nuclei (*cf.* Plate C 1, Figs. 8-11).

FIG. 6. **Horizontal Section just below the Base of a Circumvallate Papilla from a Seven-Months Fœtus (×60).**—The connective-tissue basis of the papilla is seen in the middle, and around it are two rows of small circular spaces, the ducts of v. Ebner's glands as they pass to open into the trench beside the papilla.

At a later stage the ducts are more widely separated owing to the growth in size of the papilla. Chromic acid and alcohol, hæmatoxylin.

FIG. 7. **Section through the Mucous Membrane and the Submucous Tissue of the Œsophagus** (×53).—The epithelium is seen to form a thick layer many cells deep (*cf.* Fig. 8), and beneath it is the submucous coat, consisting of connective tissue, with bloodvessels (*art.* and *vena*) running in it. In the lower part lie the acini of a mucous gland, its duct being seen in section four times as it passes from the gland to the surface.

A few fibres of the inner or circular layer of muscle are also represented; they are seen to be of the striated or voluntary variety. Alum carmine. (Flemming.)

FIG. 8. **The Epithelium of the Mucous Membrane of the Œsophagus** (×300).—Two long narrow papillæ are shown, with their connective-tissue basis. The epithelium is seen to be stratified, the deepest cells, those resting on the basement membrane, being narrow, more or less columnar, and staining deeply; the cells gradually become more flat and less stained, the most superficial being flattened squamous cells. Alum carmine. (Flemming.)

FIG. 9. **Acini and Duct of a Mucous Gland from the Œsophagus in Cross-section** (×300).—They present similar characters to those of Plate G 3, Figs. 5, 6. Alum carmine. (Flemming.)

FIG. 10. **Cross-section of the Œsophagus** (×6).—The mucous membrane and submucous tissue are complete; the muscular layers are only represented in the lower half.

The mucous membrane is thrown into folds. The muscular coat is double, consisting of an internal layer of circular fibres, an external layer of longitudinal fibres.

In the upper part of the œsophagus these fibres are striated, as shown in the figure. Carmine. (Waldeyer.)

G 5. STOMACH.

FIG. 1. **Transverse Section of the Fundus Region of the Stomach** (×12).—The mucous membrane, submucous coat, and muscular coat are shown, together with the peritoneal investment or serous coat.

The brownish coloration of the specimen is the result of the action of osmic acid, which has also stained the fat cells black.

The mucous membrane presents numerous glands in section, and the submucous coat contains some large vessels. The muscular coat, with its layers, oblique, circular, and longitudinal, is much contracted. Flemming's solution, acid carmine. (Merkel.)

FIG. 2. **A Small Piece of Mucous Membrane from the same Specimen** (×80).—The mucous membrane is lined by a single layer of columnar epithelium with numerous goblet cells. Small tubular depressions—gland tubules—are seen, some being cut across transversely or obliquely in the deeper parts of the mucous membrane. Beneath the glands is a thin layer of muscle—the *muscularis mucosæ*; lying just above this is a small lymphoid nodule in close relation to the lymphatics in the upper part of the submucous coat, which also presents bloodvessels and a few fat cells in a bed of connective tissue. (*Cf.* also G 6, Fig. 4, for the arrangement of the glands in this region.)

FIG. 3. **The End of a Cardiac or Fundus Gland from the Stomach, taken Twenty Hours after Death** (×400).—The specimen presents a condition of partial digestion, the cells being indistinct and granular-looking, the nuclei not well defined; several goblet cells are shown, but their structure is indistinct. (*Cf.* the condition in Plate G 6, Figs. 1, 2.) Hæmatoxylin.

FIG. 4. **Longitudinal Section of the Pyloric Region of the Stomach** (×12).—The mucous membrane is thicker and much richer in lymphoid tissue than that of the cardiac region; several small nodules are seen lying just below the glands. Müller's fluid, acid carmine. (Merkel.)

FIG. 5. **Part of the Mucous Membrane of the same Preparation** (×80).—On comparison with Fig. 2 and Plate G 6, Fig. 4, the glands in this region, called *pyloric glands*, are seen to differ from those of the fundus region (*cardiac* or *fundus glands*) in the following points:

> The ducts are longer and wider, the gland tubules shorter and branched, and lined by one kind of cell only (the *chief* or *peptic cells*), whereas the cardiac glands contain two kinds.

The more deeply-stained cells in this specimen are goblet cells.

FIG. 6. **Goblet Cells from the Mucous Membrane of the Pyloric Region** (×1500).—*a*, Goblet cell swollen out with mucin in its outer part, the deeper part being still protoplasmic and containing the nucleus.

b, A cell in process of evacuation of its contents.

A leucocyte is seen between two of the epithelial cells. (*Cf.* Plate G 12, Fig. 8, *a*—*f*.) Müller's fluid, hæmatoxylin. (Merkel.)

Fig. 1.

Fig. 2.

Fig. 3.

Fig. 4.

Fig. 5.

Fig. 6.

A. Brass fec.

Fig. 1.

Fig. 2.

Fig. 3.

Fig. 4.

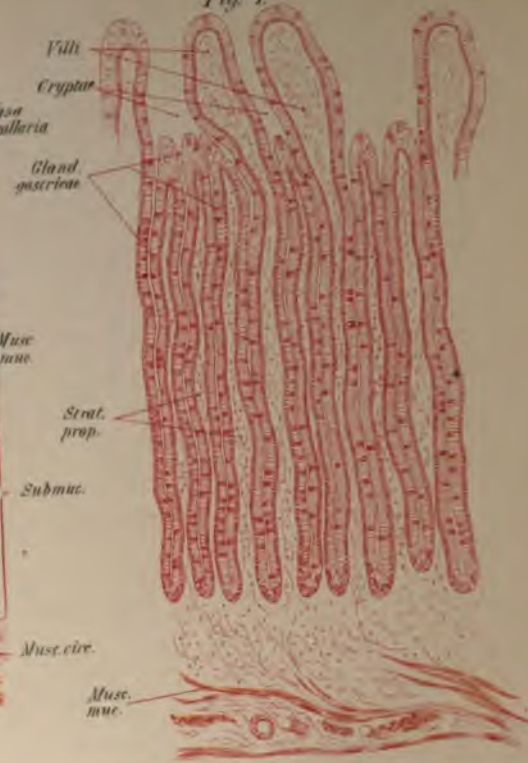

Fig. 5.

Fig. 6.

Fig. 7.

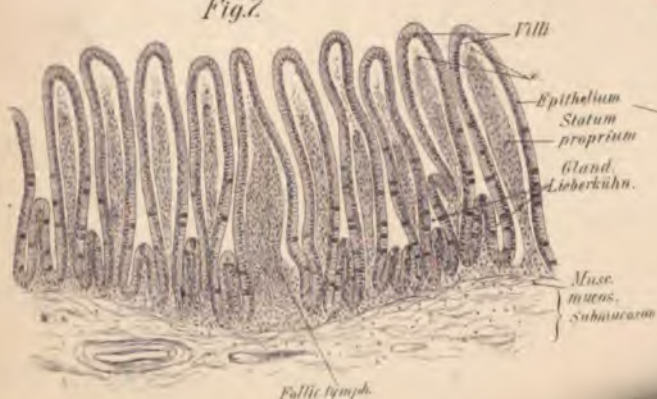

Fig. 8.

A. Brass fec.

G 6. STOMACH (continued). DUODENUM.

FIG. 1. **Transverse Section of the Ends of some Fundus or Cardiac Glands from the Specimen shown in Plate G 5, Figs. 1 and 2 (× 350).**—The tubules are seen to consist of a basement membrane, or *membrana propria*, lined by a layer of glandular epithelium (the *central* or *peptic cells*); in places between the bases of these cells and the basement membrane are larger, more darkly-stained cells, *b* (the *parietal* or *oxyntic cells*).

These cells are most numerous in the upper part of the gland tubules, and may cause the basement membrane to bulge, as in the tubule below and to the left. Flemming's solution, acid carmine. (Merkel.)

FIG. 2. **Longitudinal Section of the Ends of two Cardiac Glands (× 350).**—The relation of the parietal cells, *b*, to the basement membrane is again shown. Hæmatoxylin.

FIG. 3. **Cardiac End of the Stomach injected (× 50).**—The larger vessels run chiefly in the submucous coat, and give off branches, which pass through the muscularis mucosæ and break up into a capillary network with long meshes between the gland tubules; just beneath the surface, around the ducts of the glands, is a closer-meshed network, from which the veins arise.

The muscular coat is supplied by branches given off by the main arteries in their passage to the submucous coat. Carmine. (Reichenbach.)

The vessels were injected with a Berlin-blue gelatin injection-mass, by which method, in the case of the human stomach, the lymph channels often become injected in places, so that the injection is seldom very sharply defined.

FIG. 4. **Section of the Mucous Membrane of the Stomach, Cardiac Region (× 100).**—The mucous membrane is relaxed; it was taken from a body twenty hours after death. The section shows the arrangement of the cardiac glands. The ducts are short, and several gland tubules may open into one duct. The gland tubules themselves are unbranched and more or less parallel. Alcohol, carmine.

NOTE.—The projections of mucous membrane between the ducts are in the figure wrongly marked '*Villi*.' True villi occur only in the small intestine.

FIG. 5. **Section of the Duodenum (× 15).**—A few villi are seen projecting from the mucous membrane, and beneath it, chiefly in the submucous coat, are *Brunner's glands*.

The muscular coat is in this section much drawn up, and appears very thick. From a body some time after death. Carmine. (Freudenstein.)

FIG. 6. **The Mucous Membrane and Part of the Submucous Coat of the Last Specimen** (×500).—At the base of the villi are seen a few tubular depressions (the *follicles* or *glands of Lieberkühn*. The majority of the Brunner's glands lie in the submucous coat, below the muscularis mucosæ. The gland tubules are seen for the most part in transverse section, owing to their being coiled; in structure they resemble the pyloric glands of the stomach.

FIG. 7. **Mucous Membrane of the Duodenum, taken shortly after Death** (×60).—The villi are closely packed together, and from their bases Lieberkühn's follicles are seen to descend nearly to the submucous coat. There are no Brunner's glands, which are only found in the upper part of the duodenum. Müller's fluid, hæmatoxylin. (Merkel.)

FIG. 8. **The End of a Villus from the Last Specimen** (×180).—The basement membrane and supporting tissue of the villus have retracted from the epithelium, leaving a space occupied by red and white blood-corpuscles and fibrin threads, which present an appearance easily mistaken for connective tissue. The epithelium is columnar, and has a striated free border; between the cells wandering leucocytes are often seen.

Fig. 1.

Fig. 2.

Fig. 3.

Fig. 6.

Fig. 4.

Fig. 7.

Fig. 5.

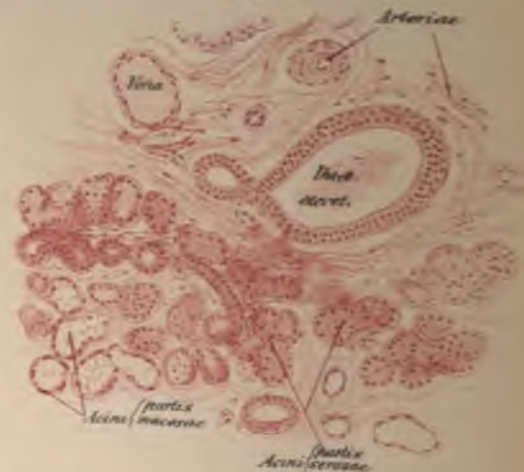

Fig. 8.

Fig. 9.

Fig. 10.

G 7. SALIVARY GLANDS AND PANCREAS.

FIG. 1. **From a Section of the Sublingual Gland (×100).**—This is an example of a *mixed* gland—that is, a gland which possesses acini of both kinds, mucous and serous or true salivary.

The two kinds are seen to differ in their behaviour to staining reagents, the cells of the serous acini staining uniformly, while those of the mucous acini are clear and unstained, except for a small zone with the nucleus near the basement membrane, and some special cells lying in certain situations outside the ordinary cells.

The duct of the gland is seen cut across—twice transversely, once longitudinally. It is lined by a single layer of columnar epithelium, the cells of which present a striated or rodded appearance at their attached margins. Heidenhain's hæmatoxylin. (Flemming.)

FIG. 2. **Various Parts of the Last Specimen (×650).**—*a*, **Four epithelial cells from a small duct.** At *i*, the part of the cell directed towards the lumen, the protoplasm is granular, while beyond the nucleus it is striated, as described above.

FIG. 2*b*, 2*c*. **Cells from mucous acini**—*b*, **longitudinal section**; *c*, **transverse section.** The nuclei are situated near the outer part of the cells, and are surrounded by a small quantity of granular protoplasm; the remainder of the cells is clear, highly refractive, and unstained, being swollen out with mucin.

Lying between these cells and the basement membrane in certain situations, as at *m*, are deeply-stained granular cells arranged side by side to form the *crescents of Gianuzzi.*

FIG. 2*d*. **The epithelium of a serous acinus.** Only one kind of cell lines the acinus (the serous cell), with well-stained granular protoplasm, distinct outlines and nucleus. The serous glands possess no crescents of Gianuzzi.

FIG. 3. **Nerve Endings in the Salivary Glands (× about 600).**—The nerves spread out between and upon the cells of the gland from a small nerve trunk seen in the upper part of the section. Silver-reduction method. (From Bergh, after Retzius.)

FIGS. 4*a* and 4*b*. **Parts of a Section of the Parotid Gland.** Flemming's fluid, acid carmine. (Merkel.)

FIG. 4*a*. **The Duct in Longitudinal and Transverse Section, and a Few Acini (×100).**—The part of the duct in longitudinal section is seen to be united to an acinus by a narrower part (the *intercalary part* or *ductule*), the epithelium in this situation being flattened instead of columnar as in the main part of the duct. The fat cells are blackened by the osmic acid.

FIG. 4*b*. **Section of an Acinus (×650).**—The cells are granular, and in some cases possess vacuoles, as at *v*; they are of the serous type, the parotid being an unmixed serous gland.

FIG. 5. **Section of a Part of the Submaxillary Gland (×80).**—The submaxillary gland in man, like the sublingual, is a mixed gland, both varieties of acini being seen in the section. A large and a small duct, with an artery and vein, are seen lying in a bed of connective tissue between the acini. Müller's fluid, acid carmine. (Merkel.)

Fig. 6. Transverse Section of a Mucous Acinus from the same Specimen (× 650).—Shows the typical characters of a mucous gland, as described above (*cf.* Fig. 2*b*, 2*c*). The large cell belonging to a crescent of Gianuzzi is highly granular, and also possesses some small vacuoles.

Fig. 7*a*. Cells from a Serous Acinus from the same Specimen (× 650).

Fig. 7*b*. Two Cells from the Wall of a Small Duct (× 650).—The striated appearance of the outer border of the cell, and the granular protoplasm next the lumen, can be readily made out.

Fig. 8. Part of a Section through the Pancreas (× 80).—In the supporting tissue bloodvessels and fat cells are seen. A small duct, with a narrow ductule or intercalary part passing from it directly to the lumen of an acinus, can be traced in the lower part of the section.

The acini closely resemble those of serous salivary glands, but are more tubular.

At * lie cells with granular contents (*cf.* Fig. 9*b*, 9*c*, 9*d*). Müller's fluid, hæmatoxylin. (Merkel.)

Fig. 9*a*. A Few Acini of the Pancreas, with a Ductule passing to one of them (× 320).—The ductule, or intercalary part, is lined by flattened epithelial cells, and passes directly to the lumen of one of the acini; the larger duct is lined by columnar epithelium.

The acini are seen to possess cells closely resembling those of the serous salivary glands, but in addition, in the centre of the acinus, in many cases, as at *x*, are seen cells (the *centro-acinar cells* of Langerhans.

Fig. 9*b*, 9*c*, 9*d*. Cells with Dark Granules, which stain with Osmic Acid (× 250).

Fig. 9*e*, 9*f*, 9*g*. To show the Changes in the Cells associated with Secretion (diagrammatic).

Fig. 9*e*. **After secretion.** The cells are small, somewhat shrunken, with distinct margins, and protoplasm almost free from granules, which have been discharged to form the active principle of the secretion.

Fig. 9*f*. **During secretion.** The cells appear larger, and the part of the protoplasm next the lumen is now obscured by granules (*zymogen*).

Fig. 9*g*. **Before secretion.** The cells contain large numbers of granules; the nuclei are near the bases of the cells.

The cells of the pancreas are seen to present two zones—an outer clear zone, an inner granular—the size of the latter varying with the stage of secretion. Flemming's solution: *a*, hæmatoxylin; *b*, *c*, *d*, carmine. (Merkel.)

Fig. 10. **Bloodvessels of the Pancreas, injected Blue, the Tissue stained Carmine (× 50).**—The capillaries form loops in the connective tissue between the lobules. (Waldeyer.)

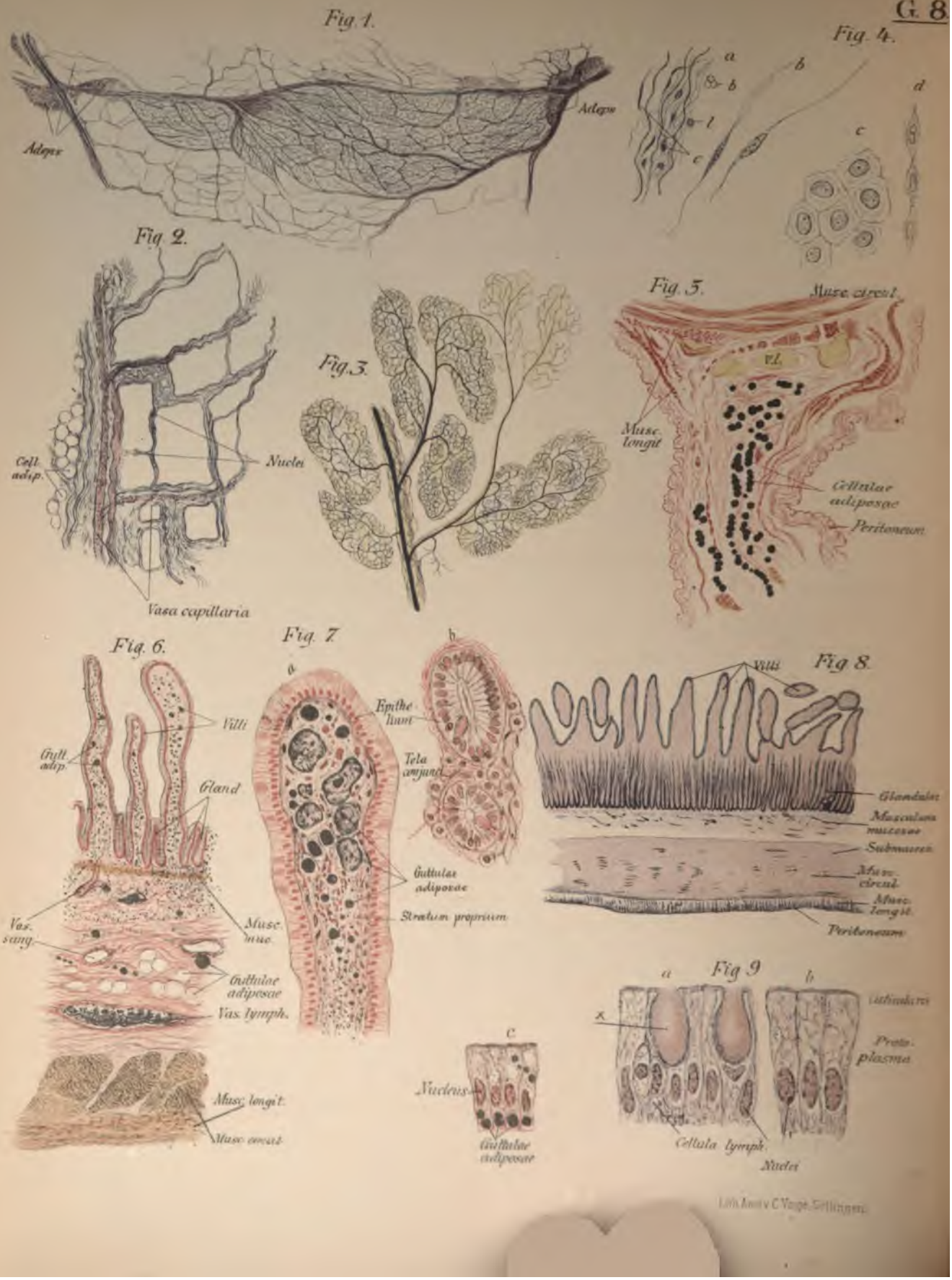

Lith. Anst. v. C. Vange, Göttingen.

G 8. OMENTUM AND MESENTERY. ILEUM.

FIGS. 1, 2, 3. **To show the Arrangement of the Connective Tissue in the Great Omentum of an Adult.**

FIG. 1. **Connective Tissue between and around the Vessels** (× **35**).—The connective-tissue bundles form an open network, in which fat cells are abundantly distributed. Methyl violet and fuchsin. Glycerin.

FIG. 2. **Part of the Same** (× **200**).—The network consists of areolar tissue; the meshes are wide, the fibres (white and yellow elastic) are arranged in small bundles; the nuclei of a few connective-tissue corpuscles are seen lying between the fibres, and around a small vessel there is a number of fat cells.

FIG. 3. **A Few Fat Lobules with the Bloodvessels injected** (× **15**).—The fat cells are arranged in small oval lobules, to each of which a small vessel goes, which, breaking up around and in the lobule, forms a capillary network about the fat cells.

FIG. 4. **Connective Tissue and Endothelial Elements from the Mesentery of a New-born Child.**

FIG. 4*a*. **Areolar Tissue** (× **200**), with connective-tissue cells and fibres.

b, Red blood corpuscles.
l, Leucocytes.
c, Connective-tissue elements.

FIG. 4*b*. **Two Connective-tissue Cells isolated** (× **600**).—They are fusiform in shape, and at each end are prolonged into one or two fine fibrils.

FIG. 4*c*. **Endothelium from the Mesentery, Surface View** (× **600**).—The cells are flattened, polygonal in outline, and closely fitted together.

FIG. 4*d*. **The Same, seen from the Side.**—The cells are seen to be narrow, with a central bulging around the nucleus.

FIG. 5. **The Attachment of the Mesentery to the Intestine** (× **20**).—The mesentery is seen to consist of two layers or folds of peritoneum, united by connective tissue conveying bloodvessels, lymphatics (*v. l.*), and nerves to the intestine. A number of fat cells (blackened by the osmic acid) lie in this connective tissue.

The two folds of the mesentery separate to enclose the intestine, which thus has a complete peritoneal or serous investment, except at the small area where the mesentery is attached to it; here there is a triangular area occupied by connective tissue in which the vessels run.

The longitudinal muscle of the intestine is seen to be continued for a short distance into the mesentery on each side. The peritoneal coat is much corrugated in the specimen. Flemming's solution, acid carmine. (Merkel.)

FIG. 6. **Part of a Longitudinal Section of Small Intestine during the Process of Fat Absorption** (×75).—Three villi and a few Lieberkühn's follicles are seen.

The fat globules are blackened by osmic acid, and can therefore be readily made out. They are seen in large numbers in the villi and submucous tissue.

A large submucous lymphatic vessel (*vas lymph.*) in the lower part of the section is seen to contain large quantities of fat. Flemming's solution, acid carmine. (Merkel.)

FIG. 7*a*. **Apex of a Villus during Fat Absorption** (×250).—As a result of the activity of the epithelial cells of the villus, which now contain few fat globules (but compare Fig. 7*c*), large numbers of fat globules are seen lying in the centre of the villus; some of these are probably collected by leucocytes.

FIG. 7*b*. **Transverse Section of Two Lieberkühn's Follicles from the Small Intestine** (×250).—These consist of a basement membrane lined by an epithelium similar to, and continuous with, that of the mucous membrane itself. The nuclei are near the base or attached margin, and some of the cells are transformed into *goblet cells*.

By some these follicles are regarded as absorptive in function rather than glandular.

FIG. 7*c*. **Epithelial Cells of the Small Intestine during Fat Absorption** (×500).—Globules of fat are seen actually in the cells themselves, the larger ones being near the basement membrane. (*Cf.* also Plate G 12, Fig. 8*a*.) Flemming's fluid, acid carmine.

FIG. 8. **Transverse Section of the Small Intestine** (×40).—The section shows the arrangement of the villi and Lieberkühn's follicles. Hæmatoxylin. (Waldeyer.)

FIG. 9. **Epithelial Cells from Intestinal Villi** (×650).

FIG. 9*a*. **Columnar Epithelial Cells with Two Goblet Cells**, *c*.—Two leucocytes are seen passing between the epithelial cells.

FIG. 9*b*. **Three Columnar Cells.**—They are seen to be narrower below, and possess a very marked intracellular network and a striated free border, or *cuticle*. Müller's fluid, hæmatoxylin. (Merkel.)

G 9. SMALL INTESTINE. VILLI. NERVE PLEXUSES.

FIG. 1. **Part of a Longitudinal Section of Small Intestine** (×4).—The mucous membrane shows long narrow folds (*valvulæ conniventes*); seen in transverse sections of the intestine, these folds are crescent-shaped, and involve a considerable proportion of the circumference of the bowel; they are thickly covered by *villi*. Flemming's solution, acid carmine. (Merkel.)

FIG. 2. **Large Lymph Follicles (Peyer's Patches) in the Mucous Membrane of the Small Intestine** (×75).—Over the follicle itself there are no villi (though they are closely packed at the sides), so that the follicle is covered by the epithelium and basement membrane only. The lymphoid tissue of the nodule is more compact in the centre. Müller's fluid, acid carmine. (Merkel.)

FIG. 3. **General View of the Bloodvessels of the Small Intestine** (×25).—The large vessels lie in the submucous coat, and give off branches upwards into the valvulæ conniventes, of which three are shown in the section; these vessels in their turn branch, to supply the villi covering the surface of the valvulæ conniventes. Numbers of small vessels are seen in the lower part of the submucous coat, some penetrating into the muscular layer. Vessels injected, tissue unstained. (Waldeyer.)

FIG. 4. **Bloodvessels in Three Villi from the Last Specimen** (×100).—A single small artery passes up one side of the villus, and begins to break up into capillaries about the middle of its length. The capillaries lie just beneath the basement membrane, and the blood from them is collected into one or two small veins which pass downwards into the submucous coat.

FIG. 5. **Plexus of Lymph Vessels, injected.**—(Waldeyer.)

FIG. 6. **Meissner's Plexus from the Submucous Coat of the Small Intestine.**—Large numbers of fine non-medullated fibres are seen passing from small ganglia and forming a plexus in the neighbourhood of a small bloodvessel. The ganglia contain small nerve cells. Gold chloride. (Waldeyer.)

FIG. 7. **Meissner's Plexus not so highly magnified.**—The ganglia are smaller, and the nerve fibres finer than those of the plexus next to be described (Auerbach's plexus myentericus). Some small vessels also form a network, which can readily be distinguished from the nerve plexus. Gold chloride. (Waldeyer.)

FIG. 8. **Auerbach's Plexus from between the Muscular Coats of the Intestine.**—Auerbach's *plexus myentericus*, as it is called, is seen to form a network with large polygonal meshes. The network is more distinct and the ganglia larger than those of the plexus of Meissner. Gold chloride. (Waldeyer.)

FIG. 9. **A Few of the Smallest Ganglia more highly magnified.**—Small groups of nerve cells are seen collected together at the nodes, surrounded by fibres which pass off in all directions to form the plexus.

Fig. 1.
Muscularis mucosae
Submucosa
Muscul. longit.
Muscul. circul.

Fig. 2.
Villi
Glandulae Lieberkühnianae
Folliculus solitarius

Fig. 3.
Villi
V.
Vasa capillaria
Vasa submucosae

Fig. 4.
Epithelium

Fig. 5.

Vas sang.
Fig. 6.
Ganglia
Fibrae nerveae

Fig. 7.
Vasa sang
Ganglia

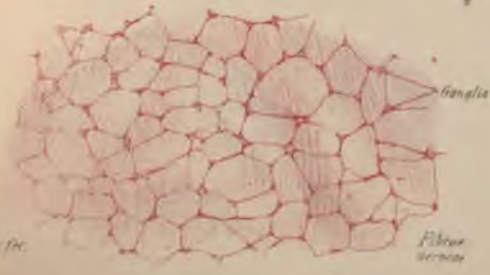
Fig. 8.
Ganglia
Fibrae nerveae

Fig. 9.
Cellulae nerveae
Ganglion
Fibrae

G. 10.

Fig. 1.

Nuclei

Tunica propria

Glandulae Lieberkühnianae (coliae)

Submucosa

Musc. mucosae

Fig. 5.

Membr. mucosa

Musc. circul.

Musc. longit.

Peritoneum

Submucosa

Arteriae

Vena

Mesenterium

Fig. 2

Cell. lymph.

Nuclei

Fig. 7.

Musc. longit.

Tela conjunct.

Epithelium

Fig. 6.

Foll. lymph.

Submucosa

Musc. circul.

Musc. longit.

Membrana mucosa

Peritoneum

Gland. Lieberkühn.

Fig. 3.

Fig. 4.

Nuclei

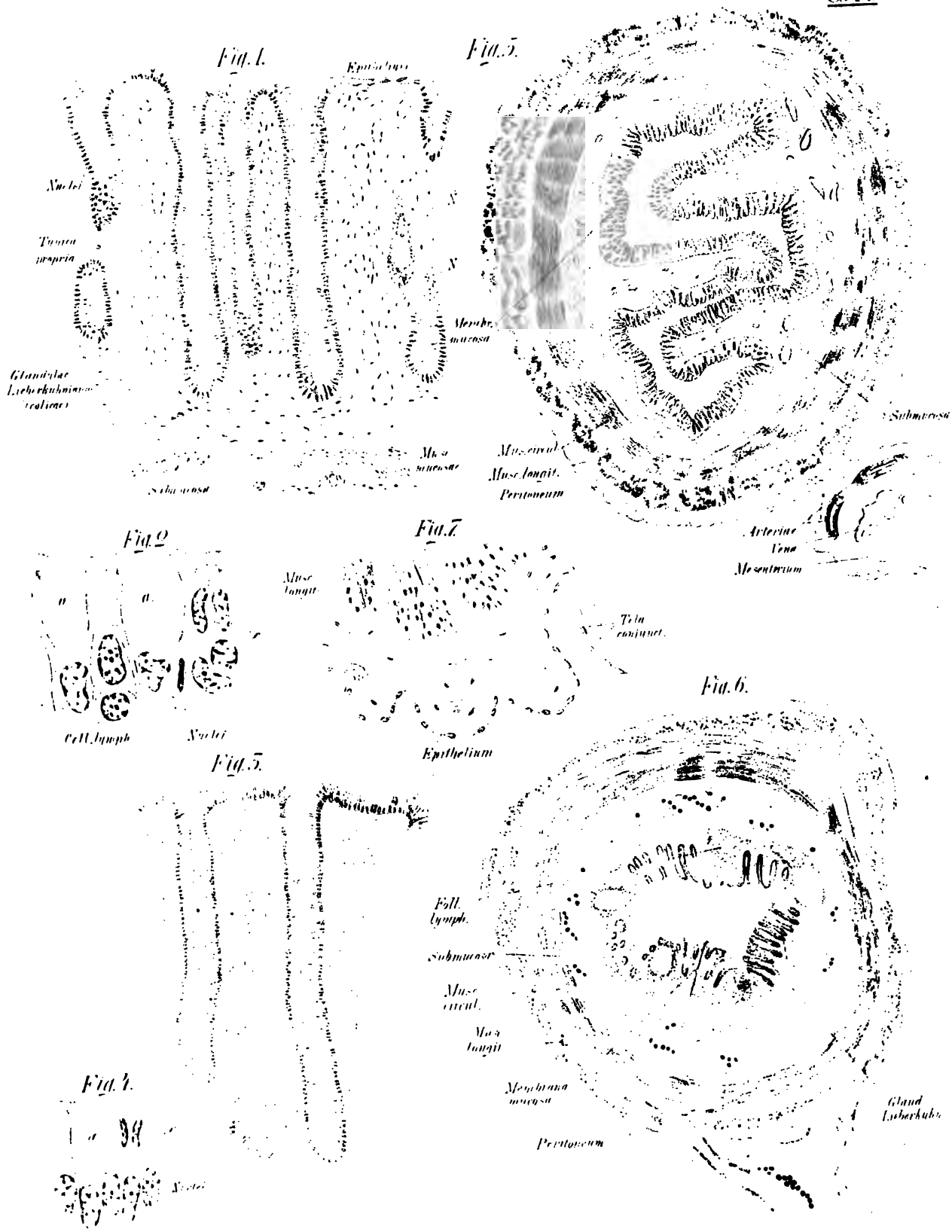

G 10. COLON AND VERMIFORM APPENDIX.

FIG. 1. **Transverse Section of the Mucous Membrane of the Large Intestine (Colon)** (×100).—Two *Lieberkühn's follicles* are seen cut so as to expose the lumen throughout their whole length; between them is a third, in which only the bases of the cells lining it are caught, so that the lumen is not seen. At the sides are glands cut transversely or obliquely. These glands are seen to be simple tubular depressions of the mucous membrane, without obvious division into duct and gland tubule. They each present a basement membrane, or membrana propria, lined by cells continuous with those covering the mucous membrane itself—that is, by columnar cells with large numbers of *goblet cells* (easily recognisable in the figure as the oval clear areas near the lumen).

The space between the tubules is occupied by retiform connective tissue, in which numerous blood capillaries are seen in section; this extends down to the *muscularis mucosæ*.

Note that there are no villi in the large intestine. Müller's fluid, acid carmine. (Merkel.)

FIG. 2. **Epithelial Cells from the Interior of a Lieberkühn's Follicle of the Large Intestine** (×1000).—The cells present similar characters to those of Plate G 8, Fig. 9, from a villus. The goblet cells, *a*, have discharged their contents. A lymph cell is seen in process of migration between the epithelial cells.

At *x** two nuclei, symmetrically placed, are seen. Their significance is not definitely known; it is possible that they belong to leucocytes, but in nearly all cases they occur symmetrically, as in the figure. Müller's fluid, acid carmine. (Merkel.)

FIG. 3. **Lieberkühn's Follicles from the Vermiform Appendix** (×100).—They are present in comparatively small numbers (*cf.* Fig. 6), but are nevertheless structurally completely developed. They present identical characters with those of the large intestine itself. Flemming's fluid, acid carmine. (Merkel.)

FIG. 4. **A Few Epithelial Cells from the Lieberkühn's Follicles of the Vermiform Appendix** (×750).—To compare with those of Fig. 2. Goblet cells, like that at *a*, are very abundant. The nuclei in relation to those of the cells of Fig. 2 are larger, but less rich in chromatin. The peculiar paired nuclei, like those at *x*, are in places very

* Dr. Brass suggests that these nuclei may be concerned in the regeneration of the epithelial cells, since it is probable that many of the goblet cells break down after discharging their contents.

abundant; they occur in the outer part of the cells of the gland tubules (*cf.* Fig. 2). Flemming's solution, acid carmine. (Merkel.)

FIG. 5. **Transverse Section of the Large Intestine in a strongly-contracted Condition** (×9).—The separate coats are very distinctly marked off from one another. The mucous membrane is thrown into folds, owing to the contraction of the muscular coat; it presents large numbers of Lieberkühn's follicles—the majority cut longitudinally, a few transversely or obliquely.

The submucous coat is thick and loose, and contains large and small vessels and lymphatics. The inner or circular muscular coat is wide, and distinctly marked off from the outer or longitudinal. At the lower part a small piece of the *mesocolon* is shown; the large vessels are seen to run in it on their way to the intestine. Müller's fluid, acid carmine. (Merkel.)

FIG. 6. **Transverse Section of the Vermiform Appendix** (×15).—The mucous membrane is small but completely developed, and possesses large quantities of lymphoid tissue, five separate nodules being visible in the section. Lieberkühn's follicles are present, but are comparatively few in number. The submucous coat contains a few fat cells. The muscular coat is about as well developed in proportion as that of the large intestine. Flemming's solution, acid carmine. (Merkel.)

FIG. 7. **A Part of the Peritoneal Coat of the Colon** (×100).—As a result of the contraction of the muscular coat, the serous membrane is thrown into folds. The structure of the peritoneum is seen to consist of a basis of subendothelial connective tissue, covered by thin flattened cells—the endothelium. Müller's fluid, acid carmine. (Merkel.)

Fig. 1.

Fig. 2.

Fig. 4

Fig. 3.

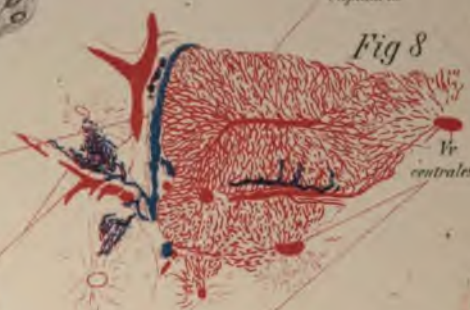

Fig 8

Fig. 5.

Fig. 9.

Fig. 6.

Fig. 7.

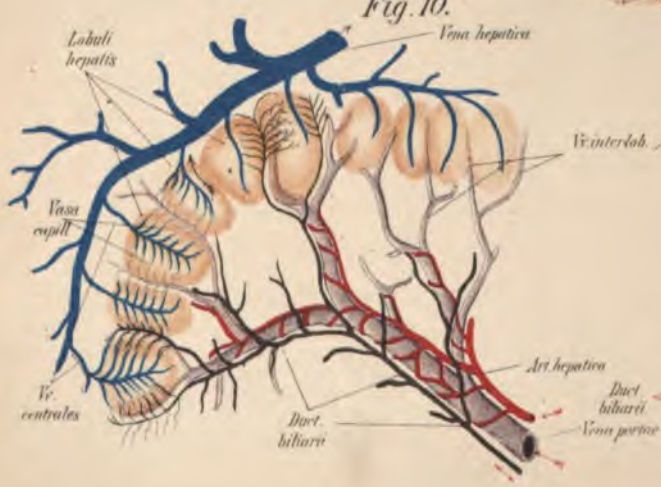

Fig. 10.

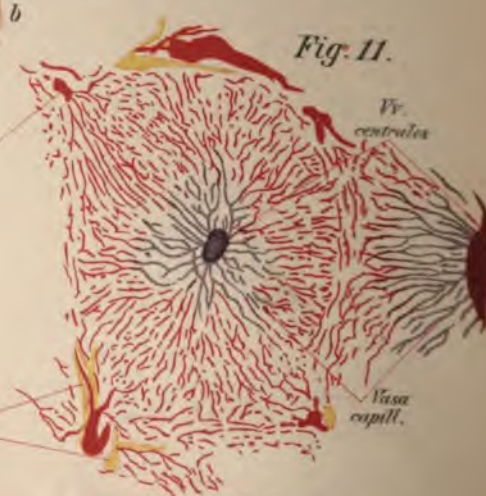

Fig. 11.

A. Brass fec.

G 11. LIVER.

Fig. 1. **A Small Piece from the Surface of the Liver** (×4).—Pigmented cell groups lie round the interlobular veins, giving the section the appearance represented. The peritoneum and the thick fibrous capsule (*Glisson's capsule*) are seen on the outer surface. Müller's fluid. (Merkel.)

Fig. 2. **Part of a Section through a Few Liver Lobules** (×30).—The lobules are separated from one another by connective tissue, which is very dense around the interlobular veins, which are accompanied by the larger bile-ducts, and by branches from the hepatic artery, the whole, with its investment of fibrous tissue, being known as a *portal canal*. Müller's fluid, hæmatoxylin. (Merkel.)

Fig. 3. **Showing the arrangement of the Liver Cells between the Periphery and the Centre of a Lobule** (×100).—A portal canal with a large *interlobular vein* is seen above; below, in what is really the centre of the lobule, is another vein in section, the central or *intralobular vein*. The rows of liver cells are separated from one another by capillaries, which, taking origin from the interlobular veins at the periphery, converge from all sides of the lobule to the central intralobular vein.

The small bile-ducts (*ductus biliarii*) in the portal canal are worthy of notice, being seen in transverse section above, longitudinal below. Müller's fluid, acid carmine. (Merkel.)

Fig. 4. **A Few Liver Cells from Fig. 2** (×400).—The liver cells possess no regular or characteristic shape; they are for the most part polyhedral. The nuclei, of which either one or two may be present, vary considerably in size, and have an accumulation of chromatic substance at their periphery. The protoplasm is also not uniform in structure, being especially complex if the cells are active; in the figure the protoplasm of many of the cells presents a very spongy appearance; in most of them the outer part of the cell is studded with fine granules; pigment granules and fat droplets are also seen in many of the cells (*cf.* Figs. 5-7). The intralobular capillaries and a small amount of connective tissue are seen between the cells, the former being for the most part cut longitudinally in this particular specimen. Many liver cells are in contact with several different capillaries, since the blood-supply to the liver tissue is a very rich one. Müller's fluid, hæmatoxylin. (Merkel.)

Fig. 5. **Liver Cells showing Pigment Granules** (×650).—The protoplasm of the cells contains large and small yellow granules.

One cell with two nuclei is seen in the lower part of the section. Müller's fluid, acid carmine. (Merkel.)

b, A connective tissue cell, lying beside a small capillary.

FIG. 6. **Liver Cells containing Fat Globules** (×650).—The fat has been blackened by the osmic acid, and consists of small droplets of various sizes in the protoplasm of the cells; yellow pigment granules are also present. Flemming's solution, acid carmine. (Merkel.)

FIG. 7. **Liver Cells without Fat Granules or Pigment** (×650).—One of the cells shows a very distinct network in its protoplasm. At *b* is a cell from the wall of a capillary lying between two liver cells. Müller's fluid, acid carmine. (Merkel.)

FIG. 8. **Liver Lobules injected—Bloodvessels Red, Bile-ducts Blue** (×30).—A central or intralobular vein is seen in longitudinal section, and converging towards it the capillaries from the interlobular branches of the portal vein; the latter appear as large trunks between the lobules.

In several other lobules the intralobular vein is seen in transverse section. The main bile-ducts, as stated above, accompany the interlobular veins in the portal canals; a few are seen between the lobules, injected blue, but they and the intralobular bile capillaries have only partly taken the injection. (Reichenbach.)

FIG. 9. **The Trunk of an Interlobular Vein injected Blue** (×50).—It passes between two lobules and gives off into each short lateral branches which break up into capillaries; these converge towards the central or intralobular vein, which is here marked in violet to emphasize the distinction. (Reichenbach.)

FIG. 10. **Diagram to illustrate the Arrangement of the Bloodvessels and Bile Canals.**—A few liver lobules are represented in yellow outlines. The branches of the portal vein (violet) are seen to pass between the lobules as *interlobular veins*. They are accompanied by branches of the *hepatic artery* (red) and of the *bile-duct* (black). The interlobular veins send off *capillaries* into the substance of the lobules (as shown in Figs. 8 and 9); from these the blood is collected by the *intralobular veins* (*vv. centrales*), and by these led into larger branches, the *sublobular* (blue), which join to form the *hepatic vein*. The arrows indicate the direction of flow in the various vessels.

FIG. 11. **Transverse Section of an Injected Liver Lobule** (×60).—The interlobular veins and their branches are shown in red, the intralobular vein and its rootlets in violet. The main bile-ducts were injected with chrome yellow; they appeared black under the microscope, but are here represented yellow. (Reichenbach.)

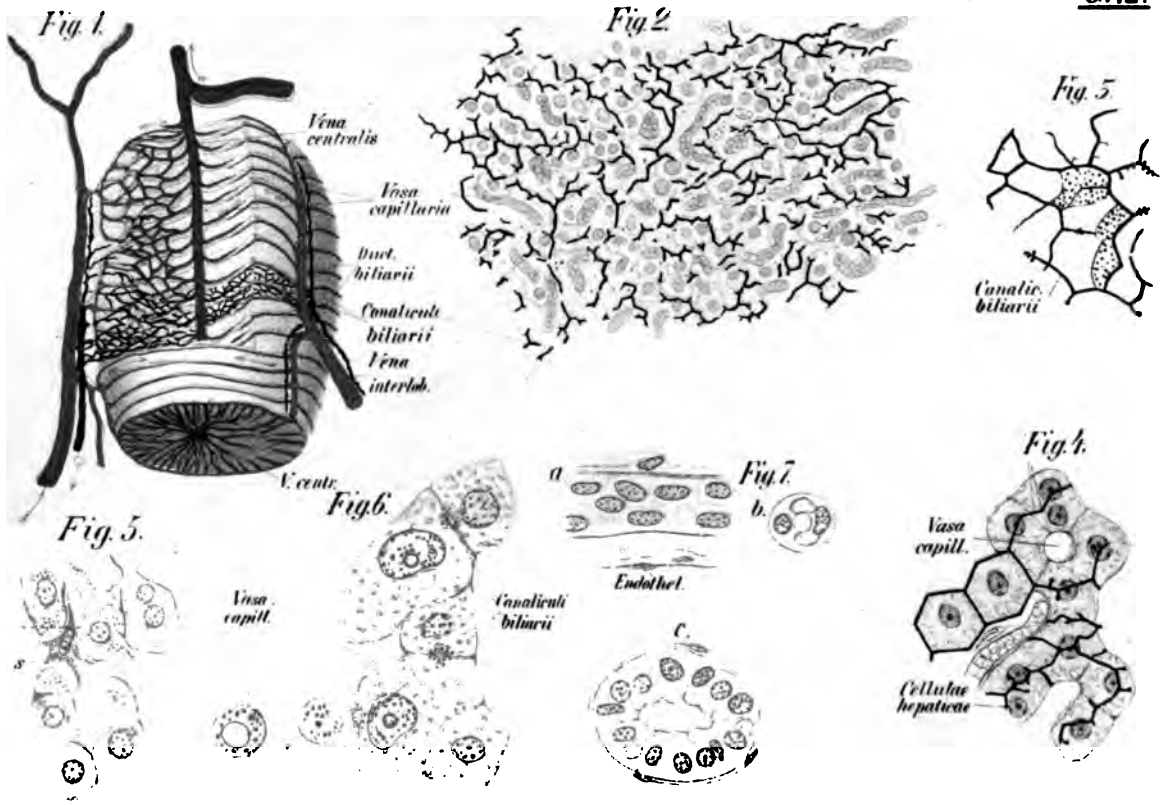
Fig. 1.
Vena centralis
Vasa capillaria
Duct. biliarii
Canaliculi biliarii
Vena interlob.
V. centr.
Fig. 2.
Fig. 5.
Canalic. biliarii
Fig. 5.
s
Vasa capill.
Fig. 6.
Canaliculi biliarii
a
Fig. 7.
b.
Endothel.
c.
Fig. 4.
Vasa capill.
Cellulae hepaticae

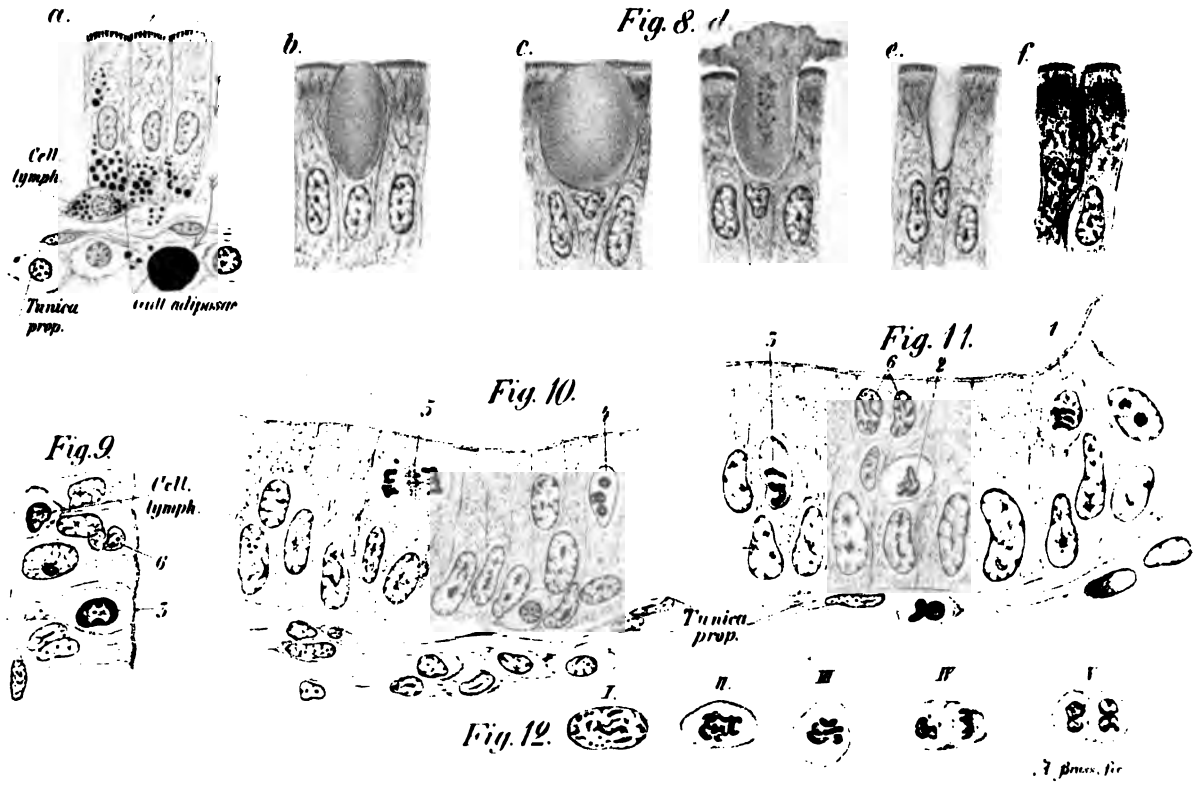
a.
Fig. 8.
b.
c.
d.
e.
f.
Cell lymph.
Tunica prop.
cell adipose
Fig. 9.
Cell. lymph.
6
5
Fig. 10.
5
4
Fig. 11.
5
6
2
1
Tunica prop.
Fig. 12.
I.
II.
III
IV
V

G 12. LIVER (continued). REGENERATION OF INTESTINAL EPITHELIUM.

FIG. 1. **Diagram of a Liver Lobule.**—The general arrangement and the colouring as in Plate G 11, Fig. 10.

The liver lobule is represented with a wedge removed in the upper part to show the intralobular vein and its origin.

The liver lobules are irregularly polyhedral in shape, and in the pig and camel are completely separated from one another by connective tissue derived from Glisson's capsule; in man, however, adjacent lobules are frequently partly fused together, so that the general structure is somewhat more complex.

FIG. 2. **Section of the Liver of a Rabbit (×150).**—The bile-ducts are mapped out by Golgi's method, since they reduce the silver salt; they are seen lying between the liver cells, which are stained red. The blood capillaries are yellow, and the red corpuscles they contain are distinctly seen. Golgi's method, alum cochineal. (Kallius.)

FIG. 3. **Bile Capillaries from a Similar Specimen, not counter-stained (×400).**—The *intercellular bile capillaries* give off small knobbed lateral twigs into the liver cells themselves (*intracellular bile passages*), the knobs or enlargements being vacuoles from which some of them originate. The vacuoles seem to be numerous in some of the cells.

FIG. 4. **A Similar Specimen (×400).**—The liver cells are marked out in violet, to show the relation of the bile channels to the cell substance.

FIG. 5. **A Stellate Connective-tissue Cell and its Processes around a Capillary (×400).**—Müller's fluid, acid carmine. (Merkel.)

FIG. 6. **Liver Cells (×650).**—Lying between the sides of adjacent liver cells (not at their angles) are seen a few intercellular bile capillaries, as small spaces, around which the protoplasm of the cell presents numerous pigment granules. Müller's fluid, acid carmine. (Merkel.)

FIG. 7. **Small and Medium-sized Bile-ducts (×400).**—*a*, Epithelium of a small duct seen from outside; below it a small vein with its lining endothelium.

FIG. 7*b*. **A small duct lined by two epithelial cells**; the nuclei of two cells more deeply situated are faintly visible.

FIG. 7*c*. **Transverse section of a medium-sized duct.** It consists of a basement membrane lined by a single layer of columnar epithelium. Müller's fluid, acid carmine. (Merkel.)

INTESTINAL EPITHELIUM UNDER VARIOUS CONDITIONS.

FIG. 8*a*. **Epithelial Cells from the Mucous Membrane of the Duodenum during Fat Absorption (×650).**—The fat is seen actually in the epithelial cells as fine droplets, which become larger nearer the base of the cell; the exact process by which the fat is

taken into the cell is not certainly known. It has been said that a considerable proportion of the fat in the intestine is saponified, and the soluble soaps so formed imbibed by the cell, which then breaks them up again into fat droplets within itself.

Leucocytes are often seen lying in or below the epithelium, crowded with fine fat globules,* one such being shown in this specimen. Flemming's solution, acid carmine.

Fig. 8*b-f*. **The Process of Secretion and Discharge in Goblet Cells (× 650).**—Each goblet cell is represented lying between two columnar cells of the ordinary form. Müller's fluid, hæmatoxylin. (Merkel.)

b, Collection of the secretion in the outer part of the cell; the nucleus is oval in shape and is situated near the base.

c, Goblet cell fully distended; the nucleus is now irregular in shape owing to narrowing of the foot of the cell.

d, Discharge of the secretion, and alteration in the form of the nucleus.

e, The cell completely discharged.

f, Cell probably in process of disintegration, for after this stage one finds similar cells with broken-down nuclei.

Figs. 9-12 illustrate the processes of cell multiplication occurring in the epithelium of the mucous membrane of the pyloric region of the stomach; the exact significance of the processes, however, is not known.

Fig. 9. **Changes in the Nuclei of the Epithelial Cells (× 500).**—At 3 is a nucleus in which the chromatin is arranged in bands about the outer part of the nucleus. At 6 are two nuclei formed by division.

A lymph cell is seen between two of the epithelial cells.

Fig. 10. **Cells in Process of Division (× 800).**—At 4 is a nucleus, the chromatin of which is collected together into four separate spherical masses.

At 5 is a nucleus in process of division, the chromosomes passing towards the poles.

Fig. 11. **Different Stages of the Same (× 1000):**

1. The chromatin becoming arranged in bands.
2. Formation of chromosomes.
3. Separation of the chromosomes.
6. Division completed.

Fig. 12. **A Few Stages represented separately** (*cf.* Plate A 3):

i. Chromatin arranged peripherally.
ii. Formation of the individual chromosomes.
iii. Same stage, lateral view.
iv. Separation of the chromosomes—metakinesis.
v. Formation of two new resting nuclei.

Figs. 10-12, Müller's fluid, acid carmine. (Merkel.)

* Some of the granules within these leucocytes, which blacken with osmic acid, have, however, been shown not to be fatty in nature.—Translator.

H.—ORGANS OF RESPIRATION.

Fig. 1.

Fig 2.

Fig. 3.

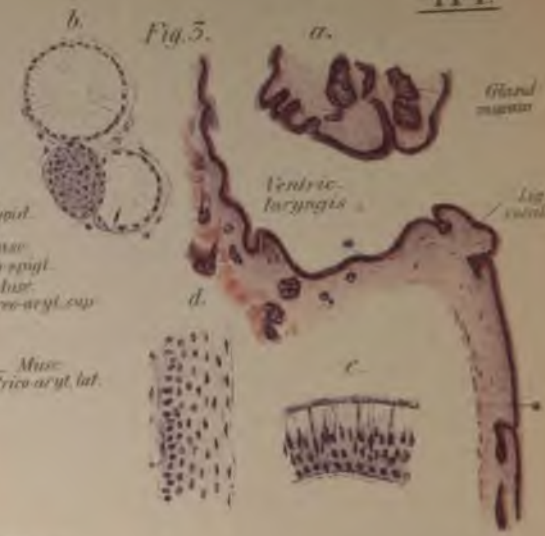

Fig. 4.

Fig. 5.

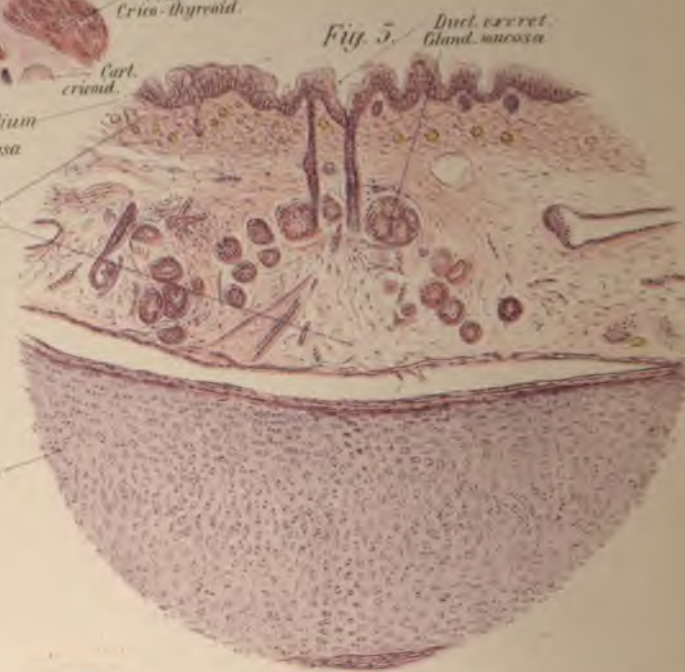

Fig. 6.

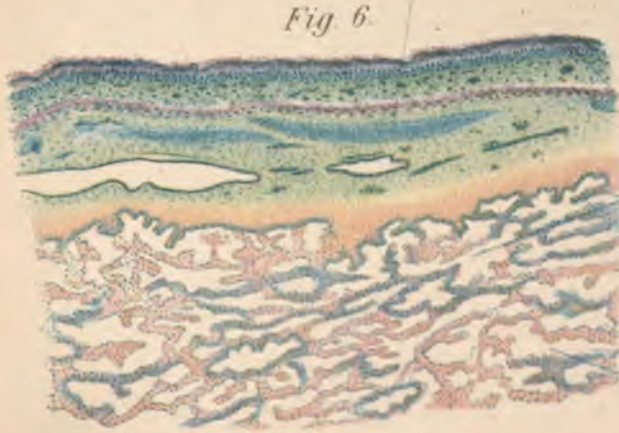

Fig. 7.

H 1. LARYNX AND AIR-TUBES.

FIG. 1. **Section through the Outer Part of the Epiglottis** (×20).—It is seen to consist of cartilage embedded in connective tissue, and with a mucous membrane externally, that part of the mucous membrane on the lingual surface (left in the figure) being thicker, presenting papillæ and large numbers of mucous glands, which are seen to lie in depressions in the cartilage. The cartilage is of the yellow elastic variety. The epithelium of the mucous membrane is stratified. Picrocarmine. (Ziemke.)

FIG. 2. **Section through One Half of the Larynx, transversely to the Vocal Cord** (×2½).—The arrow passes between the true and false cords into the *ventricula laryngis*, or ventricle of Morgagni. The true vocal cord (*lig. vocale*) consists of a firm band of fine elastic tissue; the false cord (*lig. ventriculare*) is a fold of mucous membrane.

The wing of the thyroid cartilage, and the muscles in relation with it and the vocal cord, are indicated on the plate. Hæmatoxylin, eosin. (Merkel.)

FIG. 3*a*. **Region of the True Vocal Cord** (×8).—Over the true vocal cord the epithelium is stratified, and this extends over the region indicated in the figure by the two asterisks; the other parts of the larynx are lined by ciliated epithelium.

The true vocal cord in this section is much relaxed; the end of the false cord is seen projecting over it at *a*.

FIG. 3*b*. **Mucous Gland Acini from the Larynx** (×180).—The acini are lined by narrow elongated cells, the nuclei being near the base, and the protoplasm clear and non-stained, owing to the mucin present in it. Two acini in complete transverse section lie beside a third, of which only the bases of the cells with the nuclei are cut across.

FIG. 3*c*. **Ciliated Epithelium from the Ventricula Laryngis** (×130).—A deeper layer of cells is seen beneath the actual ciliated cells.

FIG. 3*d*. **Stratified Epithelium from the Vocal Cord** (×130).—The epithelium presents the typical characters of a stratified epithelium, the deeper cells being closely packed and protoplasmic, the superficial ones flattened and scale-like.

FIG. 4. **Transverse Section of the Trachea of a Child** (×8).—The C-shaped hoop of hyaline cartilage is enclosed in fibrous tissue—the *perichondrium;* on its inner side lies the mucous membrane. This possesses large numbers of mucous glands, and is

lined by a ciliated epithelium. Between the ends of the hoop of cartilage there is a layer of non-striated muscle—the *trachealis muscle*. Hæmatoxylin, eosin. (Ziemke.)

FIG. 5. **Part of the Mucous Membrane of the Last Specimen (×80).**—Most internally is a layer of ciliated epithelium; beneath this, and resting on the basement membrane, a layer of non-ciliated cells (*Débove's membrane*). Beneath the basement membrane is a large quantity of areolar tissue, with abundant elastic fibres, and in the deepest part of this submucous tissue are the acini of the mucous glands, the ducts of which are seen passing upwards to open on to the surface.

The cartilage is enclosed by fibrous tissue, and is seen to be of the hyaline variety, the matrix being clear except at its external margin, where there are a few fibres.

FIG. 6. **Longitudinal Section of a Bronchus, with the Adjacent Lung Tissue (×50).**—Beneath the epithelium (ciliated) is a layer of areolar tissue with numerous capillaries, then a layer of plain muscle, arranged circularly—the *bronchial muscle* (stained violet). The cartilage, which is no longer in hoops, but in irregular plates, lies outside this layer of muscle in a connective-tissue investment containing large vessels; lastly, at the junction with the lung tissue is a layer (stained red) very rich in leucocytes.

The nuclei of the epithelial cells are stained violet, the leucocytes and blood corpuscles red; hence the peculiar coloration of the specimen. Hæmatoxylin, eosin. (Ziemke.)

FIG. 7. **One of the Smallest Bronchioles at its Passage into the Infundibulum and Alveoli (×120).**—The epithelial lining of the bronchiole (cubical, non-ciliated) passes into the single layer of flattened epithelium of the infundibulum. Hæmatoxylin, eosin. (Ziemke.)

H 2. LUNG. THYROID GLAND.

FIG. 1. **Bloodvessels at the Edge of a Lobule of the Lung of a New-born Child** (×50).—The pleura is cut obliquely, and hence appears thicker than it really is. The branch of the pulmonary artery (injected blue), shown on the right of the figure, breaks up into a capillary network between the alveoli; the rootlets of the pulmonary vein are shown in red. Injected Berlin blue and gelatin. (Ziemke.)

FIG. 2. **Capillaries around the Infundibula and Alveoli** (×100).—For the most part, the walls of the alveoli are cut across transversely, so that the nuclei stained are those in the walls of adjacent alveoli and the capillaries between them. At *a* the walls, and the close meshwork of capillaries over them, are seen from the surface. Berlin blue and gelatin. (Ziemke.)

FIG. 3. **Pulmonary Vessel breaking up to form a Capillary Network** (×300).—The pulmonary capillaries form a very fine network between the alveoli. The lymph vessels which accompany the artery are in this case pigmented; that is, leucocytes have deposited inhaled particles of carbon in this situation.

FIG. 4*a*. **Alveolar Wall in Transverse Section** (×400).—The alveoli are lined by thin flattened cells, and are separated from one another by very small quantities of elastic connective tissue, in which the capillaries lie, so that the blood in the latter has alveolar air on both sides of it, and is only separated from the air by the connective tissue and two layers of flattened cells:—the endothelium of the capillary wall and the flat epithelium lining the alveolus. Hæmatoxylin.

FIG. 4*b*. **Alveolar Epithelium seen from the Surface** (×400). Hæmatoxylin.

FIG. 5. **Section of the Thyroid Gland from a Child** (×80).—The vesicles of the gland are seen to be separated from one another by connective tissue (stained red), in which capillaries and larger bloodvessels are embedded. The nuclei of the cells of the vesicles are stained violet. Hæmatoxylin, eosin. (Ziemke.)

FIG. 6. **A Few Vesicles more highly magnified** (500).—The vesicles are oval in section, are distinctly marked off from one another, and are lined by a single layer of cubical cells with large spherical nuclei. The cavity of the vesicle is, as a rule, filled with *colloid substance* (*secretum*). Hæmatoxylin, eosin. (Ziemke.)

Fig. 1.

Fig. 2.

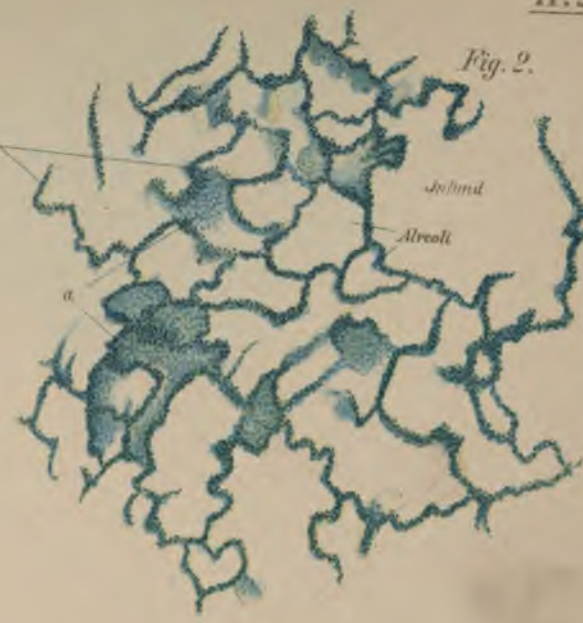

Fig. 3.

Fig. 4.

Fig. 5.

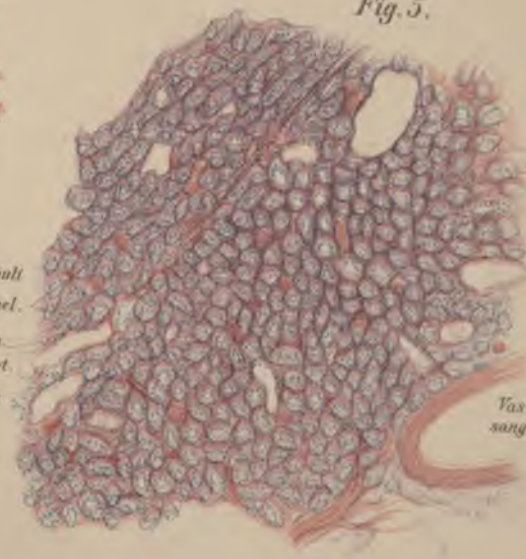

Fig. 6.

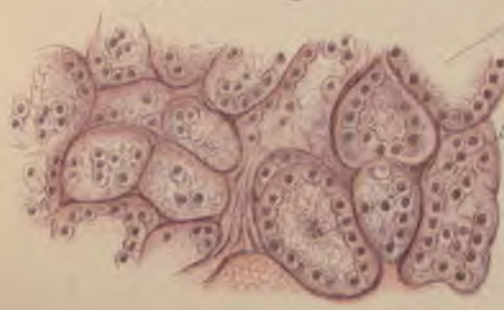

J.—THE VASCULAR SYSTEM.

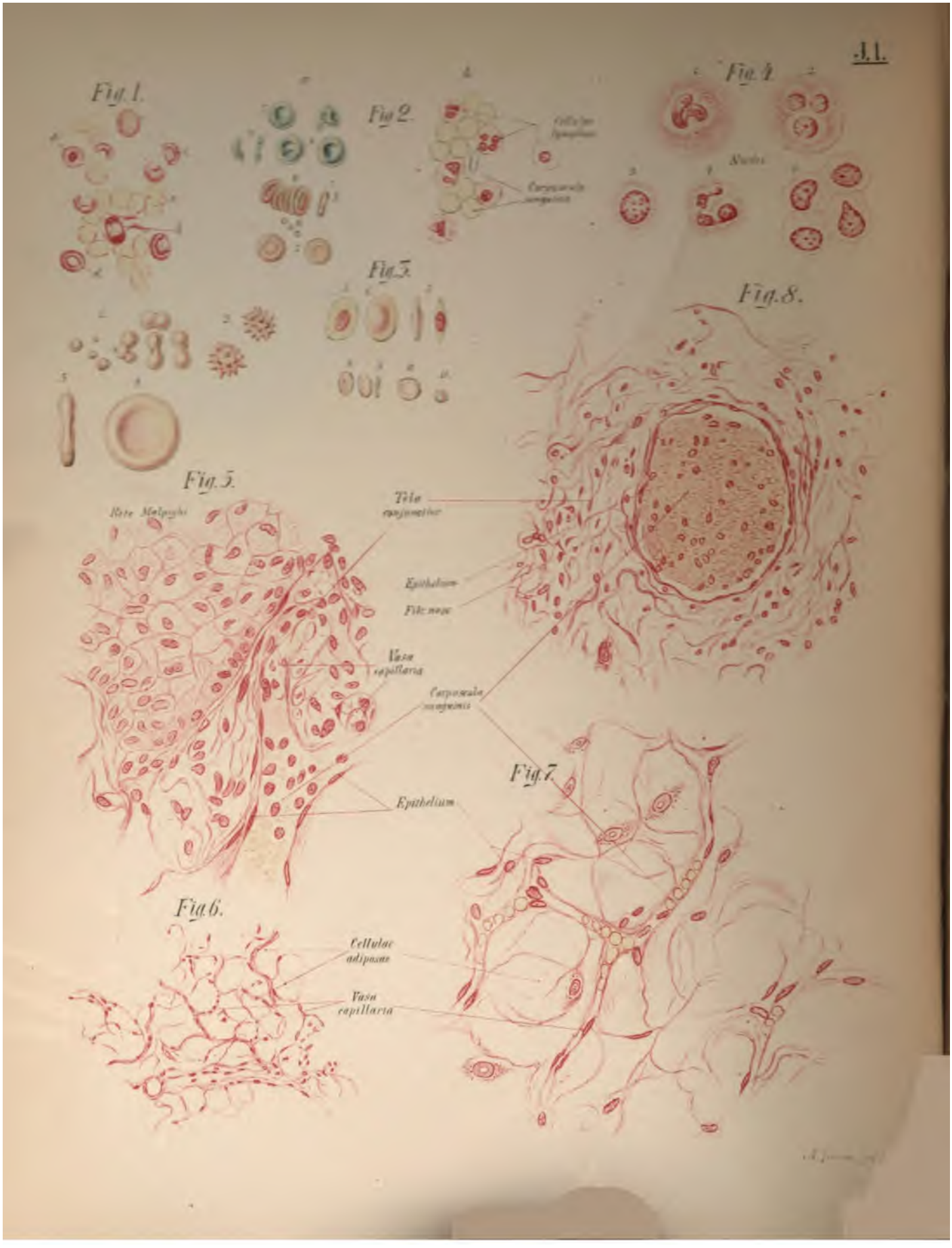
Fig. 1.
Fig. 2.
Fig. 3.
Fig. 4.
Nucleus
Fig. 5.
Rete Malpighi
Tela conjunctiva
Epithelium
Fila nervi
Vasa capillaria
Corpuscula sanguinis
Epithelium
Fig. 6.
Cellulae adiposae
Vasa capillaria
Fig. 7.
Fig. 8.

J 1. BLOOD CORPUSCLES AND CAPILLARIES.

FIG. 1. **Red Blood Corpuscles from a Seven-Months Fœtus (×550).**—Chromic acid, alcohol, picrocarmine.

a, Nucleated red blood corpuscle.

b, Nucleated red corpuscle dividing.

c, Red corpuscle—cup-shaped—staining readily (seen in profile).

d, Similar one seen on the flat.

e, Fully developed non-nucleated red corpuscles.

FIG. 2*a*, 1-3. **Red Corpuscles treated in the Fresh State with ½ per cent. Acetic Acid and Methyl Green (×650).**—1. Surface view. 2. Lateral view; the margins are thick, the central part concave and thinner. 3. A normal red corpuscle beside an effete one.

FIG. 2*a*, 4-7. **Treated while Fresh with Picric Acid and Carmine (×650).**—4. In rouleaux. 5. Side view. 6. Blood platelets. 7. Surface view of a red corpuscle.

FIG. 2*b*. **Red Corpuscles and Leucocytes from a Gastric Vein (×550).**—The leucocytes show variations in the character of their nuclei, some possessing two or more.

FIG. 3. **Various Forms of Red Blood Corpuscles:**

1. Disintegrated red corpuscles from the urine in hæmaturia.

2. Red blood corpuscles after the addition of salt and water—the *crenated corpuscle.*

3. Red corpuscle highly magnified—viewed in profile—showing its biconcave structure.

4. The same—surface view.

5, 6, 7. The oval, biconvex—nucleated red corpuscles of the frog.

8, 9. Small oval nucleated red corpuscles of the pigeon.

10. Human red corpuscle, to compare in size with—

11. That of the musk-deer, which is the smallest known.

FIG. 4. **Leucocytes from the Gastric Vessels (×1500).** — Müller's fluid, acid carmine.

1. With a coiled nucleus.

2. With three nuclei.

3. With a single large nucleus.

4. With the nucleus constricted in places.

5. Four leucocytes from the mucous membrane, each with one nucleus.

Fig. 5. **A Minute Arteriole from the Finger-tip, breaking up into Capillaries in a Papilla of the Dermis** (×750).—The endothelial layer of the intima of the arteriole is continuous with that of the capillary, of which it forms the only investment.

White blood corpuscles (recognised by their stained nuclei) frequently collect at the point of origin of the capillaries from an artery, as shown in the figure, and must be carefully distinguished from the nuclei of the endothelium, which are flat, when seen from the side. Chromic acid, alcohol, acid carmine.

Fig. 6. **Capillary Network among the Fat Cells of the Panniculus Adiposus** (×60).—Chromic acid, alcohol, acid carmine.

Fig. 7. **A Few Capillaries from the Last Specimen** (×300).—The variation in diameter of the red corpuscles (stained yellow) can be observed, due to some being compressed by the capillary wall; a similar appearance can be observed in the living condition, when a red corpuscle passes down a narrow capillary. The nuclei of the fat cells are in places shown in their surface view; they possess vacuoles; *i.e.*, they appear annular. The fat cells and endothelial cells of the capillaries are in direct contact. Chromic acid, alcohol, acid carmine.

Fig. 8. **A Small Vein from the Finger of a Seven-Months Fœtus** (×150.)—Among the fully-developed red corpuscles lie nucleated forms, more deeply stained, like those shown in Fig. 1. Picrocarmine.

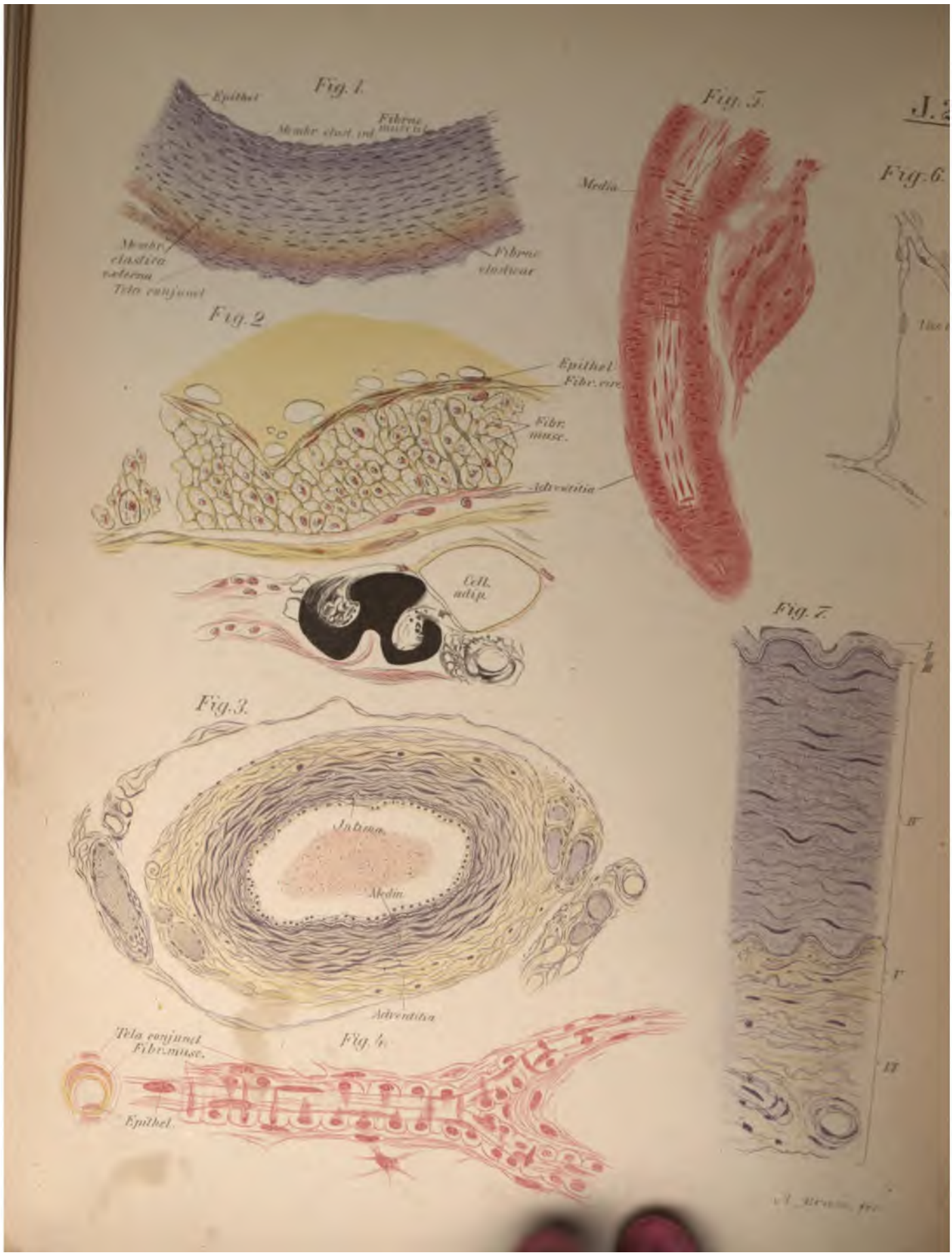
Fig. 1.
Epithel
Membr. elast. int.
Fibrae muscul.
Membr. elastica externa
Tela conjunct.
Fibrae elasticae
Fig. 2
Epithel
Fibr. corr.
Fibr. musc.
Adventitia
Cell. adip.
Fig. 3.
Intima
Media
Adventitia
Fig. 4.
Tela conjunct. Fibr. musc.
Epithel.
Fig. 5.
Media
Fig. 6.
Fig. 7.
I
II
V
III

J 2. BLOODVESSELS—ARTERIES AND VEINS.

FIG. 1. **Transverse Section of the Mammary Artery** (×125).—For an enumeration of the different layers, *cf.* Fig. 7.

The internal coat is seen to be corrugated, and lying just beneath it as a thin wavy white line is the *fenestrated membrane* of Henle (*membr. elast. int.*), composed of elastic tissue. Elastic tissue is also seen distributed throughout the middle coat as thin wavy fibres or thicker bands. Only a small part of the external coat is shown. Hæmatoxylin, eosin. (Ziemke.)

FIG. 2. **Transverse Section of a Small Vein from the Wall of the Stomach.**—Lying immediately beneath the *endothelium* is a thin ring of circular muscle fibres; then follows a thicker layer of longitudinal fibres, which are seen in transverse section in this specimen; the whole is enclosed by the *adventitia*, or external coat of connective tissue.

The fat cell which lies near the vessel will serve to afford a measure of the size relations. Flemming's solution, acid carmine. (Merkel.)

FIG. 3. **Transverse Section of a Small Artery** (×350).—This specimen shows well the separation into coats. The *intima*, or internal coat, is surrounded by the *media*, or middle coat, which is stained violet; and this in turn is enclosed by the *adventitia*, or external coat (stained yellow). Owing to the contraction of the artery, the inner coat is thrown into folds, while the outer coat has retracted from the surrounding tissues.

The outer coat is seen to consist of connective tissue, with smaller bloodvessels (*vasa vasorum*) in it. Hæmatoxylin, eosin.

FIG. 4. **Terminal Part of a Small Cutaneous Artery** (×550).—The endothelium, recognised by its nuclei being arranged longitudinally (*i.e.*, in the long axis of the vessel), is surrounded by short, circularly-arranged plain muscle fibres, their nuclei being transverse to the long axis of the vessel. The whole is enclosed by a small amount of connective tissue, constituting the adventitia. To the right of the figure the vessel bifurcates; the branches present similar characters, except that the muscular tissue is less.

On the left is a diagrammatic transverse section of the vessel. Chromic acid, alcohol, acid carmine.

FIG. 5. **A Small Cutaneous Vein** (×200).—Owing to the winding course of the vein, the section shows the structure of the different layers in one plane, since the plane of the section has caught all the various layers at different parts. In the long axis in

two places the elongated endothelial cells are exposed, with their nuclei arranged longitudinally. Around the endothelium the muscle fibres are seen for the most part in transverse section, as at the side; but in several situations, as in the upper and lower parts, also in longitudinal section, and are then seen to be arranged circularly, the nuclei of the epithelial cells being faintly discernible beneath them. 5 per cent. sublimate, acid carmine.

FIG. 6. **Formation of Capillaries in the Mesentery of a Seven-Months Fœtus (× 250).**—The mesoblastic cells join together by their processes, and then become hollowed out to form capillaries. Chromic acid, alcohol, hæmatoxylin.

FIG. 7. **Part of the Wall of a Large Artery (× 100).**—To show the structure and arrangement of the different layers. Hæmatoxylin, eosin.

Intima ... I. Layer of endothelial cells.
II. Subendothelial connective tissue.
III. Fenestrated membrane of Henle (elastic network).

Media ... IV. Composed of circularly-arranged plain muscle fibres, with some yellow elastic fibres. There is sometimes a distinct layer of elastic tissue—the external elastic membrane—separating this coat from the adventitia, but it is not constantly present.

Adventitia V. Inner part of the adventitia, very rich in white fibres.
VI. Outer part of the adventitia, with the vasa vasorum in section.

J 3. LYMPHATICS. THYMUS. SPLEEN.

FIG. 1. **A Lymphatic or Lymph Vessel just below the Glands of the Gastric Mucous Membrane** (×250).—The wall is composed chiefly of connective tissue lined by a layer of endothelium, the nuclei of which are seen in cross-section. There is a distinct space in the wall in the upper part, through which the leucocytes migrate into the mucous membrane. The cavity of the lymphatic is filled—in the lower part by coagulated lymph, in the upper part by leucocytes, which are stained red. Flemming's solution, acid carmine. (Merkel.)

FIG. 2. **Leucocytes from a Splenic Nodule in Process of Division** (×1200).—Isolated leucocytes are seen with their nuclei in various stages of karyokinesis.

In the small figure below and to the right are seen two leucocytes lying in a connective-tissue space; the cells of the connective tissue are called *inoblasts*. Hæmatoxylin, eosin. (Ziemke.)

FIG. 3. **Section through a Small Lobule of the Thymus of a Child** (×125).—The cortex and medulla can be readily distinguished from one another, since the leucocytes are less abundant in the medullary part of the lobules, which are therefore less deeply stained.

Hassall's corpuscles, the bloodvessels, and the connective-tissue septa are stained red in the specimen. Double-stained. (Ziemke.)

FIG. 4. **A Concentric Corpuscle of Hassall from the Thymus** (×400).—It consists of a central nucleated granular core surrounded by layers of flattened epithelial cells. Hæmatoxylin, eosin. (Ziemke.)

FIG. 5. **Section of the Spleen of a Child** (×12).—The *capsule* sends in *trabeculæ*, which divide irregularly, to form the supporting tissue of the organ (stained red). The *splenic pulp* is stained violet, and is seen to contain small nodules more deeply stained —the *Malpighian corpuscles*. There is no division into cortex and medulla, as in the case of a lymphatic gland. Hæmatoxylin, eosin. (Ziemke.)

FIG. 6. **A Malpighian Corpuscle from the Last Specimen** (×120).—It is seen to consist of a more dense mass of lymphoid tissue arranged round a small artery. The inner part of the nodule is less compact in structure than the outer, and constitutes the germ centre.

J. 3.
Fig. 1.
Cellulae lymphae
s
Lympha
Endothel
Vena
Art.
Fig. 2.
2.
1.
a.
l.
3.
Inoblast
Trabecula
Fig. 3.
Tela conjunct
Fig. 4.
Cellulae lymphae
Corpuscula Hassaliana
c
Fig. 5.
Trabeculae lienis
Capsula
Noduli lienalis (Malpighii)
Pulpa
Arteria
Fig. 6.

K.—URINARY ORGANS.

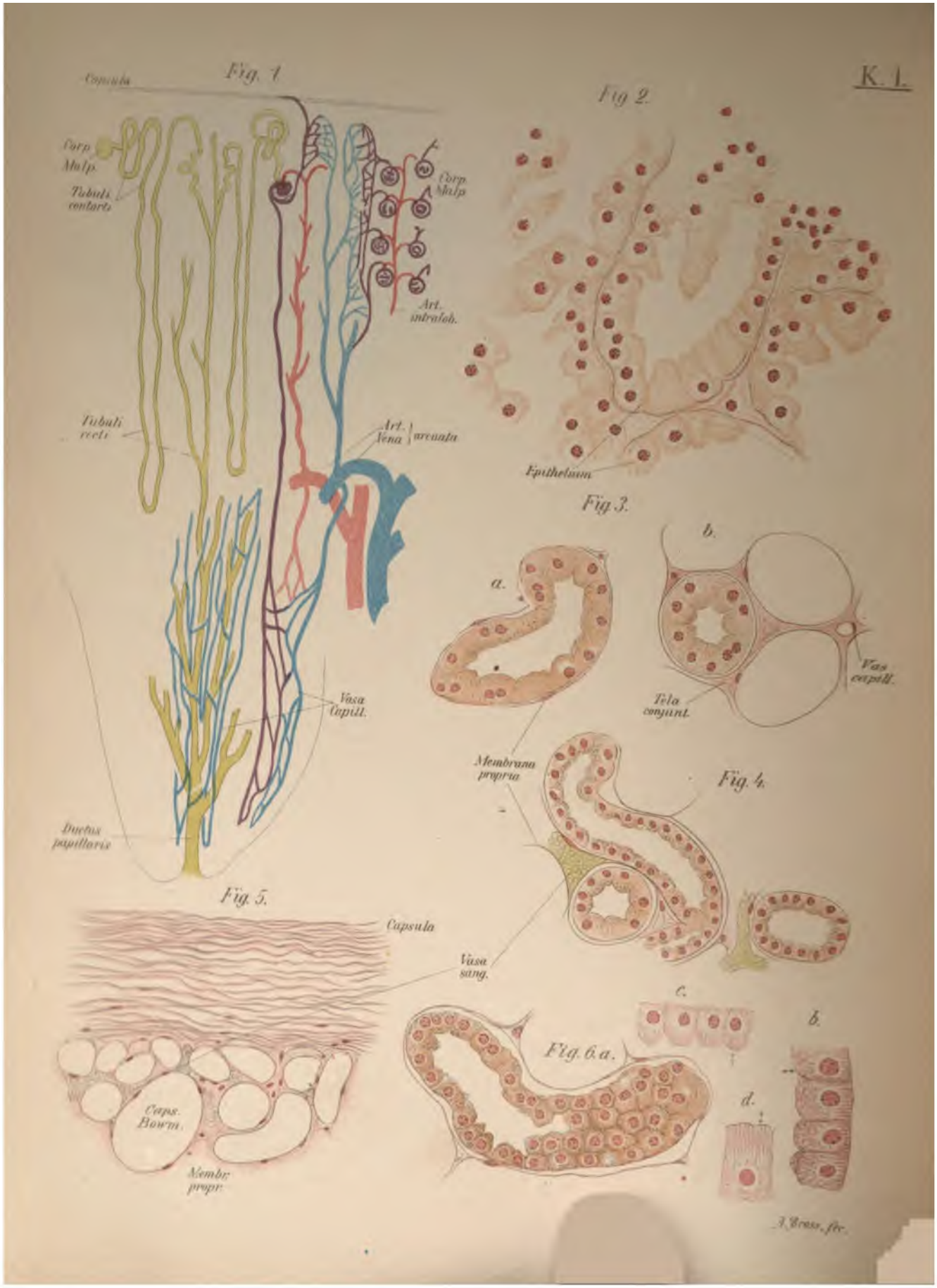
K. 1.
Fig. 1
Capsula
Corp. Malp.
Tubuli contorti
Corp. Malp.
Art. intrafob.
Tubuli recti
Art. Vena arcuata
Vasa Capill.
Ductus papillaris
Fig. 2.
Epithelium
Fig. 3.
a.
b.
Vas capill.
Tela conjunct.
Membrana propria
Fig. 4.
Fig. 5.
Capsula
Vasa sang.
Caps. Bowm.
Membr. propr.
c.
b.
Fig. 6. a.
d.
J. Braun, fec.

K 1. KIDNEYS—BLOODVESSELS AND TUBULES.

FIG. 1. **Diagram to show the Arrangement of the Urinary Tubules and Bloodvessels of the Kidney.**—Arterial arches derived from the renal artery lie between the cortex and medulla, and give off *interlobular* or *radiate* arteries into the cortex; from these, small lateral branches—the *afferent vessels* to the glomeruli—arise. All these are represented in red in the figure. The *glomerulus* itself is made up of a tuft of capillaries, from which there emerges a smaller *efferent vessel* (violet in the diagram); this breaks up into capillaries over the convoluted tubules; the blood from this capillary network is collected by *interlobular veins* (blue in the diagram), and carried down to venous arches, from which the rootlets of the renal vein arise.

The medullary part of the kidney is supplied by a system of straight vessels (*vasa recta*), which are given off from the concave side of the arterial arches above mentioned. Similar straight veins collect the blood and return it to the venous arches.

A few medullary vessels known as *false vasa recta* are derived from the efferent vessels of the lower glomeruli; one such is shown in violet in the diagram.

FIG. 2. **Cells from the Convoluted Tubules of the Kidney of an Executed Criminal** (×**650**).—The cells vary very considerably both in size and shape. Müller's fluid, acid carmine. (Merkel.)

FIG. 3. **Section of Convoluted Tubules from near the Surface of the Kidney** (×**400**).—*a*, Tubule lined by cubical epithelium; the margins of the individual cells are often not distinguishable. The nuclei are in places seen to lie close together.

b, A tubule lined by higher epithelial cells. The basement membrane of two other tubules, and the intertubular connective tissue with a small capillary, are also shown. Müller's fluid, acid carmine. (Merkel.)

FIG. 4. **Epithelium of Henle's Loop** (×**250**).—One loop is seen in longitudinal section; below it is the narrow descending limb passing into it. On the right is a transverse section of a loop; the epithelium is seen to be narrow and flat. Müller's fluid, acid carmine. (Merkel.)

FIG. 5. **The Capsule and Intertubular Connective Tissue** (×**100**).—The epithelium is not shown. The capsule consists chiefly of fibrous tissue; the intertubular tissue consists of connective-tissue cells and fibres, with small bloodvessels. One of the spaces is a *Bowman's capsule*, and is still lined by its special flattened epithelium;

the space is occupied in the normal condition by a glomerular tuft (*cf.* Plate K 2, Fig. 6). Müller's fluid, acid carmine. (Merkel.)

FIG. 6*a*. **A Tubule from near the Bowman's Capsule shown in the Last Figure** (×**400**).—On the left of the tubule the cells are seen in transverse section, on the right they are seen from the base; the individual cells interlock with one another, and are more or less polygonal in outline. Müller's fluid, acid carmine. (Merkel.)

FIG. 6*b*, 6*c*, 6*d*. **Isolated Epithelial Cells from the Convoluted Tubules** (×**650**).—*b*, Four cells from a convoluted tubule. The base or outer part of each cell is striated or rodded; the part internal to the nucleus is granular.

c, Cells of the same kind from the mouse's kidney. The striation extends right through the cell.

d, A cell from the same preparation, with the striation at the inner part of the cell —*i.e.*, the part directed towards the lumen. 5 per cent. sublimate, acid carmine.

K 2. KIDNEYS (continued)—GLOMERULI.

FIG. 1. **Section of Injected Kidney** (×90).—The glomeruli appear as small spherical tufts of capillaries. To one of them a short afferent vessel (*art. afferens*) is seen to pass, while a slightly smaller one (*art. efferens*) leaves it and breaks up into capillaries over the convoluted tubules around the glomerulus. Notice that the capillaries form a close meshed network over the convoluted tubules of the cortex, while they run parallel between the straight tubules of the medulla. The large spaces in the middle of the section are veins from which the injection mass has fallen out. Injected Berlin blue and gelatin, tissue stained carmine.

FIG. 2. **The Capillary Tuft of a Glomerulus** (×150).—The afferent vessel is seen to arise from a larger artery (*interlobular*), and to become convoluted and form a knot of capillaries, with a small amount of supporting tissue (stained blue) between them. The flattened epithelium of Bowman's capsule is seen in section. Injected carmine-gelatin, tissue stained hæmatoxylin.

FIG. 3. **Section through the Cortex and Medulla of the Kidney of a New-born Child** (×10).—Owing to the violet staining of the nuclei, the glomeruli are sharply marked off as dark dots, and the outline of some of the tubules indicated. Hæmatoxylin, eosin. (Ziemke.)

FIG. 4. **Part of the Cortex of the Last Specimen** (×75).—The glomeruli, being much shrunken, do not completely fill the Bowman's capsules. The epithelium of the convoluted tubules is seen in section.

FIG. 5. **Section through a Glomerulus** (×200).—The nuclei of the capsular epithelium and of the endothelium of the capillaries are distinctly visible.

Towards the left of Bowman's capsule is the *infundibulum*, or part from which the convoluted tubule arises; the epithelium of the capsule, elsewhere thin and flattened, here becomes gradually higher. Around the capsule is the intertubular connective tissue separating it from the convoluted tubules, some of which are seen in section. 5 per cent. sublimate, picrocarmine.

FIG. 6. **Section of a Bowman's Capsule** (×200).—On the left the convoluted tube arises from the *infundibulum* by a narrow *neck* (*collum*), the epithelium being much higher than that of the capsule itself, which consists of thin flattened cells, the nuclei of which are seen in the section inside the connective-tissue basis of the capsule. The glomerulus itself is covered by a similar epithelium, the nuclei of which are visible; the capillaries are seen indistinctly below this epithelial layer. 5 per cent. sublimate, hæmatoxylin, eosin.

Fig. 1.

Fig. 2.

Fig. 3.

Fig. 4.

Fig. 5.

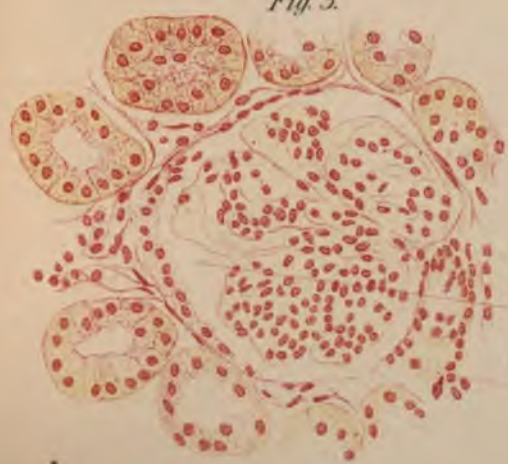

Fig. 6.

A. Bruss. fec.

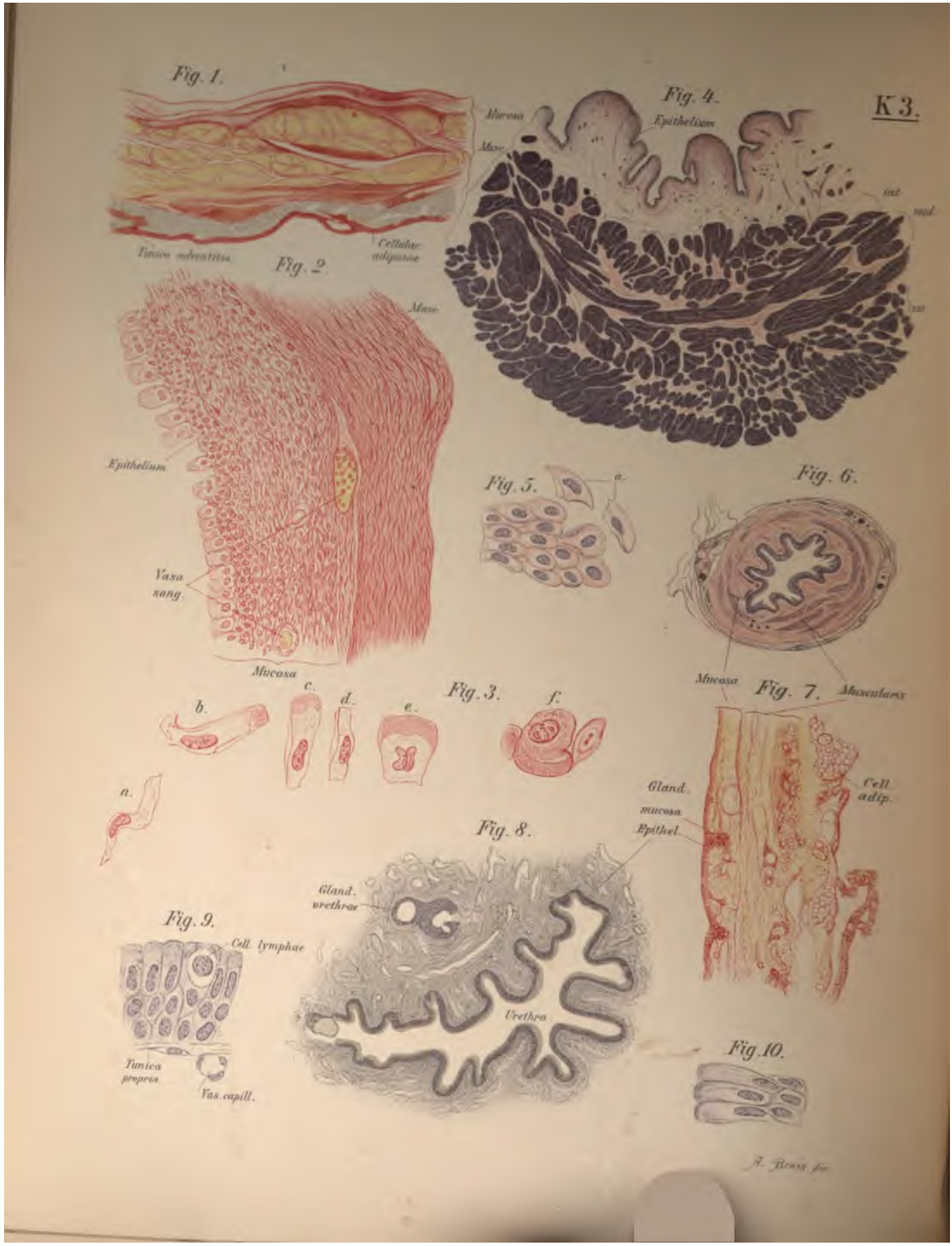
K 3.
Fig. 1.
Mucosa
Muc.
Tunica adventitia
Cellulae adiposae
Fig. 2.
Muc.
Epithelium
Vasa sang.
Mucosa
Fig. 4.
Epithelium
int.
med.
ext.
Fig. 5.
a.
Fig. 6.
Mucosa
Muscularis
Fig. 7.
Gland. mucosa
Epithel.
Cell. adip.
Fig. 3.
a.
b.
c.
d.
e.
f.
Fig. 8.
Gland. urethrae
Urethra
Fig. 9.
Cell. lymphae
Tunica propria
Vas. capill.
Fig. 10.
A. Brass fec.

K 3. URINARY BLADDER. URETER. URETHRA.

FIG. 1. **Section of the Wall of the Bladder from an Adult** (×**15**).—The mucous membrane (stained red) rests upon the muscular coat, which consists of bundles of plain or non-striated muscle fibres (stained yellow); externally is a layer of fat, the fat cells appearing as small greyish vesicles. Picrocarmine. (Freudenstein.)

FIG. 2. **The Mucous Membrane and Part of the Muscular Wall of the Bladder of an Adult** (×**200**).—Some of the superficial epithelial cells have fallen away, so that the shape of those remaining is more readily made out (*cf.* Figs. 3 and 5). The epithelium consists of several layers, and is of the *transitional* variety; beneath it is a layer of subepithelial connective tissue with small bloodvessels. The muscle fibres are stained red. Picrocarmine. (Freudenstein.)

FIG. 3. **Various Forms of Epithelial Cells seen separately (from the Last Specimen)** (×**800**).—*a*, Cell from the deeper layers, irregular in shape.

b-e, Various forms of cells from the superficial layer; the unattached part of the cell stains better than the deeper part.

e, Cell with two nuclei, common in the upper layer.

f, A large cell with a striated outer part (directed downwards) and two nuclei. Beside it are two irregular accessory cells (*cf.* also Fig. 5). Picrocarmine. (Freudenstein.)

FIG. 4. **Section of the Wall of the Bladder of a Newly-born Child** (×**8**).—The muscular coat is strongly contracted, so that the mucous membrane is thrown into folds. The muscle is seen to be deeply stained, and is arranged in three layers—an internal, of longitudinal fibres; a middle layer of circularly-arranged fibres, which is most marked at the neck of the bladder, forming the sphincter; the external layer is much thicker, and consists of longitudinal fibres. Hæmatoxylin, eosin. (Ziemke.)

FIG. 5. **Epithelial Cells from the Mucous Membrane of the Bladder of a New-born Child** (×**450**).—This epithelium is typical of the structure of transitional epithelium. It consists of three or four layers of cells; the most superficial is composed of large flattened cells hollowed out below for the convex surface of the upper part of the cells of the second layer—the pear-shaped or *pyriform* cells, beneath which there is always one layer of irregular polygonal cells, and sometimes two or more.

The most superficial cells often possess two nuclei, as shown in Fig. 3, *e* and *f*. Hæmatoxylin, eosin. (Ziemke.)

Fig. 6. **Transverse Section of the Ureter from a New-born Child** (×15).—It consists of (i.) a *mucous membrane* lined by transitional epithelium; (ii.) a *muscular coat* of three layers, like that of the bladder, the middle one being circular, the inner and outer layers longitudinal; (iii.) an *outer investment* of fibrous tissue. Hæmatoxylin, eosin. (Ziemke.)

Fig. 7. **Longitudinal Section of the Ureter of an Adult** (×15).—It presents very similar characters to the last specimen; the arrangement of the muscular fibres is more distinct, the fibres of the middle or circular layer being seen in transverse section. Picrocarmine. (Ziemke.)

Fig. 8. **Transverse Section of the Urethra of an Adult** (×50) (*cf.* Plate L 4, Figs. 2 and 6).—The mucous membrane is thrown into numerous folds, and in this the prostatic part of its course, is lined by transitional epithelium, the nuclei being seen to be darkly stained in this specimen. Hæmatoxylin. (Ziemke.)

Figs. 9, 10. **Epithelium from the Urethra** (×450).—It consists of two or three layers, the most superficial cells being elongated and cylindrical. Hæmatoxylin. (Ziemke.)

L.—GENERATIVE ORGANS

L 1. OVARY.

Fig. 1. **Transverse Section of the Ovary of a New-born Child (×10).**—The ovary appears irregular in outline. At the *hilus* numerous bloodvessels (stained yellow) are seen in section; these constitute the *pampiniform plexus*, which lies between the layers of the broad ligament. Alcohol, picrocarmine.

Fig. 2. **A Small Part of the Cortex of the Last Specimen (×75).**—The ovary has a layer of epithelial cells externally—the *germinal epithelium*. Large numbers of small vesicles, also with an epithelial covering, are seen; these are the *primitive ova*. The interstitial tissue, or *stroma*, consists of fibrous tissue, with numerous spindle-shaped connective-tissue cells.

Fig. 3. **Part of the Cortex of the Ovary of a Seven-Months Fœtus (×175).**—The germinal epithelium dips downwards into the stroma, forming Waldeyer's *ovarian tubes*; as a rule, one of the cells of each of these tubes enlarges to form the *primitive ovum*, while the others develop into the epithelium of the follicle. Chromic acid, hæmatoxylin.

Fig. 4. **Two Primitive Ova from the Last Specimen (×350).**—Each ovum lies in its own follicle, enclosed by a *capsule* derived from the stroma; the epithelium of the follicle lies between the capsule and the ovum itself.

Fig. 5. **Follicles from the Ovary of the New-born Child (×350).**—The epithelium has now become more definitely arranged, forming a distinct lining to the follicle. In the upper part there are two ova in one follicle. Alcohol, picrocarmine.

Fig. 6. **Section through the Ovary, Parovarium, and Fallopian Tube of a Seven-Months Fœtus (×6).**—The tubules of the *parovarium* (*paroophoron*) appear as dark rings. The vessels forming the pampiniform plexus are again shown in section near the hilus of the ovary, enclosed in the broad ligament. The Fallopian tube and its fimbriæ are cut across in the lower part (*cf.* Plate L 2, Fig. 5). Chromic acid, hæmatoxylin.

Fig. 7. **A Gland Tubule from the Parovarium of the Last Specimen (×350).**—It is lined by a layer of cubical epithelium, and presents a more or less circular lumen.

Fig. 8. **A Vein from the Parovarium in Process of Obliteration (×350).**—The vein is filled with clot formed chiefly of red corpuscles; spindle-shaped cells derived from the adventitia, and probably also from the intima, are seen in it. From these fibrous tissue is developed, which gradually contracts and completely obliterates the vessel.

Fig. 9. **An Old Corpus Luteum from the Ovary of a Woman aged Forty Years (×30).**—A large corpus luteum is seen on the left of the specimen; it has a reddish centre composed of altered blood-clot, the rest is composed of vascular connective tissue.

c. o. is an older corpus luteum, which is undergoing fatty degeneration and absorption. Methyl violet and eosin.

Fig.1.

Fig.2.

Fig.3.

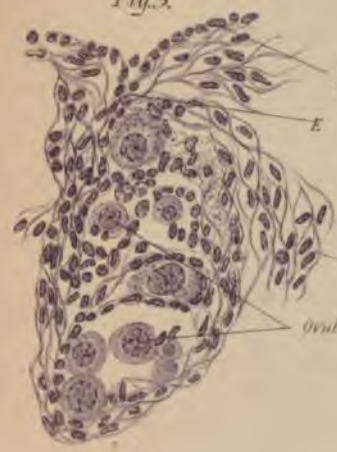

Fig.4.

Fig.5.

Fig.6.

Fig.7.

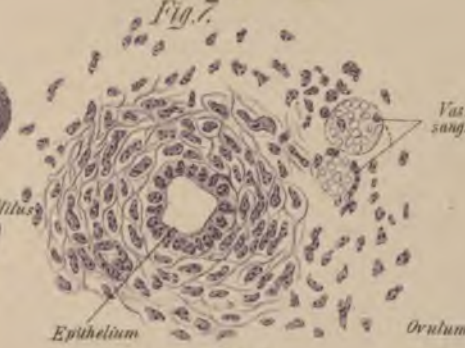

Fig.8.

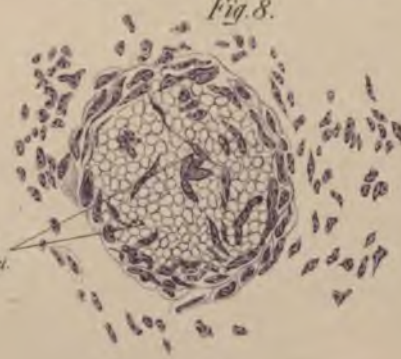

Fig.9.

A. Brass fec.

L 2. OVARY (continued)—UTERUS AND FALLOPIAN TUBES.

FIG. 1*a*. **A Mature Ovum** (×420).—A few of the epithelial cells of the follicle are still adherent to the zona radiata (*zona pellucida*), the radial striation of which is visible in places. The *germinal vesicle* is clear, and contains a large *germinal spot* and a few small chromatin granules. The *yolk* presents in the centre a reticulated appearance, and contains numerous clear spaces (vacuoles); in the outer part it is finely granular. Hæmatoxylin, eosin. (Merkel.)

FIG. 1*b*. **Cells from the Liquor Folliculi** (×420).—These are probably detached follicle cells.

FIG. 2. **Section of a Graafian Follicle** (×50).—The epithelial lining of the follicle is known as the *membrana granulosa;* in this specimen it has completely separated from the connective-tissue wall, or *theca folliculi*, as a result of the action of the reagents used in the process of preparation. The ovum lies in a collection of follicle cells known as the *discus proligerus* (*cumulus oophorus* in the diagram). The cavity of the follicle—*i.e.*, the space between the membrana granulosa and the discus proligerus—is occupied by the *liquor folliculi*.

At *x* lie the cells represented in Fig. 1*b*. Hæmatoxylin, eosin. (Merkel.)

FIG. 3. **Transverse Section of the Wall of the Uterus** (×10).—The mucous membrane contains large numbers of branching tubular glands. The muscular coat consists of two divisions; the inner and thicker consists of fibres running in various directions, but for the most part circularly, and is actually a greatly hypertrophied *muscularis mucosæ;* the outer and thinner division consists of circular and longitudinal fibres, and corresponds to the muscular coat of the other hollow viscera. Carmine. (Merkel.)

FIG. 4. **Uterine Glands of the Mucous Membrane of the Last Specimen** (×50).—The gland tubules are long, branched, and often curved; they are lined by ciliated epithelium like that covering the mucous membrane (*cf.* Fig. 7).

FIG. 5. **Fimbriæ of the Fallopian Tube of a Seven-Months Fœtus** (×80).—They consist of a basis of connective tissue covered with ciliated epithelium, and project from the mucous membrane. Chromic acid, hæmatoxylin.

FIG. 6. **Section of the Wall of the Fallopian Tube of an Adult** (×60).—Numerous bloodvessels are seen in the muscular coat; the fimbriæ present similar characters to those of the last specimen. Hæmatoxylin, eosin. (Merkel.)

FIG. 7*a*, 7*b*. **Ciliated Epithelium from the Uterus** (×400).—*a*, Elongated cells with long oval nuclei. *b*, Shorter cells; both varieties may be found in the same section.

FIG. 7*c*. **Ciliated Epithelium on a Fimbria of the Fallopian Tube** (×300).

L. 2.
Fig. 1.
a.
Corona radiata
Membrana pellucida (Chorion)
Zona ext. med. int.
Gland. uterinae
Mucosa
V
Muscularis
Macula germinat.
b.
Vesicula germinativa
Fig. 2.
Theca folliculi
Epithel. folliculi
Liquor folliculi
Cumulus oophorus
Ovulum
Fig. 3.
Fig. 4.
Gland. uterinae
Fig. 5.
Muco.
Strat. prop
Fimbriae
Fig. 6.
Vasa sang.
Fig. 7.
a.
Cilios
Musc.
b
Strat. prop.
c.

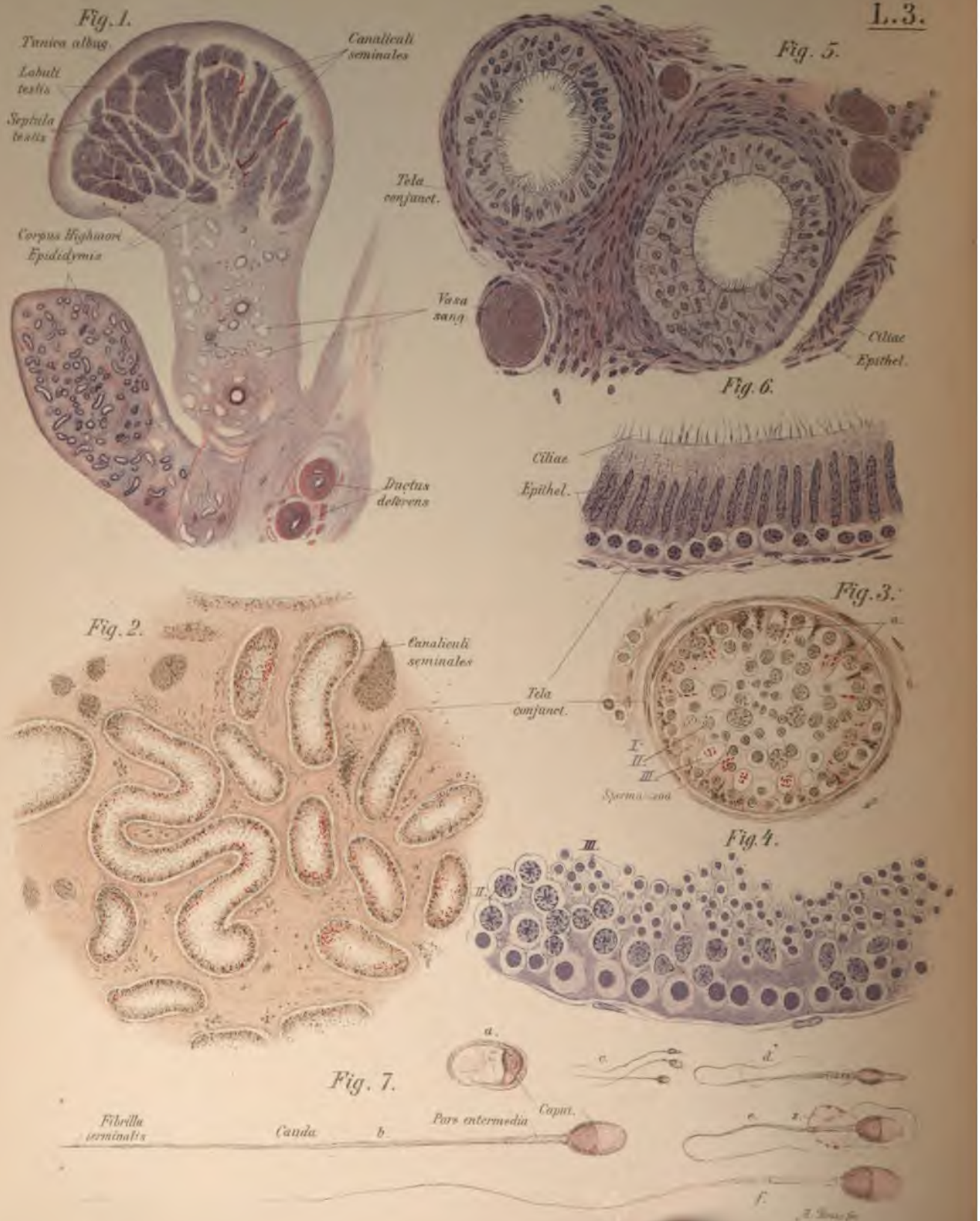
Fig. 1.
Tunica albug.
Lobuli testis
Septula testis
Canaliculi seminales
Corpus Highmori
Epididymis
Vasa sang.
Ductus deferens
Fig. 5.
Tela conjunct.
Cliae
Epithel.
Fig. 6.
Cliae
Epithel.
Fig. 2.
Canaliculi seminales
Tela conjunct.
Fig. 3.
a.
I.
II.
III.
Sperma zoa
Fig. 4.
III.
II.
Fig. 7.
a.
c.
d.
Fibrilla terminalis
Cauda
b.
Pars intermedia
Caput.
e.
g.
f.

L 3. TESTIS AND EPIDIDYMIS.

FIG. 1. **Transverse Section of the Testis and Epididymis of a New-born Child** (×9).—The testis is enclosed by an investment of dense fibrous tissue, the *tunica albuginea*. At the posterior part (the lower in the figure) the fibrous capsule is greatly thickened, and forms the *corpus Highmorianum*, or *mediastinum testis;* from this, septa pass inwards and extend to the tunica albuginea, dividing the organ into *lobules*, in which lie the *seminiferous tubules*. These converge to the mediastinum, and unite to form *straight tubules*, which anastomose with one another to form the *rete testis*, from which the *vasa efferentia* arise; these, after becoming convoluted in one part of their course to form *coni vasculosi*, open into the *epididymis*, which is a single highly convoluted tube.

The tube of the epididymis, with its supporting connective tissue, is seen cut across in various directions in the lower part of the figure; in the process of preparation the whole epididymis has become separated from the testis and displaced laterally.

The epididymis passes into the *vas deferens*, which is shown cut across twice in this specimen. Hæmatoxylin, eosin. (Ziemke.)

FIG. 2. **Transverse Section of a Part of the Testis of an Adult** (×50).—A small piece of the tunica albuginea lies above; beneath it the seminiferous tubules are cut across in various directions. The heads of any spermatozoa in the tubules appear as small red-stained bodies. Flemming's fluid, safranin and gentian violet. (Merkel.)

FIG. 3. **A Seminiferous Tubule from the Last Specimen** (×200).—It possesses a very thick basement membrane (*tela conjunct.*), on which rests a layer of large cells, for the most part with resting nuclei; these constitute (I.) the *lining epithelium;* some of these cells are elongated and project towards the lumen as *sustentacular cells*. Internal to this there are several other layers of cells, which can be better seen in the next figure.

FIG. 4. **Transverse Section of a Part of a Seminiferous Tubule** (×600).—The *lining epithelium* is seen as in the last specimen; its nuclei are darkly stained and in the resting condition; then follows a layer of cells, two or more deep, the *spermatogenic cells*, which have large nuclei showing a skein-like arrangement of the chromatin, indicating commencing karyokinesis. The most internal cells are smaller, more numerous, and possess distinct spherical nuclei; they are known as *spermatoblasts*, and gradually develop into *spermatozoa*. Hæmatoxylin, eosin. (Merkel.)

FIG. 5. **A Part of the Epididymis of Fig. 1 (×200).**—The tube is seen cut across twice, owing to its convoluted course; the two parts are separated by connective tissue conveying bloodvessels. The epithelium lining the tubule is ciliated. Hæmatoxylin, eosin. (Ziemke.)

FIG. 6. **A Part of one of the Vasa Efferentia of an Adult (×600).**—The epithelial lining is double; the deeper cells are short, and possess rounded nuclei; the superficial ones are columnar ciliated cells with elongated nuclei. Müller's fluid, hæmatoxylin, eosin. (Merkel.)

FIG. 7. **Spermatozoa.**—*a*, **Developing spermatozoon.** The tail is seen appearing as a filament in the protoplasm.

FIG. 7*b*. **Diagram of the parts of a spermatozoon.** The *head* is oval and united to the *middle part* (*pars intermedia*) by a small knob-shaped enlargement; the middle part is continued into a long *tail*, which ends in a special *terminal filament*.

FIG. 7*c*. **Spermatozoa (×400)**—the upper one in profile, the lower ones seen from the surface. The head is seen to be oval, though flattened from side to side, and somewhat pointed at the end.

FIG. 7*d*. **A spermatozoon in profile (×1500).** The head shows the anterior pointed part, and the tail is coiled. Around the middle part is a small remnant of the protoplasm of the spermatoblast from which the spermatozoon was developed.

FIG. 7*e*. **A spermatozoon seen from the surface (×1500).** The head is oval, as described above.

FIG. 7*f*. **A spermatozoon highly magnified (×2000).**

All prepared by Hermann's fluid (chromic-acetic-platinic chloride) and stained in acid carmine.

L 4. PENIS. PROSTATE. URETHRA.

Fig. 1. **Section from the Outer Part of One of the Corpora Cavernosa** (×75).—It is enclosed by a strong capsule of fibrous and elastic tissue, outside which is a layer of muscle fibres; both of these are stained red. The capsule sends in trabeculæ, also composed of fibrous and elastic tissue, and these separate the large cavernous blood-spaces (*cavernæ*) from one another; the trabeculæ appear broad in this specimen because the blood-spaces are not distended. This specimen is typical of the structure of *erectile tissue*. Picrocarmine. (Freudenstein.)

Fig. 2. **Transverse Section of the Erectile Tissue of the Penis** (×3).—It consists of the two *corpora cavernosa* above, separated by the *septum penis*, and enclosed by a dense fibrous capsule.

Below, and projecting slightly between the two corpora cavernosa, is the *corpus spongiosum*, with the *urethra* in the middle; lying at the side of the latter are the acini of *Littré's glands* in section.

In the connective tissue in the upper part of the penis lie the dorsal vein and the dorsal arteries and nerves of the penis. Picrocarmine. (Freudenstein.)

Fig. 3. **Transverse Section of a Part of the Prostate** (×75).—A few of the gland tubules, separated by connective tissue containing much plain muscle, are seen cut across in different directions. The tubules are lined by a columnar or cubical epithelium, and in some cases there is a second layer of cells between it and the basement membrane, as seen on the right-hand side of the figure. Hæmatoxylin, eosin. (Ziemke.)

Fig. 3*a*. **Prostatic Calculi within Three of the Gland Tubules** (×100).—These concretions have a laminated appearance, and occur within the lumen of the tubule. Hæmatoxylin, eosin. (Merkel.)

Fig. 4. **The Connective Tissue and Muscular Basis of the Prostate** (×12).—The cells lining the gland tubules are not indicated. Hæmatoxylin, eosin. (Ziemke.)

Fig. 5. **Epithelial Cells from the Prostate Gland Tubules** (×300).—The cells are more or less elongated, and rest on a basis of connective tissue. Hæmatoxylin, eosin. (Ziemke.)

Fig. 6. **A Part of the Urethra, with a Duct and Some of the Acini of Littré's Glands** (×80).—The epithelium of the duct is continuous with that of the urethra; the acini are lined by clear mucous cells. Chromic acid, acid carmine.

Fig. 7. **Acini from Littré's Glands** (×250).—*a*, **Before Secretion.** The cells are swollen out with mucin, and their nuclei lie near the bases of the cells, and are much flattened.

Fig. 7*b*. **During Secretion.** The cells are less distended, their outlines are more distinct; the nuclei are more spherical, and lie near the middle of the cells.

In the upper part, owing to the obliquity of the section, some of the cells are cut transversely, so that their nuclei lie close together.

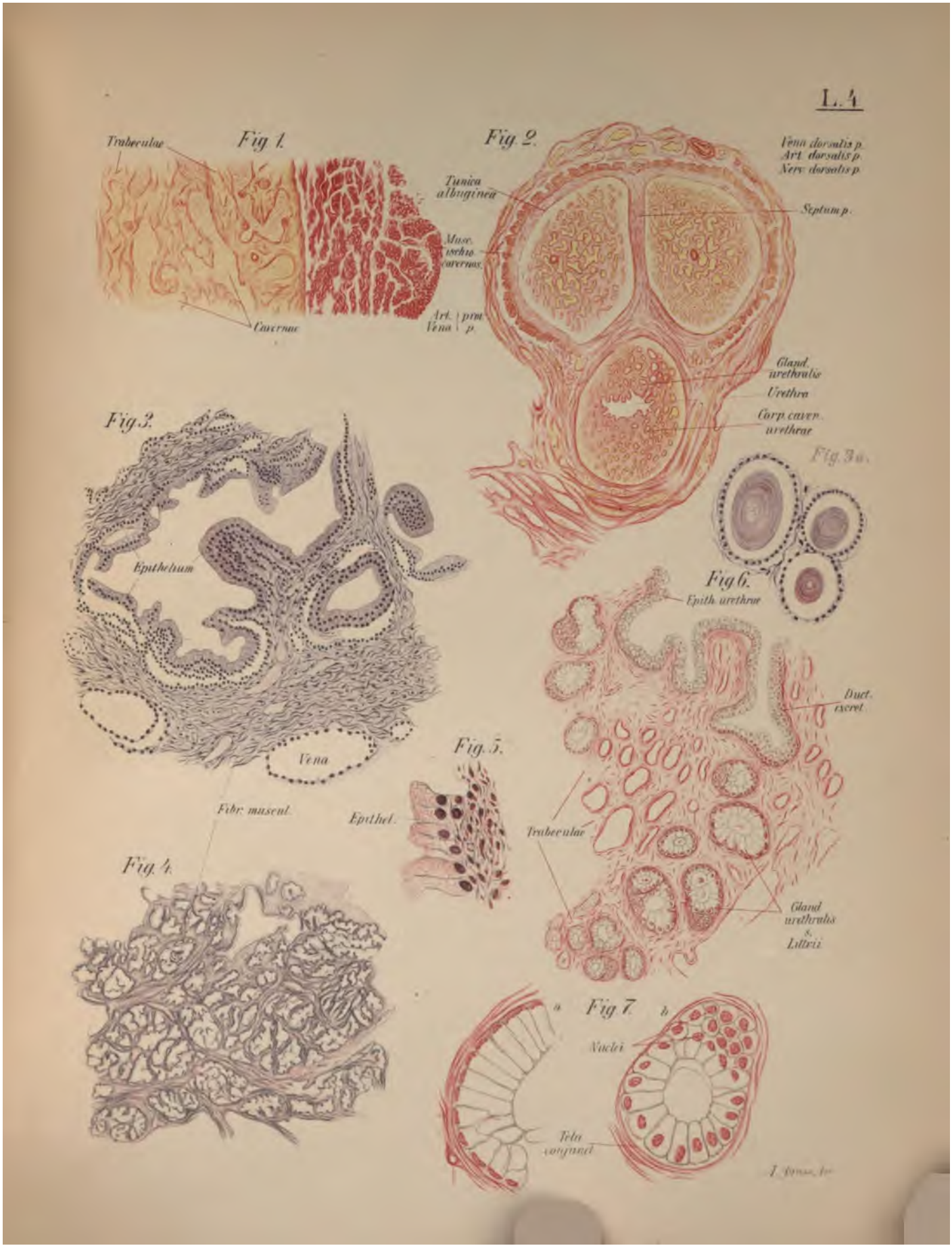
L. 4
Fig. 1.
Trabeculae
Cavernae
Fig. 2.
Tunica albuginea
Musc. ischio-cavernos.
Art. Vena prin. p.
Vena dorsalis p.
Art. dorsalis p.
Nerv. dorsalis p.
Septum p.
Gland. urethralis
Urethra
Corp. caver. urethrae
Fig. 3.
Epithelium
Vena
Fig. 3a.
Fig. 6.
Epith. urethrae
Duct. excret.
Trabeculae
Gland. urethralis s. Littrii
Fig. 5.
Epithel.
Fibr. muscul.
Fig. 4.
Fig. 7.
a
b
Nuclei
Tela conjunct.

INDEX.

Absorption of fat, 116, 123
Accessory disc of Engelmann, 88
olive, 60
Achromatic spindle, 20
Achromatin, 19
Adamantoblasts, 102
Adventitia of artery, 135
Air tubes, 127
Alveoli, 128, 130
Amitotic division, 19
Amœba, 13
Ampulla, 49
Apical cell, 14
Appendix vermiformis, 119, 120
Aqueduct of Sylvius, 71, 72
Arcuate fibres, 61, 63
Arcuate nuclei, 60
Areolæ of bone, 95
Areolar tissue, 115
Arrector pili, 25
Arteria centralis retinæ, 43
Arteriole, 134
Artery, structure of, 135, 136
Aster stage of division, 20
Attraction spheres, 18
Auditory hair cells, 47, 49, 50
nerve, 49
nuclei of, 64, 66
Auerbach, plexus of, 118
Axilemma, 54
Axis cylinder, 53

Basilar membrane, 48
Basket cells of cerebellum, 74
Bile-ducts, 123
Bipolar cells of retina, 46
Bladder, urinary, 145
Blood corpuscles, 133
vessels, 135
Bone, 95, 97
decalcified, 97
development of, 95
Bonnet, nerve plexus of, 30
Bowman, capsule of, 141, 142, 144
glands of, 37
membrane of, 39
Bronchial muscle, 128
Bronchiole, 128
Bronchus, 128
Bruch, membrane of, 42
Brunner, glands of, 111

Canal of Schlemm, 42
Canaliculi of bone, 97
Canalis Cochleæ, 47, 48
Cancellous bone, 98
Capillary network, 130, 134
Capsule of cartilage cells, 93
Cardiac glands of stomach, 110, 111
Cartilage, 93
Cement substance of teeth, 101
Centrosome, 19, 20
Cerebellum, cortex of, 73
Cerebrum, cortex of, 75, 78
results of Golgi's method, 78
Chlorophyll, 14
Chorio-capillaris, 42
Choroid, 42
Chromatin, 19
Chromosomes, 20
Cilia, 17
Ciliary muscle, 42
processes, 42
Ciliated epithelium, 17
of larynx, 127
of respiratory region, 37
of uterus, 152
Circumvallate papillæ, 38, 105, 106, 107
Claudius, cells of, 47
Cochlea, 47
Cohnheim, fields of, 88
Collaterals of Ramon-y-Cajal, 54, 75
Colloid substance, 130
Colon, 119
Columnar epithelium, 17, 116
Cone fibres, 44
Cones of retina, 44
Coni vasculosi, 153
Connective-tissues, 91
Convoluted tubules of kidney, 141
Corium, 23
Cornea, 39
Corneal corpuscles, 39, 91
Corneo-sclerotic junction, 42, 91
Corpora cavernosa, 156
quadrigemina, 71
Corpuscles, red, 133
white, 133
Corpus Highmorianum, 153
luteum, 150
spongiosum, 156
Corti, organ of, 47
Crista acustica, 49
Crura cerebri, 71
Crusta, 72
petrosa, 101
Cuticula, 17

Débove, membrane of, 17, 128
Decalcified bone, 97
Decussation of pyramids, 61
at birth, 65
supra-pyramidal, 61
Deiters, cells of, 47
Dendrites, 18, 54, 76
Dendron, 75
Dentine, 101
Dermis, 23
Descemet, membrane of, 39
Development of tooth, 101
Diaster stage of division, 20
Discus proligerus, 152
Dispirem stage of division, 20
Duodenum, 111, 112

Ebner, v., glands of, 38, 105
Elastic tissue, 91, 93
cartilage, 92
Eleidin, 33
Embryo, 14
Enamel, 101
organ, 102, 103
prisms, 101, 104
pulp, 103
Endomysium, 86
Endoneurium, 79
Endothelium, 18
Engelmann, accessory disc of, 88
Epidermis, 33

Epididymis, 153, 154
Epiglottis, 127
Epimysium, 86
Epineurium, 79
Epithelium:
ciliated, 17, 37, 127, 152
columnar, 116
squamous, 17, 24
stratified, 23, 33, 127
transitional, 145
Epitrichial layer, 23, 28
Equatorial stage of division, 20
Erectile tissue, 156
Eyelid, 31

Facial nerve, nucleus of, 69
Fallopian tube, 152
fimbriæ of, 152
Fasciculus solitarius, 63
Fat, absorption of, 116, 123
in liver cells, 122
Fenestrated membrane of Henle, 135
Fibre cells of Retzius, 49
Fibro-cartilage, 93
Fifth nerve, ascending root of, 58, 60, 61
Filiform papillæ, 107
Fillet, 60, 64, 69, 71, 72
Formatio reticularis, 58, 60, 61
alba, 64, 68
grisea, 64
Fossa rhomboidea, 59, 63
Fourth nerve, nucleus of, 71
Fovea centralis, 43
Fundus of stomach, 110
Fungiform papillæ, 107
Funiculus cuneatus, 58, 61, 62
gracilis, 58, 61, 62
teres, 63
nucleus of, 63
Fusiform nerve-cells, 75

Galactoferous ducts, 31
Ganglion, inferior cervical, 79
spinal, 79
spiral, 50
Ganglionic layer of retina, 46
Gennari, striæ of, 75
Germinal epithelium, 150
spot, 17, 152
vesicle, 13, 17, 19, 152
Gianuzzi, crescents of, 113
Glands, gastric, 110, 111
mammary, 31, 32
Meibomian, 31
of Littré, 156
salivary, 13
sebaceous, 31
sweat, 23, 33
Glisson, capsule of, 121
Glomerulus, 141, 144
Glossopharyngeal nerve, nucleus of, 63

Goblet cells, secretion and discharge of, 124
of stomach, 110
of small intestine, 116
Golgi's method, 78
Graafian follicle, 152
Granule layer of cerebellum, 73
Gustatory pore, 38
cells, 38

Hair, 25
cells, auditory, 47, 49, 50
cuticle, 26
follicle, 25
knob, 25
papilla, 25
root, 25
Hannover, stratum intermedium of, 103
Hassall, concentric corpuscles of, 138
Haversian canals, 97
Heart muscle, 87
Henle, fenestrated membrane of, 135
layer of, 25
loop of, 141
sheath of, 53
Hensen, line of, 88
supporting cells of, 47
Horizontal cells of retina, 46
Horny layer of skin, 23
Huxley, layer of, 26
Hyaline cartilage, 93
Hypoglossal nerve, nucleus of, 58, 63

Ileum, 115
Infundibulum, 128, 130
Intercalary part of duct, 113
Interfibrillar substance of muscle, 88
Interglobular spaces, 101
Intermediate line, 88
Intervertebral disc, 93
Intima of artery, 135
Iris, 42
Irruption, stage of, 95

Jelly-like connective-tissue, 91
Jelly of Wharton, 91

Karyokinesis, 19, 20
Kidney, 141, 144
Krause, membrane of, 88

Lacunæ of bone, 97
of cartilage, 93
Lamellæ of bone, 97
Lamina cribrosa, 43
fusca, 40, 42, 43
spiralis ossea, 47
suprachoroidea, 42

Lantermann, incisures of, 54, 68, 80
Large intestine, 119, 120
Larynx, 127
Lemniscus, 69
medialis, 71
lateralis, 71
Lens, 39
fibres, 39
epithelium, 39
Leucocytes, 133, 138
Lieberkühn, follicles of, 112, 116, 119
Ligamentum circulare, 101
nuchæ, 91
pectinatum iridis, 42
spirale, 48
ventriculare, 127
vocale, 127
Lip, 34
Littré, glands of, 156
Liver, 121, 122, 123
Lung, 128, 130
Lunula, 28
Lymphatics, 138
of intestine, 118

Macula lutea, 43
Malpighi, corpuscles of, 138
rete, 23
Mammary gland, 31, 32
Marrow of bone, 95
Matrix of connective-tissue, 91
of nail, 27
Medulla oblongata, 58, 59, 61, 63
at birth, 65
Medullary segments, 54
sheath, 53
spaces, 95
Medullated nerve fibres, 54, 68, 79, 80
Meibomian glands, 31
Meissner, plexus of, 118
Membrana granulosa, 152
reticularis, 48
tectoria, 47
Membrane of Reissner, 47
Meristem, 15
Merkel, end-disc of, 88
tactile cells of, 30
Mesentery, 115
Metakinesis, 20
Microsomes, 20
Milk tooth, 104
Modiolus, 47
Molecular layer of cerebellum, 73
of cerebrum, 75, 78
Montgomery, glands of, 32
Morgagni, ventricle of, 127
Mucous glands of larynx, 127
of lip, 34
of œsophagus, 108
salivary, 113
of tongue, 105

Müller, fibres of, 44, 46
Muscle, 86
corpuscles, 87
fasciculi of, 86
heart, 87
non-striated, 87
striated, 86
vascular supply of, 86
Muscularis mucosæ of colon, 119
of stomach, 110
of uterus, 152
Myelin, 53
Myelospongium, 82

Nail, 27, 28
bed, 27
groove, 27
matrix, 27
root of, 27
Nerve-cells, 18, 53, 55, 59, 79
granules in, 55, 59
fibres, 53, 68, 79, 80
Nervi nervorum, 79
Neurilemma, 53, 79
Neuroblasts, 55
Neuroglia, 59, 78, 82
arrangement of, 82
development of, 82
Neuron, 75
Nodes of Ranvier, 53, 80
Non-medullated fibres, 54
Non-striated muscle, 87
Nucleus, 19
ambiguus, 64
cuneatus, 60, 61
gracilis, 60, 61
lateralis, 61

Odontoblasts, 102, 103
Œsophagus, 108
Olfactory bulb, 37
cells, 37
mucous membrane, 37
nerve fibres, 37
Olivary nucleus, 60, 61, 63
Olive, accessory, 60, 63
peduncle of, 63, 68
superior, 69, 70
Omentum, 115
Oosphere, 14
Optic nerve, 43
Ora serrata, 40, 43
Osteoblasts, 95
Osteoclasts, 95, 96
Osteogenetic fibres, 95
Otoliths, 49
Ovarian tubes of Waldeyer, 150
Ovary, 150, 152
Ovule, 14
Ovum, 13, 16, 150, 152
Oxyntic cells, 111

Pacinian bodies, 23, 28
Pampiniform plexus, 150
Pancreas, 114
Panniculus adiposus, 23
Papillæ of tongue, 105, 107
Papillary part of skin, 27
Parareticular cells of retina, 46
Parietal cells of cardiac glands, 111
Parotid glands, 113
Parovarium, 150
Pars ciliaris retinæ, 42, 43
Penis, 156
Peptic cells, 111
Perimysium, 86
Perineurium, 79
Periosteum, 95
Peritoneum, 120
Pes of crus cerebri, 72
Peyer's patches, 118
Pia mater, 73
Pigment cells of choroid, 39
of lamina fusca, 40
Pigment epithelium of retina, 17, 46
crystals of, 18
in liver cells, 121
Pleura, 130
Polar corpuscles, 20
Polymorphous cells, 75, 78
Pons Varolii, 64, 69, 71
transverse fibres of, 70
pyramidal bundles of, 71
Portal canal, 121
Posterior longitudinal bundle, 64, 71
perforated space, 71
Prickle cells, 33
Prostate, 156
Prostatic calculi, 156
Pseudopodia, 13
Purkinjé, cells of, 55, 73
Pyramidal cells of cortex cerebri, 75, 76, 78
Pyramids, 60, 61, 63

Ranvier, nodes of, 53
Raphe of medulla, 68
Recklinghausen's, v., spaces, 39
Red corpuscles, 133
nucleus, 72
Reissner, membrane of, 47
Restiform body, 60, 64, 69
at birth, 66
Rete Malpighi, 23, 27
mucosum, 23
testis, 153
Retina, 43, 44, 46
Retzius, fibre cells of, 49
Rod elements, 44
fibres, 44
Rods and cones, 44
Rods of Corti, 48
Root-sheaths of hair, 25

Saccule, 49
Salivary glands, 113
Sarcolemma, 87
Sarcoplasm, 88
Sarcostyle, 87
Sarcous element, 83
Scala tympani, 47
vestibuli, 47
Scalp, 31
Schlemm, canal of, 42
Schwann, sheath of, 53
Sclerotic, 40, 42, 91
Sebaceous glands, 31
Segmentation of ovum, 14, 15
Semicircular canals, 49
Sensory decussation, 58, 61
end organs of skin, 30
of smell and taste, 37
Serous salivary glands, 113
Sharpey, fibres of, 94, 95
Siliqua olivæ, 63
Sinus lacteus, 31, 32
Sixth nerve, nucleus of, 69
Skin, 23
Small intestine, 116, 118
Spermatoblasts, 153
Spermatogenic cells, 153
Spermatozoa, 154
Sphincter pupillæ, 42
Spinal cord, 58
at birth, 65
Spinal ganglion, 79
Spiral ganglion, 50
Spirem stage of division, 20
Spleen, 138
Spongioblasts, 82
Spongioplasm, 17
Squamous epithelium, 17, 24
Stratum corneum, 23, 33
granulosum, 23, 33
intermedium of Hannover, 103
lucidum, 23, 33
Stratified epithelium of œsophagus, 108
of skin, 23
of vocal cord, 127
Stroma of ovary, 150
Sublingual gland, 113
Submaxillary gland, 113, 114
Substantia gelatinosa centralis, 59, 62
of Rolando, 60, 61
nigra, 72
Suprapyramidal decussation, 58, 61
Suspensor, 14
Sustentacular cells of olfactory region, 37, 38
of taste buds, 38
Sylvius, aqueduct of, 71, 72
Sympathetic nervous system, 79

Tactile cells of Merkel, 30

Tactile corpuscles, 30
Taste buds, 38, 107
Tegmentum, 71
Tela choroidea, 72
Tendon, 86
    cells, 86
Testis, 153
Thymus, 138
Thyroid cartilage, 127
    gland, 130
Tongue, 105, 107
Tooth, 101
    development of, 101, 102, 103
    papilla, 103
    sac, 102
Trabeculæ of bone, 95, 98
Trachea, 127, 128
Trachealis muscle, 128
Transitional epithelium, 145
Trapezium, 69
T-shaped junction, 55, 79
Tunica albuginea testis, 153
Tunnel of Corti, 47
Turbinated bones, 37
Tympanum, 49

Ureter, 146
Urethra, 146, 156
    bladder, 145
Urinary tubules, 141, 142
Uterus, 152
    glands of, 152
Utricle, 49
Uvea, 42

Vagus, nucleus of, 63
Valvulæ conniventes, 118
Vas deferens, 153
Vasa efferentia, 153
    recta, 141
    vasorum, 135
Veins, 135
Vena Vorticosa, 42
Ventricle, fourth, 63
Ventricula laryngis, 127
Vermiform appendix, 119, 120
Vicq d'Azyr, striæ of, 75
Villi, 112, 116, 118
Vocal cord, 127

Waldeyer, ovarian tubes of, 150
Wharton, jelly of, 91
White corpuscles, 133
    sheath of nerve fibres, 53

Yellow elastic cartilage, 91
Yolk, 17, 152

Zona pellucida, 17, 152
    radiata, 152
Zonule of Zinn, 42

THE END.

Baillière, Tindall and Cox, King William Street, Strand

LANE MEDICAL LIBRARY

To avoid fine, this book should be returned on or before the date last stamped below.

SEP 13 1960

NOV 19 1965

LANE MEDICAL LIBRARY
STANFORD UNIVERSITY
300 PASTEUR DRIVE
PALO ALTO, CALIF.

E551 Brass, Arnold
B823 Atlas of human histolo-
1897 gy 3505

NAME	DATE DUE
Wm. Sheerlett	JUL -3 23
[illegible]	[illegible]
Mary Savage A346	SEP 13 1960
Jim Metzger	NOV 19 1965